



13283/B/1

1/1/10/1

148





ON

CANCEROUS AND CANCROID

GROWTHS.

WILLIAM BURNS & CO. LTD.

PRINTED

ON

CANCEROUS AND CANCROID  
GROWTHS.

BY

JOHN HUGHES BENNETT, M.D., F.R.S.E.,

FELLOW OF THE ROYAL COLLEGE OF PHYSICIANS;

PROFESSOR OF THE INSTITUTES OF MEDICINE, AND ONE OF THE PROFESSORS OF CLINICAL  
MEDICINE, IN THE UNIVERSITY OF EDINBURGH.

WITH ONE HUNDRED AND NINETY ILLUSTRATIONS COPIED FROM  
NATURE AND DRAWN ON WOOD BY THE AUTHOR.

EDINBURGH:  
SUTHERLAND AND KNOX, GEORGE STREET.  
LONDON: SIMPKIN, MARSHALL & CO.,  
AND SAMUEL HIGHLEY.

---

MDCCCXLIX.

305154





## PREFACE.

---

THE causes, diagnosis, nature, and treatment of Cancer, are points on which the most distinguished and experienced men in the profession are at variance. No one can doubt that this disease is frequently confounded with epithelial, fibrous, cystic, and other forms of morbid growth, and that up to the present time practical men have no ideas sufficiently fixed and positive to govern their conduct in many important and dangerous cases. It has appeared to the Author that the only mode of lessening the uncertainty which prevails on this subject, is careful investigation into the Clinical facts of each case, conjoined with an accurate and minute examination of the morbid growth. The results of inquiries carried on in this way, during a period of seven years, are now laid before the profession; and although the work falls far short of what is required to complete our knowledge of Cancer, the writer is at least conscious of having honestly attempted to elucidate one of the most difficult subjects in Pathology and Practical Medicine.

Twenty-two, out of the fifty-six observations recorded in the text, have been published in the MONTHLY JOURNAL OF

MEDICAL SCIENCE, and it was originally the Author's intention to have inserted the whole in the pages of that periodical. Believing, however, that three years would have elapsed before his design could have been accomplished in this manner, he has thought it better to lay the whole inquiry as it stands, at once before the profession.

The Treatise is divided into two parts. The first is carefully restricted to a record of facts, embracing a history of the case, a description of the morbid parts, and an account of the minute structure presented by these under the microscope. As the author is convinced that, in the existing state of our knowledge, no mere verbal description of ultimate tissues is sufficient to communicate correct impressions of them to others, exact copies of the structures described have, in every case, been represented. The drawings made from the objects at the time, he has carefully copied on wood, in which they have been cut by Mr Dudley. Although on this account they may not possess that finish and beauty which the hand of a professional artist would have given them, he feels satisfied that they will be considered by every histologist faithful representations of the structures described. Hitherto, surgeons in this country have possessed no work which will serve as a guide to the structural differences in Cancerous and Cancroid growths. The numerous figures contained in this volume may, perhaps, be useful to them in that capacity, and assist their own individual observations.

In the second part, the Author has given a systematic account of Cancers, partly founded on his own observations and partly on those of other writers, but more especially of

J. Müller, Gluge, Walshe, Lebert, Vogel, Sédillot, Rokitski, Engel, Gunsburgh, Bruch, and Virchow, to whose works nearly all that is known on the true Structure and Pathology of Cancer may be said to be confined. He trusts that wherever his own opinions are found to differ from those of such distinguished authorities, they will appear to be sufficiently warranted by the facts and arguments adduced in their support.

The Author thinks it right to state here, what he has endeavoured to inculcate in the body of the work, that the microscope *alone*—that is, independently of all other kind of observation—can seldom determine in the living subject the presence or absence of Cancer. At the same time, he feels himself bound emphatically to declare, that he thinks it capable of being as serviceable to the surgeon in cases of morbid growth, as the stethoscope is to the physician in cases of diseased heart or lungs. Neither instrument is infallible ; both require to be studied in an especial manner ; both demand long practical experience, and judicious reasoning power ; and both require to be conjoined with all the aids to be derived from other modes of observation. With the stethoscope, it is not that the crepitating rale in pneumonia, or the mucous rale in bronchitis, differ from similar rales which accompany tubercular disease, but that these signs, *conjoined with other symptoms*, clearly establish the diagnosis. So, likewise, it is not the recognition, by means of the microscope, of certain cells and fibres, which will enable us to assert with certainty the existence of Cancer ; but that their detection in particular places, and accompanying peculiar forms of growth, permits

us to do so. In proportion as our knowledge of morbid anatomy advances, instrumental assistance becomes the more valuable for the purposes of diagnosis; and it is now manifest that, to this end, a microscope is as necessary to assist our sense of sight, as is a stethoscope to assist our sense of hearing, or a probe to assist our sense of touch.

In conclusion, the writer begs to return his sincere thanks to the numerous gentlemen who have furthered his inquiry, by allowing him to examine morbid specimens, and to publish their cases. Aware of the persevering efforts now making, by many individuals, to base the Practice of Medicine upon a more rational and a less empirical foundation, it will afford him the highest satisfaction to learn, that the following pages are considered by them as a useful contribution to their labours.

# CONTENTS.

## PART I.

	PAGE
ON CANCEROUS AND CANCROID GROWTHS . . . . .	1
OBSERVATION I.—Cancerous Tumour of the Breast—Excision—Cure .	
... II.—Tumour apparently Fibrous, but really Cancerous, of the Neck—Excision—Cure . . . . .	5
... III.—Cancroid Tumour of the Breast (Cystic Sarcoma)— Excision—Cure . . . . .	6
... IV.—Cancerous Tumour of the Breast—Excision—Cure .	9
... V.—Cancer of the Breast—Excision—Cure . . . . .	10
... VI.—Cancer of the Breast—Excised—Return of the Disease—Re-excision—Re-appearance of the Morbid Growth . . . . .	11
... VII.—Cancroid Tumour of the Breast—Excision—Cure .	12
... VIII.—Cancer of the Cheek—Excision—Cure . . . . .	14
... IX.—Fungoid Tumour of the Bladder—Hæmaturia— Death . . . . .	16
... X.—Cancer of the Testicle—Excision—Cure . . . . .	18
... XI.—Cancer of the Testicle—Excision . . . . .	20
... XII.—Cancer of the Uterus; Ovaries; Lumbar, Mesenteric, and Epigastric Glands; Liver; Stomach and Colon— Peritonitis—Death . . . . .	22
... XIII.—Cancer of the Uterus—Fatty Liver—Bright's Disease—Death . . . . .	24

	PAGE
OBSERVATION XIV.—Cancer of the Uterus—Peritonitis—Death . . .	26
... XV.—Cancer of the Uterus and Lumbar Glands—Death . . .	29
... XVI.—Cancer of the Liver, Stomach, Spleen, and Lumbar Glands—Pneumonia—Death . . . . .	31
... XVII.—Cancer of Liver, Pancreas, and neighbouring Lym- phatic Glands—Death . . . . .	34
... XVIII.—Cancer of Liver, Pylorus, Lesser and Greater Omentum and Lumbar Glands—Fever and Dysentery —Death . . . . .	36
... XIX.—Cancerous Ulcer of Stomach—Stricture of Pylorus —Cicatrices in the Liver—Calcareous Concretions in Mesenteric Glands . . . . .	39
... XX.—Cancer of the Lung, Bronchial Glands, and Pericar- dium—Death . . . . .	43
... XXI.—Cancroid of Stomach, and Cancer of Mesenteric and Lumbar Glands—Death . . . . .	46
... XXII.—Cancroid of Stomach—Stricture of Pylorus—Con- traction and Thickening of Omentum—Chronic Peri- tonitis—Death . . . . .	48
... XXIII.—Cancroid and Chronic Ulcer of Stomach—Con- traction and Thickening of Omentum—Ascites— Death . . . . .	50
... XXIV.—Cancroid of Stomach—Bronchitis—Cretaceous Concretions in the Lungs—Death . . . . .	52
... XXV.—Cancer of Stomach, Intestines, and Lymphatic Glands—Double Pleurisy—Peritonitis—Death . . . . .	54
... XXVI.—Cancerous Ulcer of Stomach—Cancer of Epigastric and Mesenteric Glands—Cancer of Pleura, Diaphragm, Peritoneum, Liver, and Uterus—Peritonitis—Death . . . . .	57
... XXVII.—Cancer of the Stomach, Duodenum, Liver, Pan- creas, and Lumbar Glands—Death . . . . .	59
... XXVIII.—Cancer of Duodenum—Jaundice—Pericarditis— Cretaceous Concretions in the Lungs—Death . . . . .	63
... XXIX.—Cancer of the Rectum and of the Prostate—Per- foration of Intestine—Peritonitis—Death . . . . .	64
... XXX.—Cancerous Masses of Diaphragm—Cancerous Tu- mour in Abdomen—Aneurism of Aorta—Disease of Aortic Valves—Cicatrices with Cretaceous Masses in Apices of both Lungs—Ascites—Death . . . . .	66

	PAGE
OBSERVATION XXXI.—Cancer of Omentum and Peritoneum, loaded with Calcareous Deposit—Ascites—Death . . . . .	69
... XXXII.—Cancroid Tumour attached to the Tentorium pressing upon the Cerebellum—Inflammatory Softening of Cerebellum—Chronic Tubercular Cavern in Left Lung, with Vegetations—Death . . . . .	72
... XXXIII.—Cancroid Tumour attached to the Tentorium— Inflammatory Softening of the Right Corpus Striatum and Optic Thalamus—Death . . . . .	74
... XXXIV.—Cancroid Tumour below the Integuments of Thigh—Excision—Return in Six Years—Re-exci- sion . . . . .	78
... XXXV.—Cancerous Tumour of Mouth—Excision—Return —Re-excision . . . . .	80
... XXXVI.—Cancroid Tumour of the Mamma—Excision— Cure . . . . .	82
... XXXVII.—Cancroid Tumour of the Parotid Gland—Hemi- plegia of the Face—Death . . . . .	83
... XXXVIII.—Cancroid Tumour of the Neck—Excision—Re- turn in Two Years—Re-excision after Twenty-one Years—Cure . . . . .	87
... XXXIX.—Cancroid Tumour of the Neck (Enchondroma) —Excision—Cure . . . . .	89
... XL.—Melanic Cancer of the Cheek—Excision—Cure . . . . .	91
... XLI.—Cancroid of Lip—Excision—Cure . . . . .	93
... XLII.—Cancroid of the Lip—Excision—Cure . . . . .	95
... XLIII.—Cancroid Tumour of the Leg—Amputation—Re- covery . . . . .	96
... XLIV.—Cancerous Tumours on the Finger and Toe—Am- putation—Recovery . . . . .	98
... XLV.—Cancer of Sternum, Ribs, and Left Mamma— Chronic Ulcer of Stomach—Cretaceous Concretions in Mesenteric Glands—Cystitis—Death . . . . .	100
... XLVI.—Osteo-medullary Sarcoma of the Os Femoris—Am- putation of the Hip-joint—Return of the Disease in the Orbit and Stump—Death . . . . .	103
... XLVII.—Cancroid Tumour (Medullary Sarcoma) of Hu- merus—Amputation at the Shoulder-joint—Death . . . . .	105

	PAGE
OBSERVATION XLVIII.—Cancroid Tumour (Enchondroma) of the Humerus —Amputation at the Shoulder-joint—Cure . . . . .	108
... XLIX.—Cancroid Tumour (Enchondroma) of the Ischium and Pubis—Vegetations on the Margin of the Aortic Valves—Death . . . . .	110
... L.—Colloid Cancer of Omentum, and the Peritoneum lining the various Abdominal Viscera—Compound Encysted Colloid Tumours of Ovaries—Peritonitis—Death . . . . .	112
... LI.—Colloid Cancer of Peritoneum, Stomach, and Ovaries— Pleuro-pneumonia—Death . . . . .	117
... LII.—Colloid Cancer of the Mamma—Excision—Cure . . . . .	120
... LIII.—Colloid Cancer of the Mamma—Excision—Cure . . . . .	122
... LIV.—Encysted Sanguineous Colloid Tumour of the Back —Excision—Cure . . . . .	124
... LV.—Cancroid Ulcer of the Scrotum and Penis—(Chimney- sweep's Cancer)—Excision—Cure . . . . .	126
... LVI.—Cancroid Ulcer of the Tongue—Excision . . . . .	129

## PART II.

INTRODUCTION, WITH DEFINITIONS . . . . .	135
CHAPTER I.—Histology of Cancerous and Cancroid Growths . . . . .	139
... II.—Chemistry . . . . .	162
... III.—General Anatomy . . . . .	169
... IV.—General Pathology . . . . .	201
... V.—Statistics . . . . .	218
... VI.—Diagnosis . . . . .	221
... VII.—Prognosis . . . . .	231
... VIII.—Rational Treatment . . . . .	236
APPENDIX . . . . .	253



ON

# CANCEROUS AND CANCROID GROWTHS.

---

## PART I.

I PROPOSE, in the first part of this inquiry, to record illustrative cases of cancerous and cancroïd growths, in all of which the minute structure of the diseased part has been carefully described and figured.<sup>1</sup> These will be accompanied by short commentaries, which serve to point out the particular facts of interest contained in each observation.

<sup>1</sup> *Method of examining morbid growths.*—The following is the method which, for some years, I have employed in the examination of morbid growths, and which I recommend to the young pathologist. The specimen should always be recent; the addition of alcohol causing coagulation of the albuminous compounds, and altering the form of the corpuscular elements.

In the first place, the external physical characters of the growth should be accurately examined, and as much learned of the history of the case as possible. A section should then be made, and the appearances of the cut surfaces carefully examined. These should be squeezed, to see if they yield any fluid; if not, the surface should be gently scraped. A drop of the fluid or pulpy substance so obtained, should now be placed between glasses, and examined with an achromatic microscope under a power of 250 linear diameters. After the natural appearances of the more fluid parts have been observed, water should be first added, then acetic acid, and the effects of each re-agent studied. Water generally causes the cell formations to enlarge by endosmosis, and enables the manipulator to separate coherent masses, and examine each corpuscle, perfectly isolated. It is only in this way that the numerous molecules and granules floating in the blastema can be separated from those within the cell, which now may be seen revolving in the fluid with its contents. Acetic acid has the remarkable property of dissolving and rendering very transparent many of the albuminous compounds. The walls of most recent cell formations are, in this way, rendered transparent, or caused to disappear; and the nucleus, which was formerly obscure, is rendered clear and well defined. The action of acetic acid on cell struc-

## OBSERVATION I.

## CANCEROUS TUMOUR OF THE BREAST—EXCISION—CURE.

SUSAN BAILLIE, æt. thirty-seven, dressmaker, admitted February 22, 1847, into the Royal Infirmary, under Mr Syme. At the latter end of December she observed a swelling of the left mamma, attended with sharp shooting pain, which was thought to be an abscess, and treated by fomentations, &c. Under this treatment it decreased in size, leaving in its place a small tumour the size of a horse-bean, in which she felt a sharp, gnawing pain. It has increased rapidly, paroxysms of pain coming on at intervals, attended by swelling of the arm and axillary glands of the same side. On admission, a circumscribed tumour in the left breast, about the size of a small orange, can be distinctly felt, separable from the true substance of the gland. *February 24.*—To-day Mr Syme removed the tumour by a single incision. She was dismissed with the wound completely healed, and to all appearance in good health, *March 13.*

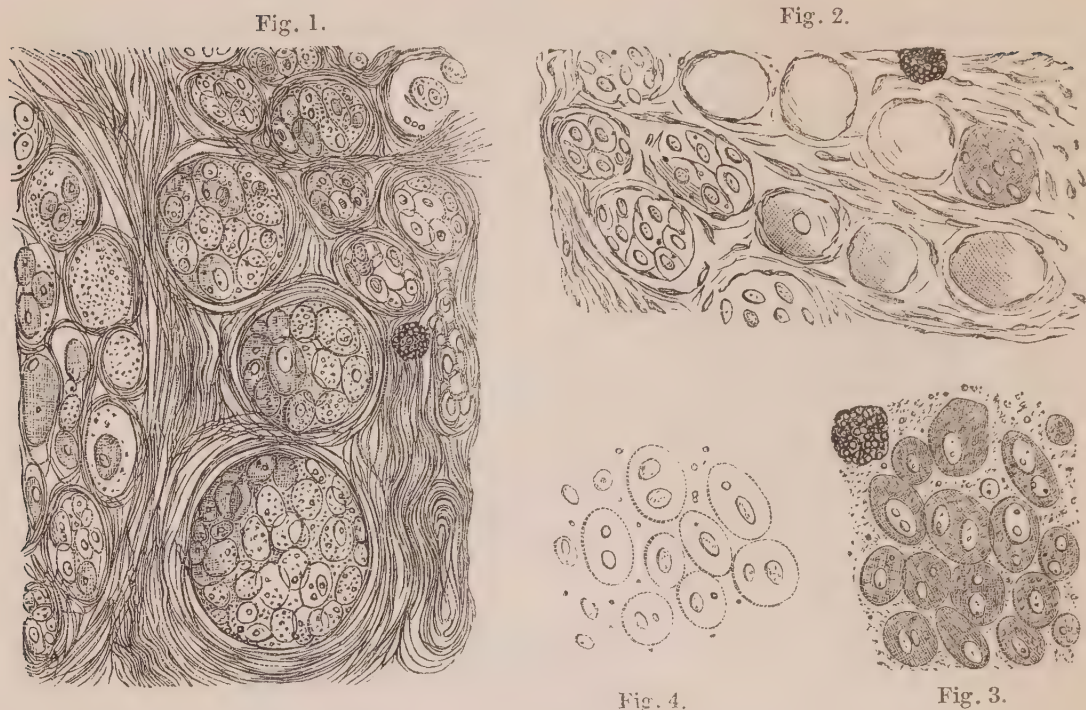
tures is of the utmost importance in a diagnostic point of view, and the having omitted to describe its effects has vitiated the account of many otherwise good observations. I would recommend the young pathologist to repeat these demonstrations several times before terminating this part of the inquiry, and further to study the effects of ether and of liquor potassæ, diluted with an equal part of water. In every case, whenever the cut surface of the tumour presents differences in structure, colour, or consistence, the same manipulations and observations must be repeated on the fluid or pulpy substance from each altered portion.

Having now examined the fluid parts of the growth, the solid parts must be investigated. For this purpose a thin slice should be removed, placed between glasses, inspected under the microscope, and in like manner successively treated with water and acetic acid. A thin slice may be obtained with a sharp knife, or a pair of curved scissors; but by far the best means is the double-bladed knife of Valentin. This instrument, indeed, may be considered almost indispensable to the histologist, especially where large sections are required, and where it is of importance not to derange the relation of the elementary structures to each other. A transparent section thus obtained, enables the observer to see the fibrous stroma of the growth, the arrangement of the ultimate filaments, the relation to these of the cells, granules, molecules, or mineral particles, he has previously examined; the arrangement of the blood-vessels, &c. &c. Several sections should always be made, and attentively inspected, from various parts of the tumour; of course, taking care to include in these every variety of appearance and structure it may present.

The observation is now complete. To keep a record of it, however, it is necessary that a note be immediately taken of the appearances observed, with and without re-agents, and that the different structures be accurately drawn. This requires some little skill in drawing, and especially in copying from the field of the microscope. I cannot, however, too strongly recommend the early and constant practice of drawing what is seen, not only because mere words often utterly fail in giving a correct idea of the object described, but because such practice necessitates a much more careful examination of the object itself.

*Examination of the Tumour.*—On examining the tumour I found it, as stated in the report, to be about the size of a small orange or billiard-ball, imbedded in the fatty tissue of the mamma, a layer of which surrounded it laterally and posteriorly. It was intimately connected with the substance of the gland laterally and posteriorly, into which it sent here and there short prolongations—anteriorly, it was adherent to the skin. It was of firm consistence, but somewhat softened at one spot. On section it grated under the knife, and presented a smooth, whitish, fibrous structure, except anteriorly at the softened part, which was about the size of a hazel-nut, of a pinkish hue, with a small infiltration of blood in its centre, of a bright crimson colour. The circumference of the tumour generally was hard, firm, and resistant to the knife (scirrhus). This hardness diminished anteriorly towards the softened part, which presented all the characters of encephaloma, and yielded on pressure a fluid the colour and consistence of thick cream. The elliptical portion of skin removed with the tumour was healthy.

*Microscopic Examination.*—A thin section was removed from the centre of the tumour by means of Valentin's knife, and examined with a power of 250 diameters linear. It consisted of a mesh-work of fibrous tissue, forming waved bands, arranged here and there in circles, varying in size. Some of these were very large (one-fifth of a millimetre in diameter), enclosing other circles, each of which were surrounded by several filaments of the fibrous tissue. Some of these circles contained numerous nucleated corpuscles crowded together, mixed with granules; others contained only a few, or nothing but granules. Here and there were to be seen several compound granular corpuscles. The appearance of this section is very accurately represented—(Fig. 1). On adding acetic acid to the whole structure, it became more transparent. Many of the fibrous filaments became invisible, and such as remained were studded here and there with elongated nuclei. The walls of the corpuscles were partially dissolved, and rendered very transparent; whilst their nuclei were unaffected. A portion of the section, as seen after the addition of acetic acid, is represented—(Fig. 2). The cream-like fluid, which could be squeezed from the surface of the tumour, contained, 1st, nucleated cells; 2dly, compound granular corpuscles; 3dly, numerous granules. The nucleated cells were of a round or oval form, varying in size from the 1-100th to the 1-50th, or even 1-40th of a millimetre in diameter. Some contained one nucleus, others two, of an oval form, varying in the longest diameter from 1-100th to 1-75th of a millimetre. Some of these nuclei contained one nucleolus, and others two. On the addition of acetic acid the cell-wall was rendered more transparent; the nuclei were unaffected, and appeared in consequence very distinct. The appearance of these cells, with and without acetic acid, is exhibited in the two lower figures of the woodcut. The compound granular corpuscles and granules do not require minute description here.



*Fig. 1.* Portion of the section from tumour, described Obs. I., consisting of fibrous tissue and cysts, enclosing cancer cells and granules. A compound granular corpuscle is also visible. *Fig. 2.* Another portion of the same section treated with acetic acid. The fibrous tissue is rendered more transparent, and elongated nuclei are visible scattered throughout it. The nuclei of the cancer cells are unchanged, while their walls are very transparent. A compound granular corpuscle is seen at the upper part of the figure. *Fig. 3.* Cancer cells from the cream-like juice squeezed from the tumour. Numerous granules and a compound granular cell are seen. *Fig. 4.* The same after the addition of acetic acid.

*Remarks.*—This case was a very characteristic one of the so-called scirrhus of the breast. I therefore have selected it as a standard of comparison, presuming that if any growth deserves the name of cancerous or malignant, it will not be denied to this one. I spent three entire days in its microscopic examination, and making numerous drawings, selections from which have been cut on wood. Sections with Valentin's knife were made of it in all directions, and the fluid it contained examined at all points. In short, I spared no possible pains to make out every anatomical fact in connexion with the tumour. The result of the examination was, that it was composed of a fibrous matrix, arranged so as to form numerous minute cysts, within which, as well as between the meshes formed by the fibrous tissue, numerous nucleated cells had developed themselves. Many of these cells were characterised by the presence of a double or divided nucleus, within which might be observed a double or divided nucleolus. These structures I shall in future denominate *cancer cells*. On the addition of acetic acid, the cell-wall was partially dissolved and rendered very transparent, whilst the nucleus was unaffected. The fibrous tissue at

the same time exhibited numerous elongated nuclei, which were seen in the waved filaments as well as those which formed the concentric circles constituting the walls of each cyst.

I may further notice that no distinct line of demarcation could be discovered between the morbid growth and the healthy tissue of the mamma, the fibrous tissue of the one being continuous with that of the other, and the adipose tissue of the gland encroaching here and there upon, and portions of it being occasionally imbedded in, the substance of the tumour.

Several other tumours, of a like appearance to the naked eye, which I have examined, presented the same structural arrangement. In a growth about the size of a pigeon's egg, excised from the breast by Mr Spence (June 10, 1847), which he kindly allowed me to examine, its section was so exactly similar under the microscope, that the same drawings might serve for both specimens.

## OBSERVATION II.

### TUMOUR APPARENTLY FIBROUS, BUT REALLY CANCEROUS, OF THE NECK— EXCISION—CURE.

*May 8th, 1847.*—I received for examination the half of a tumour, which was of several years growth, and had been excised from the region of the parotid gland. It was of a globular form, about three inches in diameter, with a small mamellated projection at one point. It had been carefully dissected out from the neck, its surface being smooth, and distinctly defined. On section it was resistant, and crunched under the knife. It presented a tolerably even dull-white surface, uniform throughout, of tolerably hard consistence, and was pronounced, after the most careful inspection, to be fibrous. At the same time it did not present any distinct fibrous appearance; and, on being broken up, it was observed to break across abruptly. One of the clerks in the Infirmary (Dr Gairdner), who examined it, likened its general appearance and texture, with considerable truth, to that observed in a hard pudding made of ground rice. No cream-like fluid could be obtained from it on pressure, although a pulpy substance could be obtained from its surface easily, on scraping with a knife.

*Microscopic Examination.*—On making a thin section with Valentin's knife, it was seen that this tumour, like that described Obs. I., was composed of fibrous tissue, arranged here and there in concentric circles or cysts, differing in size, but generally measuring from the 1-50th to 1-20th of a millimetre in diameter—(Fig. 5). The fibrous filaments in many places were exceedingly fine, and mingled with numerous fusiform corpuscles. Within the cysts nucleated corpuscles were contained, the walls of which were rendered very transparent by acetic acid, while the nuclei were unaffected—(Fig. 6). The

fibrous tissue did not present the same wavy character, nor did it seem to be so well developed as in Obs. I. On examining the pulpy substance removed by scraping the surface of the tumour, it was seen to contain numerous nucleated corpuscles, with some fusiform cells—(Fig. 7). They were mostly of round or oval form, but some were distinctly caudate, heart-shaped, or somewhat square. Several contained two nuclei, each with one nucleolus, others a single nucleus with two nucleoli.

Fig. 5.

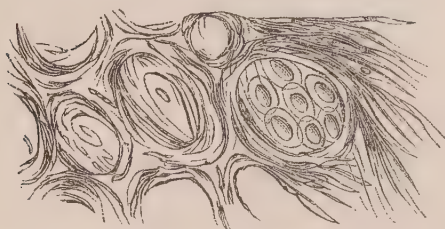


Fig. 6.

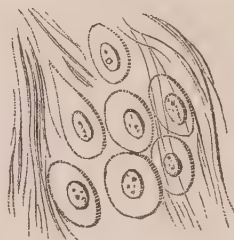
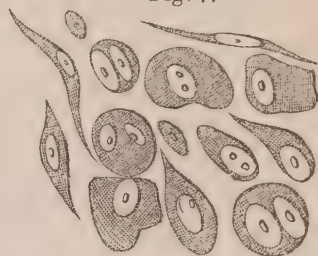


Fig. 7.



*Fig. 5. Portion of a section from tumour, described Obs. II., consisting of very fine fibrous tissue mixed with fusiform cells, and cysts inclosing cancer cells. Fig. 6. Another portion of the same after the addition of acetic acid. Fig. 7. Cancer and fusiform cells scraped from the surface of the tumour.*

*Remarks.*—It is necessary to remark, that whilst the corpuscular element and the minute structure of this tumour were almost identical with that observed in Obs. I., its appearance to the naked eye was very different. It was considered by all who examined it to be simply fibrous; it was so considered before and after removal by the surgeon who operated; the morbid growth was distinctly limited and defined, and admitted of being carefully dissected out. Yet its minute structure, as shown by the microscope, was seen to consist of the same elements, similarly arranged as in the former tumour, which presented to the naked eye very opposite characters, and was at once recognised by every one who saw it to be malignant. I consider this to be a very important fact, and one which will go far to explain many of the anomalies and contradictions which have prevailed among practical men concerning this subject.

### OBSERVATION III.

#### CANCROID TUMOUR OF THE BREAST (CYSTIC SARCOMA)—EXCISION—CURE.

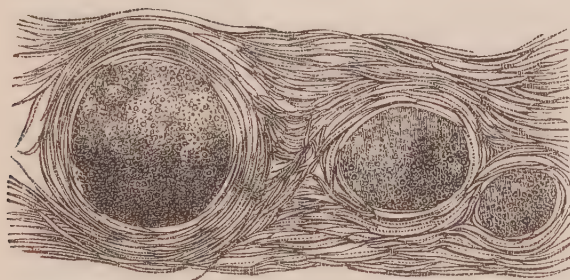
A married woman, *æt.* thirty-six, without children, had observed a tumour in the right mamma eighteen months ago, the size of a hazel-nut. When she applied to Dr R. Mackenzie, she stated that it had regularly progressed in size, and was now as large as an adult human hand. At one point the skin is slightly ulcerated from pressure, and bleeding had taken place from this point more than once. She complained of pain only from its weight and size, and had none of the lancinating severe pains so common in cancerous tumours. It was smooth

on its surface, round, and moveable. A cyst was punctured in it, and a quantity of glairy fluid removed. The mamma was excised in the beginning of May 1847, by Dr Mackenzie, by a double elliptical incision. The wound healed readily, and the cicatrix is now (September) sound.

*Description of the Tumour.*—The tumour consisted of a dense mass, of globular form, weighing 7lbs. The portion of skin on its anterior surface was healthy, with exception of the ulcer from pressure formerly noticed; and a layer of adipose tissue was attached to it here and there, posteriorly and laterally. On section it presented a smooth surface, of a yellowish fawn colour, of a faintly fibrous texture, with here and there distinct cysts, varying in size from a pea to that of a pigeon's egg. These cysts were lined with a smooth serous membrane, and filled with a glairy, glutinous, transparent fluid, of a pale straw colour. The tumour presented the characters of so-called cystic-sarcoma, and a glairy transparent fluid could be squeezed from it, or removed from its surface by scraping with the knife.

*Microscopic Examination.*—Numerous sections were made of this tumour in different directions with Valentin's knife. It was found to be composed of a fibrous texture, the filaments of which were interlaced together in some places, forming waved bands of filamentous tissue, occupying the entire field of the microscope. In other places cysts were formed, as in the two former Observations, the walls of which were composed of fibrous filaments and fusiform corpuscles, as in Obs. II. The contents of those cysts varied considerably. Some were occupied by a coagulated exudation, composed of minute molecules and granules, as in Fig. 8. Others contained numerous corpuscles of round

Fig. 8.

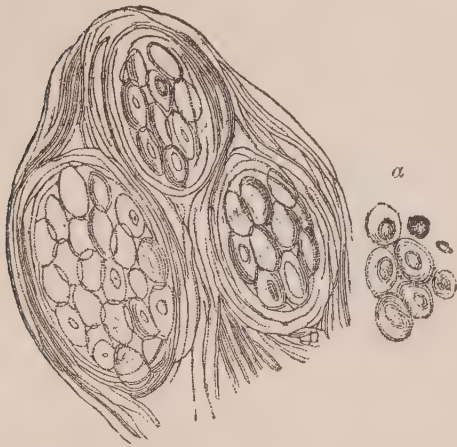


*Fibro-cystic structure in a portion of the tumour, described Obs. III. The cysts containing granular exudation.*

or oval form, varying in size from the 1-100th to the 1-50th of a millimetre in their longest diameter, generally of the latter size. They each contained a single oval nucleus, generally 1-100th of a millimetre in diameter. These cells occurred in groups, underwent a slight change in form from contiguous pressure, and were only slightly affected by acetic acid.—(See Fig. 9). Occasionally the fibrous tissue was arranged so as to form groups of loculi, generally about the 1-25th of a millimetre in diameter, containing a structureless, gelatinous fluid, as in Fig. 10. Acetic acid every where rendered the fibrous tissue more

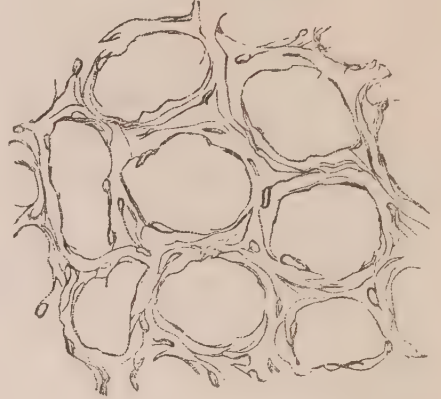
transparent, and rendered the elongated nuclei very apparent—(Fig. 10). The glairy, gelatinous fluid was for the most part structureless, but sometimes contained some of the cells above described, or fusiform corpuscles.

Fig. 9.



*Fibro-cystic structure, in another portion of tumour, described Obs. III. The cyst contained fibro-plastic cells; (a) a few of the latter after the addition of acetic acid.*

Fig. 10.



*Fibrous structure with loculi, in another portion of tumour, described Obs. III., after the addition of acetic acid.*

*Remarks.*—The fibrous element in this tumour exactly resembled that which existed in Observations I. and II., and was arranged in the same manner. The corpuscular element, however, was very different. In no case did the cells contain a double nucleus or nucleoli. They in every respect corresponded to those denominated *Fibro-plastic* by Lebert, and closely resembled some forms of epithelium.<sup>1</sup> Their general size was much smaller than that of cancer cells, and they were not accompanied by numerous granular, or compound granular corpuscles. The action of acetic acid upon them was also very different. The division of the nucleus being nowhere perceptible, we may presume that these cells do not possess the power of reproduction. Hence a marked difference between them and those described in the two former Observations. The coagulated granular exudation, occupying some of the cysts, is an occurrence which I have only met with in this tumour.

A fibro-cystic tumour removed from the breast of a lady, June 17, 1847, by Mr Syme, composed of numerous minute cysts, containing a gelatinous yellow fluid, and imbedded in fibrous tissue, presented the same structure represented Figs. 9 and 10.

<sup>1</sup> *Physiologie Pathologique.* Vol. ii. p. 123.



## OBSERVATION IV.

## CANCEROUS TUMOUR OF THE BREAST—EXCISION—CURE.

A woman aged about thirty-five, unmarried, laboured under a tumour, the size of a small orange, which she first noticed five months previously. It was irregular on the surface, and the skin was of a red colour. She had occasionally experienced lancinating pain in it, shooting towards the axilla. Her general health was good. The breast was excised, August 16th, by Mr Syme. The wound healed readily, and, towards the end of September, the cicatrix was sound.

*Description of the Tumour.*—The tumour was the size of a small orange, of globular form, closely adherent to the skin anteriorly, and posteriorly imbedded in the substance of the mamma. It was tolerably circumscribed except at one point, where it sent a prolongation nearly an inch long laterally into the gland. On section it generally presented a dirty grayish colour, reticulated all over with an orange yellow matter, and here and there presenting small irregular patches of crimson colour. In consistence it was soft throughout, in one place pulpy, and every where yielded a copious milky fluid on pressure.

*Microscopic Examination.*—The fibrous structure of the tumour was exceedingly loose, generally running in parallel lines straight or waved, and not forming cysts. In the meshes between these fibres numerous cancer cells were present. These were generally of an oval form, though some were round, and varied in size from the 1-50th to the 1-20th of a millimetre in diameter. Some contained a nucleus with two nucleoli; others, a double nucleus. Mixed with the cells were numerous granules, and several naked nuclei, characterised by their oval form and great delicacy. The orange-coloured creamy matter in the reticular form was composed of numerous compound granular corpuscles and masses—(See Fig. 11). On the addition of acetic acid, the cancer cells exhibited the appearance formerly described—(Fig. 12).

Fig. 11.

Fig. 12.

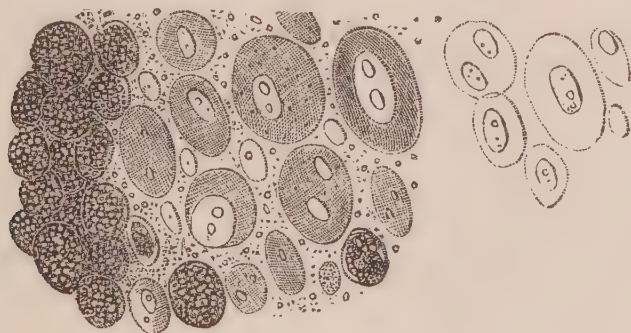


Fig. 11. Cancer cells and compound granular corpuscles in the tumour, described Obs. IV.—  
Fig. 12. The former acted on by acetic acid.

*Remarks.*—This tumour presented all the characters of Muller's *Carcinoma reticulare*, and was considered by all who saw it to be a

very malignant growth. Some of the corpuscles were large and well developed, whilst others existed in every stage of formation, from the simple oval nucleus to the large cell with double nucleoli. The large quantity of fatty matter in the form of compound granular corpuscles, constituted a considerable part of this tumour, and presented all the appearances and structure of fawn-coloured softening of the brain. It will be seen in subsequent Observations that the structure of the reticulum varies considerably.

## OBSERVATION V.

## CANCER OF THE BREAST—EXCISION—CURE.

I received by post, April 13, 1847, a slice of a tumour removed by Mr Fergusson of London from a female breast the previous day. The woman was aged sixty-three, and had, says Mr F., "so malignant a tumour that I could scarcely be induced to operate. Nevertheless, up to the present time (October) there has been no return of the disease." The section presented a white glistening structure, here and there of pulpy consistence, with small patches of a yellow substance, soft as cream, deposited in it. It yielded, on pressure, a tolerably copious milky juice.

*Microscopic Examination.*—The fibrous structure of the tumour was more dense than in the last case, composed of fibres running in parallel lines in bundles, between which the corpuscles had been developed. These were of the same character as in Observation IV.; only a few of them presented a caudate form, and some presented several prolongations—(Fig. 13). Acetic acid caused the cell wall to become more transparent, and the nucleus very apparent—(Fig. 14). The fibrous structure was also rendered more transparent, and oval or elongated nuclei could be seen scattered through it—(Fig. 15). The yellow creamy substance was composed of numerous granules and molecules, which entirely disappeared on the addition of ether—(See Fig. 16).

Fig. 13.

Fig. 14.

Fig. 15.

Fig. 16.

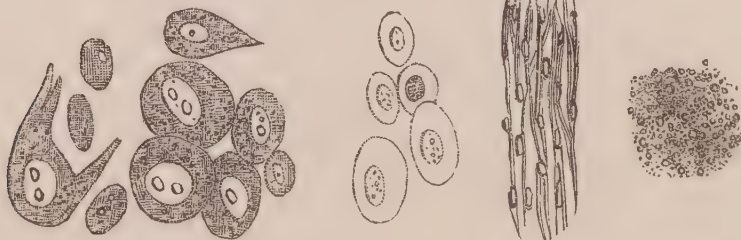


Fig. 13. Cancer cells in portion of tumour, described Obs. V. Fig. 14. The same acted on by acetic acid. Fig. 15. The fibrous structure acted on by acetic acid. Fig. 16. Structure of the yellow creamy substance.

*Remarks.*—In this tumour, we observe that several of the cancer

cells were elongated at one end, so as to present a caudate appearance. This form of cell is now recognised by histologists not to be characteristic of cancer, although there can be no doubt that many such cells were originally oval, and subsequently more or less elongated by pressure. We have here an instance, also, of cells throwing out various prolongations, and assuming a very irregular form. Yet the existence of a nucleus with double nucleoli, as seen in the figure, prove to us that they possess the same mode of development, and are identical with the round or oval cancer cells. In this, as in the last Observation, the quantity of fat accumulated is worthy of notice, existing in the granular rather than in the corpuscular form.

## OBSERVATION VI.

CANCER OF THE BREAST—EXCISED—RETURN OF THE DISEASE—RE-EXCISION—  
RE-APPEARANCE OF THE MORBID GROWTH.

The patient, a remarkably fat and otherwise healthy woman, æt. fifty, from the country, had had the mamma excised for cancer two years previous to her consulting Dr Douglas Maclagan. He found that the cicatrix was again affected with the disease; and, as she insisted on its being again removed, it, as well as the whole of the mamma, was cut out, May 6, 1846. The wound, in the course of healing, took on unhealthy action, and sloughed. It had, therefore, to heal by granulation; but, before this was completed, she was sent by Dr Maclagan into the country for change of air. She returned in June 1847, with the disease again established in the cicatrix. Neither on this, nor at any previous time, had the axillary glands been affected, and her general health has always been excellent. Dr Maclagan now refused to excise the tumour for the third time. She returned to the country, and has not since been heard of.

*Description of the Tumour.*—The part excised consisted of the entire mamma, which was very voluminous, loaded with fat, and weighed upwards of two pounds. Anteriorly, there was a deep cicatrix, surrounded by puckering, about two inches long, in the centre of which was a nodule of firm carcinomatous matter, about the size of a walnut. It was slightly elevated above the surface, and was firmly adherent to the skin. On section, it was seen to be of white colour, with smooth surface, a little softened at one point, and sent several prolongations posteriorly and laterally into the substance of the gland. Scraping with the knife, and very strong pressure, produced from its surface a thick, white, pultaceous fluid.

*Microscopic Examination.*—The cancerous juice squeezed from the softened portions of the diseased mass, contained some round and oval cancer cells ex-

actly similar to those described in previous Observations. A considerable number of them, however, had undergone marked changes in their form, being elongated, caudate, spindle-shaped, or approaching a square shape—(Fig. 17). One of these, of a caudate form, represented at the top of the figure, measured 1-12th of a millimetre in length. The nuclei were generally of an oval form, and contained a double nucleolus. In the cell just now indicated, the nucleus measured about 1-50th of a millimetre in its longest diameter. It contained at one extremity two nucleoli situated transversely to its long axis, and, at the other extremity, a large vesicular nucleolus 1-125th of a millimetre in diameter, enclosing one granule. On adding acetic acid, the same change was observed as in the previous Observations—(Fig. 18). A section of the morbid growth with Valentin's knife, exhibited its stroma to consist of a fibrous mesh-work, in which the cells, mingled with numerous granules and free globules of oil, were imbedded. Considerable collections of compound granular corpuscles could also be observed here and there.

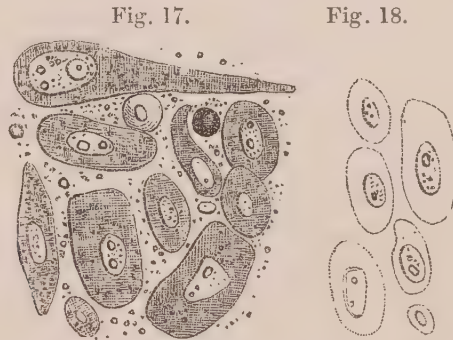


Fig. 17. Cancer cells in growth, described Obs. VI. Fig. 18. The same acted on by acetic acid.

*Remarks.*—In this case a cancerous growth had been excised twice, and although on the latter occasion the entire mamma was removed, it again returned. The cancer cells were large and well developed, and exhibited in a characteristic manner one of the modes in which the nucleoli are developed within the nucleus. The alteration in the form of the cells, is here, as in Observation V., deserving of notice.

## OBSERVATION VII.

### CANCROID TUMOUR OF THE BREAST—EXCISION—CURE.

On the 20th of May 1847, I received from Mr Page of Carlisle a slice of a tumour removed by him from a female's breast. The following is the note he was so good as to give me of the case :—“ The woman is forty-two, married, no children, always enjoyed good health. An uncle had cancer of the face, which was removed many years before his death, and there was no return of the disease. About four months before admission she was suddenly attacked with pain in the right breast, of an acute throbbing character, at times very

severe ; at first confined to one spot, where there was a hard swelling ; subsequently there were three prominent parts, all hard, and in the neighbourhood of the nipple ; and in all, the same pain. The breast rapidly increased in size, but the pain was principally seated in the prominent parts. On admission the whole breast was greatly increased in size, heavy, the skin very vascular and tense, and in some parts slightly prominent portions, in which there was an indistinct sense of fluctuation. The breast perfectly smooth on the subjacent parts ; considerable superficial tenderness, rendering an examination difficult. No retraction of the nipple, and no enlargement of the neighbouring glands. The tumour weighed  $4\frac{3}{4}$  pounds, and was composed of two distinct structures, dispersed irregularly throughout the whole mass ; a portion of each of which you received. Her recovery has been uninterrupted."

*Description of the portion of Tumour received.*—The portion of tumour I received was about three inches long, an inch broad, and two lines in depth. At one end it consisted of an amber-coloured, tolerably firm gelatinous mass, resembling slightly opaque gelatine, in which, here and there, faint striæ were observable. Towards the centre of the slice several white lines were seen, here and there mixed up with the jelly-like substance. These lines became more and more numerous, and crowded together towards the other end of the section, which offered the appearance of a perfectly opaque white mass, resembling in its general aspect and consistence firm *blanc mange*, and presented a marked fibrous structure when torn. No milky juice could any where be squeezed from the surface.

*Microscopic Examination.*—The amber-coloured gelatinous portion was composed principally of a structureless blastema, containing here and there fibres of extreme delicacy, which, with careful management of the light, might be observed to assume the form of fusiform corpuscles. In the midst of the jelly-like blastema, at different depths, were a number of compound granular masses. Some of these, when brought into focus, presented a number of granules, varying in size from the 1-500th to the 1-200th of a millimetre in diameter, which highly refracted light, and were aggregated together, without being enclosed within a cell wall. When out of focus, these masses presented a brownish dark shadow, as represented Fig. 19. Where the amber-coloured jelly was passing into the white substance, the fusiform cells became more numerous, and were mingled with a number of oval nucleated cells of great delicacy, varying in size, and especially in length ; some being caudate, others spindle-shaped, as towards the right side of Fig. 20. As the white substance became firmer, these elements were more compressed together, as is seen towards the left of the same figure. A thin section of the densest part of the white portion presented a fibrous structure, wholly composed of fusiform cells, which, on the addition of acetic acid, became more transparent, whilst the nuclei were rendered very distinct—(Fig. 21).

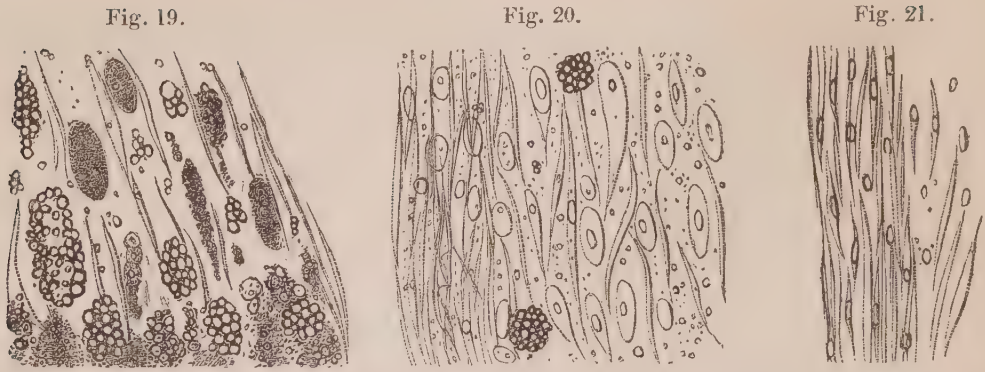


Fig. 19. Structure of jelly-like matter in tumour, described Obs. VII. Fig. 20. Structure of the white substance in the same case. Fig. 21. The same acted on by acetic acid.

*Remarks.*—This interesting specimen of morbid growth exhibited an unequivocal example of a jelly-like or simple blastema, in which fibrous tissue was forming. The development could be watched throughout all its different stages. In the jelly-like matter were a number of fat granules, the number of which gradually disappeared as the structure became more fibrous. The oval corpuscles might be seen, in a very early stage, resembling some of these isolated granules, and gradually becoming larger and larger, caudate, spindle-shaped, and at length fusiform. There was no appearance here of a cancer cell, and we must regard this tumour as one in progress of development. According to the report it was of four months' standing; and yet, in that short period, exudation had been thrown out to the amount of  $4\frac{3}{4}$  pounds weight. The time had apparently been occupied more in the process of exudation than in that of development.

### OBSERVATION VIII.

#### CANCER OF THE CHEEK—EXCISION—CURE.

JANE JOHNSTONE, æt. forty-six, admitted May 5th into the Royal Infirmary, under Dr Duncan, with carcinoma of the upper lip and left cheek. About six years ago, it began as a small wart at the angle between the left ala of the nose and the cheek, and has been gradually on the increase ever since. Within the last six months it has grown much more rapidly than it did in the earlier part of its course. It now involves two-thirds of the superior labium, the left ala of the nose, and the skin of the cheek, as far as the malar prominence. The patient suffers little pain from it; her countenance is sallow, and of a harsh, unhealthy appearance. She says that she has, from time to time, experienced lancinating pain in the part, but this is somewhat doubtful. *May 7th.*—To-day the whole of the diseased parts were removed. The wound healed rapidly, and she was discharged cured, May 25th.

*Description of the Morbid Growth.*—The part removed had been soaking twenty-four hours in water before I saw it, whereby the whole had been perfectly blanched, and the epidermic surface considerably softened. The skin was considerably thickened and indurated, and growing from its surface were several nodules of firm consistence, and varying in size from a pea to an almond-nut. On cutting into one of these, the incised surfaces presented a dead white, and partly fibrous structure, but yielded on pressure a thick, glutinous, milky fluid.

*Microscopic Examination.*—Several sections were made of these tumours with Valentin's knife, one of which is represented—(Fig. 22). At *a* is the external edge of the section passing through the softened epidermis, the cells of which are enlarged, apparently swollen by steeping in water. They occurred isolated and in groups. A few were round, but they were generally of a somewhat square shape, varying in their longest diameter from 1-50th to 1-30th of a millimetre. Their nucleus was delicate, yet well marked, of round form, measuring about the 1-100th of a millimetre across, with a single nucleolus attached to the wall of the nucleus, about the 1-300th of a millimetre in diameter. Those which occurred in groups were greatly altered in shape, and formed a continuous surface by being agglutinated at their edges (*b*). These epidermic scales were mingled with a great number of fusiform corpuscles, of a flattened form, distinctly nucleated, presenting a narrow edge when turned sideways, and confusedly lying together or crossing one another. The tissue of the dermis was considerably hypertrophied, consisting of curled filaments of elastic tissue, with a fibrous mesh-work, in which numerous loculi or round openings were observed, as at *c*. Some of these were completely filled with cancer cells, and others were seen infiltrated amongst the meshes of the fibrous structure at *d*. Here and there compound granular masses were visible occurring in the stroma. The milky juice squeezed from the cut surface contained numerous cells, resembling in every particular those described and figured Obs. I.—(See Figs. 3 and 4).

Fig. 22.

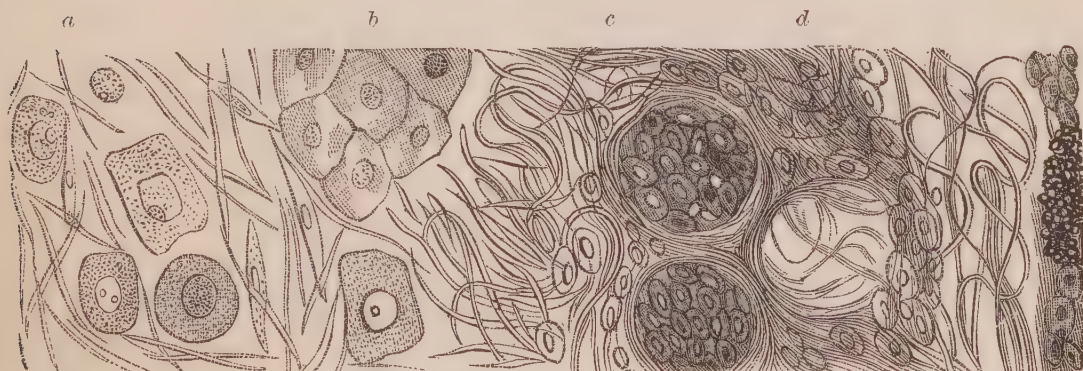


Fig. 22. Appearance of section of cancerous tumour, described Obs. VIII. *a*. Epidermic scales and fusiform corpuscles on the external surface. *b*. Group of epidermic scales. *c*. Fibro-elastic tissue of the dermis. *d*. Cancer cells infiltrated into the fibrous tissue, and filling up the loculi of dermis.

*Remarks.*—The epidermic scales in this case offered a striking

resemblance to some forms of cancer cell, represented Fig. 17. One of the nuclei also, it will be seen, has a double nucleolus. I shall afterwards point out how epidermic and epithelial cells, after being steeped in water or a thin serous fluid, may exactly resemble in every essential particular cancer cells. In the present instance, however, they existed rather in the form of flattened scales, which, by their aggregation, formed in some places a contiguous surface, as at *b*. The epidermic cells, also, were external to the fibrous structure; whereas the true cancer cells were situated within the meshes formed by it, or filled up the loculi in the dermis, where, in a healthy condition, the sebaceous follicles, hair bulbs, and blood-vessels are situated, as at *c*.

### OBSERVATION IX.

#### FUNGOID TUMOUR OF THE BLADDER—HÆMATURIA—DEATH.

On the 24th of April 1846, I visited the Glasgow Infirmary, and was present during the examination of an individual who had died there under the care of Dr W. Thomson. The following is an account of the case he was so good as to give me.

Charles M'Lachlan, æt. forty-two, was admitted into the Royal Infirmary of Glasgow on the 2d of January 1846, under the care of Dr W. Thomson. His urine had been occasionally bloody for many years; and, for five years previous to his admission, had been passed with pain and difficulty. For three or four weeks his symptoms had been much aggravated. Calls to micturition were very frequent, occurring at intervals of a quarter of an hour at longest, and the passage of the urine was attended by much pain along the urethra. He felt much debilitated from the quantity of blood which he had recently lost, although at the time of his admission his urine was not bloody. There was severe and pretty constant pain above the pubes, but none, for a long time previously, in the loins. The urethra and prostate were natural, and nothing abnormal could be detected in the bladder by the sound. He had phimosis, which he attributed to a gonorrhœal attack twenty years previously. His urine was light coloured, neutral, of sp. gr. 1014. It contained mucus and albumen, and the addition of nitric acid rendered it deep pink. The aspect of patient's countenance was cachectic. His body was emaciated, his skin harsh and dry, and his disposition peevish and irritable. Pulse 90; feeble. Ankles œdematous. Digestive functions pretty natural.

From his admission to the 1st of March his treatment consisted chiefly in the administration of opiates, generally in the form of enemata; and of pills with and without the acetate of lead; of leeches to the perinæum; of the infusion of buchu with the tr. ferri muriat.; and of a stimulant embrocation to the loins. Under the use of these measures he seemed, for some time, to



improve. His urine became more free from mucus, and was seldom bloody, and he could retain it for an hour. The pain above the pubes, however, as well as the scalding after micturition, continued severe. There was no pain or weight in the loins.

Towards the end of February, the sound was again introduced for the purpose of examining the bladder. It detected nothing abnormal in that viscus or in the urethra. The operation, however, was accompanied by pain about the prostatic portion of the urethra, and followed by decided increase in the quantity of blood discharged.

During the greater part of March he improved in the power of retaining his urine, calls to micturition being often at two hours interval from each other. In every other respect, however, he was decidedly worse. His urine became constantly bloody, and the pain in the hypogastric region more and more severe. The loss of blood was attended by extreme debility and emaciation, pallor of the integuments and of the mucous lining of the mouth, anxiety and depression of countenance, and mental despondency. His appetite failed, and his stomach became exceedingly irritable, so that, for some time, all his food was rejected by vomiting, at longer or shorter intervals after being swallowed. He had opiate enemata to relieve the hypogastric pain; effervescing powders to allay the irritability of the stomach; wine to support his strength; and sulphuric acid, pil. plumb. opiat., and latterly, extract of hæmatoxylin, in order to check, if possible, the discharge of blood.

Towards the latter end of March, his symptoms underwent some amendment. The flow of blood ceased; the stomachic irritability became diminished; there was abatement of the pains; and his temper became more cheerful and hopeful. His pulse, however, continued very feeble, and there was little accession of strength. His improvement was of short duration. On the 20th of April he was evidently sinking. Next two days he was incoherent, and he died on the 23d.

*Sectio cadaveris, April 24th.*—The kidneys were found slightly granular. The bladder contained three rounded masses of fungoid disease; two of them, about the size of hazel-nuts, were attached near the orifice of the urethra by very narrow pedicles and thin slips of mucous membrane; the third, which was as large as a hen's egg, had been so loosely connected, that its attachment had been separated, apparently in the act of dissecting out the bladder. These tumours were of soft pulpy consistence throughout, and of a whitish grey colour, closely resembling grey cerebral matter (encephaloma).

*Microscopic Examination.*—A portion of the larger soft medullary tumour contained the structures represented Fig. 23, composed of, 1st, numerous molecules and granules; 2d, oval and round corpuscles, some of which contained two distinct granules; 3d, oval nucleated bodies; 4th, caudate and spindle-shaped cells; and 5th, fusiform corpuscles with one extremity more or less divided. On the addition of acetic acid, the cell walls in general were rendered more transparent, whilst the granules and nuclei remained distinct—(Fig. 24).

Fig. 23.



Fig. 24.

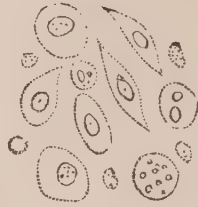

Fig. 23. Corpuscles in soft cancerous looking tumour of the bladder, described Obs. IX. Fig. 24. The same acted on by acetic acid.

*Remarks.*—Dr Thomson observes of this case:—“During this man’s life, the diagnosis was somewhat doubtful. It was pretty evident, from his general aspect, that he laboured under malignant disease. Where this was situated, however, was a matter of some uncertainty. The irritability of the patient’s stomach; the fact that nothing was detected in the bladder by the catheter; and the uniform diffusion of the blood amongst the urine, and the absence of coagula in it, seemed to indicate that the kidneys, or one of them, was the seat of the disease; while the absence of pain in the loins, the constant pain at the hypogastric region, and the aggravation of symptoms which seemed consequent on the last introduction of the sound, appeared to refer it to the bladder.” It is possible that a microscopic examination of the urine might have thrown some light upon the case, although it cannot be overlooked, that the corpuscles of the tumour (Fig. 23) very much resemble epithelial cells. The analogy between cancer and epithelial cells will be more fully described in the second part of the work. This is the only cancerous-looking tumour I have met with on the mucous coat of the bladder, and I have, therefore, considered it worthy of being recorded.

#### OBSERVATION X.

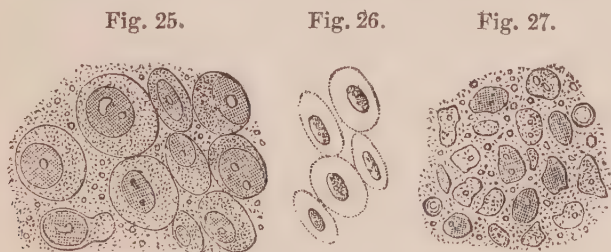
##### CANCER OF THE TESTICLE—EXCISION—CURE.

JAMES ANDERSON, a quarryman, æt. forty, was admitted into the Royal Infirmary, Sept. 17, 1842, under the care of Mr Syme, with a large hard swelling of the right testicle. He states, that about two years and a half ago he received a blow on it from a large crowbar, immediately after which the organ became swollen, and felt very painful, especially at two points. In both of these points an abscess formed, was opened and healed. The tumour, however,

continued to increase in size, although for a twelvemonth he felt little or no uneasiness in it except what arose from its bulk, which, he says, at the end of that time was as large as a goose egg. At this period he felt a "stounding" pain in the part, passing in the direction of the inguinal canal. This continued for some time, although partially relieved by successive poulticing. The swelling has continued to increase up to the period of admission. On examination the left testicle was found to be of its natural size and consistence. In place of the right one there is a hard solid tumour, the size of a large cocoa-nut. The cord seems to be implicated as far as the external opening of the canal. The patient is of a strong constitution, although his countenance has a slightly cachectic aspect. *September 21st.*—Mr Syme to-day excised the tumour in the usual way, except that the whole body of the morbid growth was separated from its attachments before the cord was cut. This was done on account of the disease extending so far up towards the groin. Eleven vessels were tied, and the edges of the wound brought together by interrupted sutures. He was discharged cured, *November 8th.*

*Description of the Tumour.*—On making a section of the morbid growth, it was seen to be composed of two substances, one presenting all the characters of cerebriiform cancer, the other a bright yellowish granular matter imbedded in it in masses. The first was generally of an opalescent greyish colour, semi-transparent, and of gelatinous consistence, here and there passing into a dull white colour and firmer material. The upper third was more dense than the inferior portions, and of somewhat fibrous texture. This medullary matter was sprinkled here and there with small bloody extravasations, of a deep crimson colour, and yielded on pressure a copious milky fluid. Here and there, in the substance just described, were imbedded masses of a light yellow or saffron colour, varying in size from a hazel-nut to a walnut. They were of soft consistence, friable, and readily broke down under the fingers, very much resembling in general appearance and feel the substance of certain farinaceous puddings.

*Microscopic Examination.*—The white or medullary substance of the tumour was composed of bands of filaments of great fineness, partly composed of fusiform cells, which crossed each other in various directions. In the meshes so



*Fig. 25. Cancer cells in tumour of testis, described Obs. X. Fig. 26. The same acted on by acetic acid. Fig. 27. Corpuscles and granules in yellow masses of same tumour.*

formed, were numerous round and oval cancer cells of great delicacy, varying in size from the 1-50th to the 1-30th of a millimetre in diameter—(Fig. 25).

The nuclei were very distinct, in different stages of development, some containing one nucleolus, and others two. On the addition of acetic acid, the cell was rendered almost invisible, whilst the nucleus was somewhat contracted and rendered darker—(Fig. 26). The yellow substance was composed of numerous molecules, granules, and loose oil globules, mixed with corpuscles of irregular form. These approached the square or oval form, and in their longest diameter measured from the 1-100th to the 1-80th of a millimetre. In some one, and in others two highly refracting granules could be distinguished, similar to those seen in the nucleus of the cancer cell—(Fig. 27).

*Remarks.*—The white or medullary substance of this tumour was evidently composed of the same structure as has been shown to be present in other forms of cancerous growth; consisting of nucleated cells, with double nucleoli, developed in the meshes of fibrous tissue. The yellow substance very much resembled certain forms of tubercle, for which, indeed, it has often been mistaken by pathologists. Its minute structure also has a general resemblance to tubercle, although, on comparison, the corpuscles will be seen to be more like the nuclei of cancer cells. I have always considered, however, that their peculiar appearance was owing to the degeneration or breaking down of the cancer cells first formed, constituting one of the modes in which these cells become abortive. It is the reticulum of Müller, and the xanthose of Lebert. We have here also an example of a cancerous growth arising from local injury.

## OBSERVATION XI.

### CANCER OF THE TESTICLE—EXCISION.

WILLIAM STEVEN, æt. thirty-eight, a mason, admitted into the Royal Infirmary September 11, 1847, under Mr Syme. He had a large tumour of the right testicle, which commenced two years previously. For the first two months he experienced stinging pains in it, but subsequently he felt no inconvenience except from the weight, or when pressed upon. It gradually increased in size, and is now of oval form, and measures eight inches in longest diameter. It is firm and solid to the feel; the skin covering it perfectly healthy. *September 24.*—The tumour was excised in the usual manner. A considerable number of arteries were tied at the time, and five more about two hours afterwards, the bleeding having continued. He has done well, but is not yet discharged—(*October 16.*)

*Description of the Tumour.*—The tumour was of an oval form, measuring in its longest diameter eight inches, and weighed 2 lbs. 14 oz. On stripping off the tunica vaginalis, its external surface was seen to be slightly lobulated. On section, the cut surfaces generally presented a pale fawn or flesh colour, mottled here and

there by crimson extravasations of blood. In two places there was a collection of pale yellow matter, passing gradually into the surrounding substance. One of these measured three inches across in its longest diameter; the other an inch and a half. The consistence of the tumour differed at various places. Towards the circumference, and in the under portion, it was generally firm and fleshy, and presented an evident fibrous arrangement; at one or two spots, however, softening had occurred, over an extent the size of a sixpence, of a greyish colour, and almost diffuent. At the upper portion of the tumour the diffuent softening was much more extensive, occupying about one-fourth of its surface, which, mingled with a considerable quantity of blood extravasated, appeared of a dirty violet colour. The slightest pressure produced copious streams of a milky, reddish or purplish, turbid fluid, from different parts of the surface. The pale yellow matter was of cheesy consistence, somewhat friable, or easily broken down between the fingers, and more dry than the surrounding structures.

*Microscopic Examination.*—The fluid contained in the softened portions, as well as that squeezed from any part of it, was crowded with cancer cells, compound granular corpuscles, blood globules, and numerous granules. The cancer cells existed in every stage of development; from naked nuclei, containing two nucleoli, to the perfect cell, containing two or even three nuclei. Some were round, others oval, and a few caudate. In size they varied from 1-60th to 1-35th of a millimetre in diameter—(Fig. 28). On the addition of acetic acid, the cell walls became more transparent, whilst the nuclei became somewhat contracted, more opaque, and very distinct—(Fig. 29). A section with Valentin's knife, showed that those cells were enclosed within the meshes of a fibrous stroma, the filaments of which ran in a wavy or straight direction, sometimes crossing each other, at others forming circular or oval curves. On the addition of acetic acid, they presented elongated nuclei, scattered at irregular distances—(Fig. 30). The

Fig. 28.

Fig. 29.

Fig. 30.

Fig. 31.

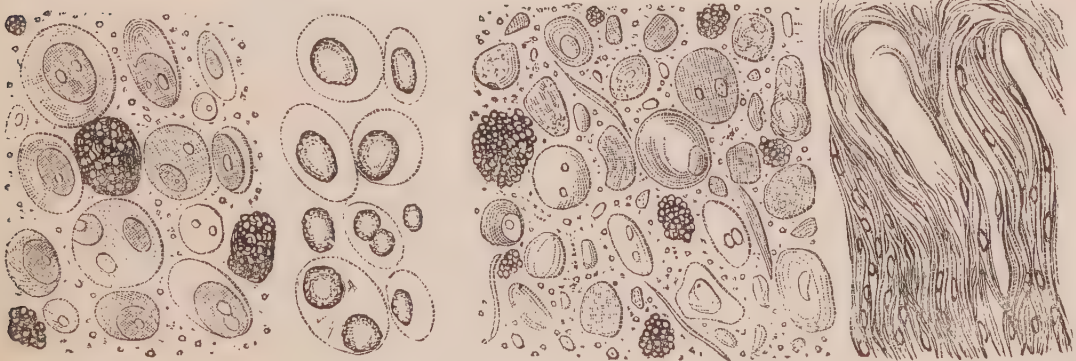


Fig. 28. Cancer cells and granular corpuscles in tumour, described Obs. XI. Fig. 29. The same acted on by acetic acid. Fig. 30. Cancer cells and granular corpuscles undergoing disintegration. Fig. 31. Fibrous matrix of the tumour acted on by acetic acid.

pale yellow cheesy matter was composed of numerous cancer cells, the majority of which, however, had lost their roundness of outline; several appeared indented

and shrunk together. In some, nuclei and nucleoli could still be seen; in others no trace of nucleus could be observed, but only a greater or less number of granules, either confined apparently to the centre of the cell, or diffused throughout its contents. Many irregular shaped bodies, approaching the round or oval, not 1-100th of a millimetre in diameter, could also be observed, resembling tubercle corpuscles, as in the last observation. The compound granular corpuscles were for the most part broken down, presenting no cell wall, but rather a congeries of granules of more or less irregular outline. Several fusiform cells and debris of fibrous texture, together with a multitude of granules and free oil globules, floated among the elements just described.

*Remarks.*—In this observation, the gradual breaking down and disintegration of the cancer cells, to form the yellow material, could be observed in almost every stage: some having lost their contour, others more or less collapsed; the nuclei converted into granules. Many cells were broken down, forming small irregular bodies, resembling tubercle corpuscles. The compound granular corpuscles, and fibrous tissue, were also broken down. This peculiar appearance, also, it must be remembered, was not accompanied with softening,—a fact the more necessary to dwell upon, because it has frequently been considered by pathologists to indicate a yellow softening of cancer. In point of fact, it was dryer than the more perfect cancerous structure surrounding it,—a proof that the fluid it formerly contained had been absorbed.

## OBSERVATION XII.

CANCER OF THE UTERUS; OVARIES; LUMBAR, MESENTERIC, AND EPIGASTRIC GLANDS; LIVER; STOMACH AND COLON—PERITONITIS—DEATH.

MARIAN CHRISTIE, æt. forty-nine, a widow of intemperate habits, was admitted Feb. 26, 1842, into the Royal Infirmary, under the care of Dr Spittal. Her illness was of three years' duration, and first appeared with constant pain in the epigastrium. During the last twelve months vomiting had supervened, generally coming on five or ten minutes after taking food. On admission, the symptoms were of a similar description. The vomiting was frequent. She had acute pain in the left hypocondrium, and wandering pains in the abdomen. There was great prostration of strength, and a sallow complexion. The catamenia had only appeared twice during the last five months. The pain in the abdomen subsequently became more severe, the presence of fluid also was apparent, and she died April 12.

*Sectio Cadaveris, April 6, 1842.*—Body greatly emaciated.  
*Thoracic organs* healthy.

*Abdomen.*—The abdominal cavity was greatly distended with fluid, which was of a brownish colour, containing flocculi of lymph. The peritoneum lining the abdominal parietes was coated with a brownish lymph, which in the iliac region was of a black colour and gangrenous odour. The intestines were loosely adherent by soft lymph, of the same unhealthy character as that just mentioned. From the rectum upwards, they were covered with projecting tumours, varying in size from a sixpence to half-a-crown, of whitish colour, slightly depressed in the centre, and more or less vascular. The mucous membrane was healthy, except in the centre of the transverse arch of the colon, where the projection inwards of one of these tumours had produced ulceration. In the sigmoid flexure of the colon, the tumours were not only larger but more continuous, and the intestinal walls were considerably thickened, and the gut constricted. At the pyloric portion of the duodenum, a large tumour projected from without inwards into the canal, and a few others of smaller size existed around. Several others formed a mass the size of a small orange, which pressed inferiorly and posteriorly inwards on the stomach, producing an hour-glass constriction of that organ. On opening it, the mucous membrane corresponding to the tumour was found deeply ulcerated, with raised edges, extending over a space the size of a five-shilling piece. The liver, at its posterior part, contained three or four white tumours about the size of walnuts, prominent on the surface and depressed in their centres. All the mesenteric and lumbar glands were enlarged and affected with the same disease, which, wherever present, presented on section a whitish colour, in some places very soft, yielding on pressure a copious milky fluid.

The whole fundus of the uterus was infiltrated with the same cancerous deposit, and presented on its surface several prominent tumours, varying in size from a hazel-nut to a walnut. The os uteri was enlarged, its margins rough and ulcerated, yielding on pressure a brownish, foetid fluid. Both ovaries were enlarged, and infiltrated with white cancerous matter throughout.

The other abdominal organs healthy.

*Microscopic Examination.*—On examining a drop of the fluid, squeezed from a section of the tumour in the fundus uteri, at a point where it was somewhat softened, it was found to contain the structures represented—(Fig. 32). Numerous corpuscles were observed, varying greatly in size and shape. Some completely round, about the 1-50th of a millimetre in diameter, containing a round nucleus, more or less granular, about the 1-130th of a millimetre in diameter. Some of these had evidently been rendered oval and elongated by pressure. Several also had attained a much larger size, and were of a caudate or spindle-shaped form, with one or more nuclei, some of which contained double nucleoli. A few had reached a great magnitude, their nuclei and nucleoli being proportionally augmented. One in the centre of the figure measured nearly 1-10th of a millimetre across. Another corpuscle is seen where the nucleus measured about the 1-33d of a millimetre in diameter, and contained a large nucleolus, with a centre granule the 1-200th of a millimetre in diameter. Mingled with the cells now described, were numerous granules, several naked nuclei, and some elongated fusiform corpuscles. In the harder portions of the same tumour, the cells varied in size from the 1-80th to the 1-30th of a millimetre in diameter.

The fluid squeezed from one of the tumours attached to the sigmoid flexure of the colon, contained cancer cells of the same general appearance as those in the uterus—(Fig. 33). There were few fusiform corpuscles, however, and a greater number of free nuclei.

Acetic acid produced the same reaction on these cells as has been so frequently described before. The cancerous deposit in the other organs, want of time prevented me from examining.

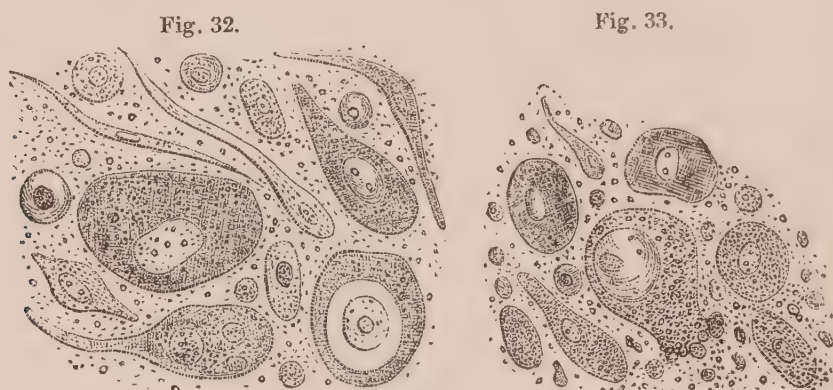

Fig. 32. Cancer cells and fusiform corpuscles from uterus, described Obs. XII. Fig. 33. Cancer cells from an enlarged lymphatic gland attached to the colon in the same case.

*Remarks.*—This was an example of very extensive cancerous formation. At the time it occurred, however (1842), not being so much interested in the subject as at present, I only kept notes and drawings of the appearances found in the uterus and glands. It will be observed, that the cancer cells in both had reached a much higher stage of development than any that have been yet noticed. In Fig. 32, we see how, in the same tumour, the cells grow in two different ways. In one increasing by multiplication of the nuclei, in another by one cell rising within another.

### OBSERVATION XIII.

#### CANCER OF THE UTERUS—FATTY LIVER—BRIGHT'S DISEASE—DEATH.

ANNE DUFF, aged thirty-seven, admitted into the Royal Infirmary June 19, 1844, under Dr Graham. Has had five children. About four months ago she first perceived a discharge of a yellow colour from the vagina, and has since had constant pain in the lower parts of the abdomen. She has also passed clots of blood at irregular intervals. On admission she complains of constant pain in the region of the uterus, and there is a very copious foetid discharge from the vagina. To the touch the cervix uteri feels smooth, tense, and hard, and the os uteri considerably dilated and irregular, sending down projections into the vagina. The examination causes great pain. The urine is scanty, is mixed with blood, and highly coagulable by heat and nitric acid.—



*September 23*, The symptoms, with more or less intromission, have continued up to the present time ; the vaginal discharge always mixed with more or less blood. To-day she complains of pain and tightness across the breast, on left side. There is dyspnoea. The heart's action violent—pulse small and jerking.—

*September 28*, Much weaker ; aspect exsanguine ; countenance anxious. No pain or hemorrhagic discharge.—*October 7*, Has continued to lose strength. Three days ago the pain and bloody discharge returned. Died at half-past two, A.M.

*Sectio Cadaveris, October 9th.*

The body is of cachectic aspect, and unusually loaded with fat.

*Head* not examined.

*Chest*.—About a pint of clear amber-coloured serum occupied both cavities of the pleura. Pleura on right side slightly adherent by bands of chronic lymph. Both lungs were gorged, and loaded with yellow serum. *Heart* of normal size. The right auriculo-ventricular orifice so large as readily to admit the whole hand. Valves healthy.

*Abdomen*.—*Liver* enlarged, weighed four pounds six ounces. It was of a pale-yellowish colour throughout, and had undergone the complete fatty degeneration. The *left kidney* was of normal size, the cortical substance of whitish-yellow colour throughout, and of fatty aspect, presenting the so-called second stage of Bright's disease. The *right kidney* small, about the size of a goose's egg. The cortical substance indurated, and of white colour, with no trace of tubular substance. The pelvis and calyces, distended with urine, presented a series of sacs the size of marbles opening into each other. The *peritoneum* lining the pelvis was covered with shreds of recent lymph, and its cavity occupied by about half a pint of light yellow turbid serum. The *uterus* was much enlarged. The inferior half of the fundus transformed into a fungoid, sanguinolent soft mass, presenting all the characters of encephaloma. The cavity enlarged, presenting a greenish bloody, irregular lining. The os uteri the size of half-a-crown, irregular, nodulated, with projecting masses of fungoid disease. The superior half of the fundus of normal aspect, soft to the feel ; on section, allowing a milky cancerous juice to be squeezed from the cut surfaces. Other organs healthy.

*Microscopic Examination*.—The milky fluid squeezed from the cut fundus of the organ contained corpuscles of a round or oval form, varying in size from the 1-50th to the 1-18th of a millimetre in diameter. Some of the larger contained greatly developed nuclei, containing one or two nucleoli. One is represented (Fig. 34), with a nucleus about the 1-30th of a millimetre in diameter, containing two oval nucleoli. The largest the 1-50th of a millimetre in its longest diameter. These cells were mingled with a few naked nuclei, and numerous granules. The action of acetic acid was the same on these as on other cancer cells. A thin section with a scalpel from the cut surface of the fundus, presented a fibrous mass so dense, that the direction of the filaments or their arrangement could not be discovered. On washing out the cells with water, however, and adding acetic acid, the fibrous matrix was seen to be made up of the elongated

nuclei of fusiform corpuscles (Fig. 35), closely crowded together, assuming here and there a looped appearance of an oval form, or a rounded concentric arrangement. In some places concentric circles containing cancer cells were visible, as in Fig. 2.

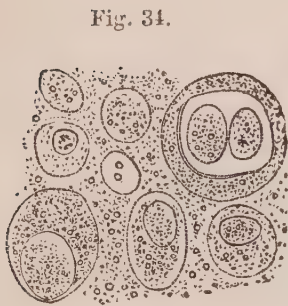


Fig. 34.




Fig. 35.

*Fig. 34. Cancer cells in juice squeezed from uterus, described Obs. XIII. Fig. 35. Fibrous stroma of the uterus acted on by acetic acid.*

*Remarks.*—Here also the cancer cells had arrived at a very large size, as in the last case. It would seem that in the uterus these cells multiply very rapidly, and quickly produce great destruction of parts. Thus, in Obs. XII., the large masses of new growth formed could only be traced clinically nine months back, and in the present one only four months; and it is very likely that the increase of the cancerous formation is dependent on the excessive power of development of the cells.

#### OBSERVATION XIV.

##### CANCER OF THE UTERUS—PERITONITIS—DEATH.

AGNES SUTHERLAND, a fisherwoman, aged thirty-nine, admitted September 15, 1845, into the Royal Infirmary, under Dr Alison. The patient is a widow, and the mother of five children. She has an exsanguine appearance, and states that, nine months ago, she first perceived a leucorrhœal discharge, which she attributed to fatigue and cold. Subsequently discharges of blood appeared, which have continued ever since, mingled with coagula. On admission she complains of pain in the abdomen, where there is considerable tenderness and tympanitis, particularly over the umbilical region. There is also great thirst, hot skin, furred tongue, and rapid pulse. The bowels are constipated, and she complains of weakness of the back. Notwithstanding the employ-

ment of appropriate means to combat the peritonitis, she died on the morning of the 17th.

*Sectio Cadaveris, September 18th.*

The *head* was not examined.

*Chest.*—The cavity of each pleura contained about half a pint of turbid yellowish fluid ; but there were no flakes of lymph, nor adhesions. The left lung was puckered at its apex, and contained several masses of old tubercle, passing into cretaceous concretions, and surrounded by a firm fibrous cyst of a black colour. The lungs otherwise were healthy. The pericardium contained three ounces of clear serum. The heart was healthy.

*Abdomen.*—The peritoneal cavity was much distended with gas and fluid.—The latter, amounting to about two quarts, was of a yellowish, purulent looking character, and contained numerous flakes of soft lymph suspended in it. This lymph formed a coating, in some places a quarter of an inch thick, over the abdominal surface of the diaphragm and liver. It was also diffused over the peritoneal coat of the intestines, but to a much less amount, and gave to the peritoneum a villous look, somewhat like mucous membrane. The intestines, both large and small, were much distended with gas ; and they, together with the large omentum, were matted together by soft recent adhesions. The liver was pale and fatty, weighing 3 lbs. 8 oz. The kidneys were pale and flabby. The right one was much atrophied, both cortical and tubular portions being affected ; whilst the pelvis was dilated, and capable of containing a large walnut. The pelvis was entirely filled with a firm tumour, which, on removal, and a section being made of it, was found to be owing to an enlarged and cancerous uterus. The superior half of the organ was hypertrophied : its walls an inch in thickness, and on pressure it exuded large drops of a white creamy viscous fluid. The inferior half of the organ, and upper portion of the vagina, were converted into an irregular, fungoid, cancerous mass, of a dirty greenish colour, covered with pus, and mingled with the creamy fluid just noticed. The fundus of the uterus was elevated above the brim of the pelvis, and firmly united to the inferior knuckles of intestine, and margin of the large omentum. These, together with several enlarged cancerous lumbar glands, formed one mass of disease.

*Microscopic examination.*—On examining the creamy fluid squeezed from the body of the uterus, it was found to contain numerous cancer cells densely crowded together. When separated by means of water, they were found to vary greatly in size and form, several being more or less caudate or spindle-shaped. The round and oval corpuscles presented the same appearance described in former observations, and varied in size from the 1-150th to the 1-30th of a millimetre in diameter. The caudate and spindle-shaped cells contained a round nucleus about the 1-100th of a millimetre in diameter. The cells of some of the former were cleft at one extremity, or presented two unequal prolongations—(Fig. 36). Acetic acid partly dissolved the cell walls, whilst the nuclei remained unaffected.

The milky fluid squeezed from one of the enlarged lumbar glands contained

cancer cells, mingled with fusiform and compound granular corpuscles. The first varied in size from the 1-150th to the 1-25th of a millimetre in diameter, with nuclei also varying in size. In one cell, figured Fig. 37, the nucleus is seen greatly enlarged, measuring about the 1-30th of a millimetre across, with one oval nucleolus in its wall containing two granules. The compound granular corpuscles were of great size and beauty, and existed in various stages of development, some only half, and others completely full of granules. One of the latter, 1-20th of a millimetre in diameter, is represented in the figure— (Fig. 37).

Fig. 36.

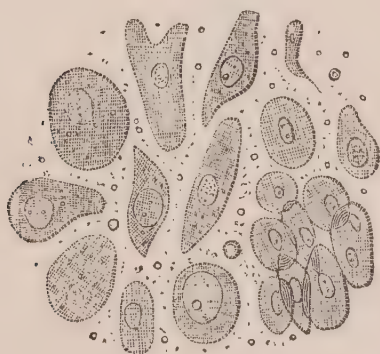

Fig. 37.

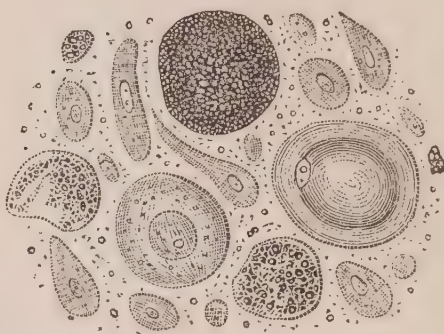


Fig. 36. Cancer cells in the juice squeezed from uterus, described Obs. XIV. Fig. 37. Cancer cells in the juice squeezed from a lumbar gland in the same case.

*Remarks.*—In this case we observe that the cancer cells from the uterus varied greatly in shape from those which existed in the two former observations (Obs. XII. and XIII). The general appearance of the cancerous alteration, however, as well as all the other elements of its structure, remained the same. The disease was of nine months standing, and yet the cancer cells were not so well developed as those in the last observation, where the uterus had apparently only been affected four months. Hence the duration of a disease bears no proportion to the development of the constituent cell elements of which it is composed. On the other hand, the cancerous juice in the lumbar gland presented some peculiarities. It contained numerous compound granular cells, whilst in that squeezed from the uterus not one was to be observed. Are we at liberty to draw any conclusion from this fact respecting the relative age of the cancerous formation? To this point we shall pay especial attention in a subsequent part of this paper.

## OBSERVATION XV.

## CANCER OF THE UTERUS AND LUMBAR GLANDS—DEATH.

BETTY BROWN, æt. forty, admitted February 22, 1846, into the Royal Infirmary under the care of Dr Patterson. She is much emaciated, and has a pale sallow complexion. She has had six children, the last fourteen years ago, and all without any bad symptoms. For the last ten years leucorrhœa has been present; menstruation has been regular until last May, when a bloody discharge took place every two or three days, up to October. In that month, considerable hemorrhage occurred at intervals during a fortnight. It then ceased, but returned eight weeks ago, and continued three weeks. A week ago it occurred again, but only lasted four days, and was slight. During the interval between the first and second flooding, a thin watery discharge of a very offensive odour came away. Each flooding was preceded by a gnawing pain in the uterine region, which, on its commencement, disappeared. At present there is a profuse watery discharge from the vagina, communicating to her person a very offensive odour. She passes urine without difficulty. The appetite is bad.—*March 3d*, A swelling may be detected in the pelvis, above the pubes, the size of which cannot be determined.—*March 16th*, The discharge has much diminished. There is no pain. Appetite improved. Bowels kept regular by medicine. On examination of the os and cervix uteri, they were found ulcerated to a great extent, and a white foetid fluid flowed from the speculum.—*March 31st*, The discharge has again become abundant, and is very fetid. She complains of pain in the back and lower part of the abdomen, which is increased on pressure. The tumour formerly felt is apparently larger, and can be detected more in the centre of pelvic region.—*April 14th*, Has continued to suffer great pain, and has become very weak from the incessant discharge and absence of appetite. She gradually sunk and died, *April 19th*.

*Sectio Cadaveris, April 21.*

*Head* not examined.

*Chest*.—Lungs pale; emphysematous anteriorly, and superiorly much loaded with carbonaceous matter.

*Abdomen*.—The pelvis was entirely filled up with indurated nodulated masses, which compressed the right ureter below, causing it to be distended superiorly with fluid. On removing the pelvic contents, and subsequently examining them, it was found that, at the upper end of the vagina, a cavity the size of an orange had been formed. The walls were of a dirty green colour, rough, and uneven on the surface, from which a dirty brown opaque fluid could be squeezed. It presented all the characters of cancerous ulceration in its last stage. The os and cervix uteri had completely disappeared; the upper half of the fundus only preserving its healthy appearance. The ulceration was separated from the cavity of the abdomen by the peritoneum, which was united to the ovaries and several enlarged lumbar glands, by bands of chronic lymph. These, together with the distended vagina, formed the mass which

filled up the pelvis. The adherent lumbar glands were as large as marbles and pigeon's eggs, and, on section, presented a smooth surface of whitish-yellow colour, and of soft, cheesy consistence. The ovaries, on being cut into, presented several cicatrices loaded with black pigmentary deposit.

The right kidney was diminished to the size of a hen's egg, and anemic throughout. The cortical substance was much atrophied, being at its thickest portion only one-eighth of an inch in depth. The tubular cones were small, short, but healthy in structure. The pelvis was much enlarged; it, as well as the ureter, distended with pale urine,—the mucous surface healthy. Left, kidney anemic, but otherwise healthy. The right ureter was about the size of the little finger, and distended with fluid, evidently from the obstruction it had received in the pelvis. Other abdominal organs healthy.

*Microscopic Examination.*—On examining a lumbar gland about the size of a pigeon's egg, it was found to be infiltrated with the corpuscles, represented Fig. 38. These consisted, for the most part, of variously shaped, somewhat flattened cells; some round and oval; others squarish, triangular, or more or less indented, as if collapsed or pressed upon. A small nucleus could only be seen in a few. For the most part, they contained nothing but molecules and granules, either scattered thinly throughout their interior, or confined in a group to the centre. They varied in size from the 1-100th to the 1-40th of a millimetre in diameter. It was not possible to determine whether the former or smaller ones were free nuclei or not. Acetic acid rendered the cell walls slightly more transparent, but otherwise produced no change upon them. They floated amidst a multitude of loose molecules and granules.

Fig. 38.



Fig. 38. Retrograde cancer cells from a lumbar gland, Obs. XV.

*Remarks.*—This woman had laboured under leucorrhœa for ten years; yet the functions of the uterus were not seriously deranged until about twelve months previous to her decease. The possibility of forming any precise notion of when the disease commenced, is, in this as in most other cases, impossible. The appearances discovered on dissection, however, prove it to have been very old. The cancerous formation in the uterus had softened and been discharged by the vagina, leaving a cavity, presenting on its walls the appearance

of chronic ulceration. The section of the lumbar glands, one of which only I had it in my power to examine, presented a whitish-yellow colour, and cheesy consistence, without yielding any cancerous juice. It resembled the so-called reticulum of Müller's *Cancer reticulare*, and the yellowish material described in Obs. X. and XI. Its minute structure, however, presented a cell formation very different. The cell-walls were here and there partly collapsed, as in Obs. XI.; but in the majority the nucleus had disappeared, and, instead of it, a number of molecules and granules existed. Are we to suppose these to be a disintegration of the nucleus, or the result of endosmosis through the cell-wall? However this may be, there can be little doubt that the appearances described constitute one mode of the retrograde course of the cancer cell.

In the four cases of cancer of the uterus now detailed, we find that death was caused by peritonitis in two, by fatty liver and kidney in one, and by exhaustion from the excessive discharges in the fourth. In one case (Obs. XIV.), there were chronic encysted tubercles in the lungs, showing that, at an early age, the tubercular diathesis had existed and been removed, and that the cancerous disease had supervened. The existence of fatty liver and kidney in another case (Obs. XIII.), is also worthy of notice, as indicating that these degenerations may occur with cancerous as well as with tubercular formations.

I could easily have multiplied cases of uterine cancer; but as it was not in my power to add other histological facts of importance, their publication has appeared to me unnecessary. Another case, where cancer of the uterus was associated with cancer of the stomach, is recorded Obs. XXVI.

#### OBSERVATION XVI.

CANCER OF THE LIVER, STOMACH, SPLEEN, AND LUMBAR GLANDS—PNEUMONIA  
—DEATH.

JOHN DOHERTY, æt. fifty.—A shoemaker from Ireland. Admitted November 11, 1846, into the Royal Infirmary, under Dr Andrew. He entered the army at the age of twenty-three, and was almost immediately sent to India, where he remained seven years. He did not live intemperately, and enjoyed excellent health for five years. He then experienced pains in the limbs and joints, and says he had liver complaint, for which he was actively treated. He did not recover, however, and was finally sent home and discharged. Since then

he has had good health, until thirteen weeks ago. At that time, he began to suffer from vomiting, which was arrested by medical treatment; but he has experienced severe pain in the abdomen, back, and left shoulder, with great tenderness of the epigastrium. He now suffers considerable pain in the bowels and epigastrium, which are acutely tender on pressure. Percussion and auscultation of the lungs are natural. The hepatic dulness is extended about an inch below the ribs, on the right side, and stretches considerably on the left side into the hypocondriac region.—*November 18*, The tenderness of epigastrium is diminished. The liver may be seen to have descended lower, and to be nodulated externally. To the feel, these present hard, irregular masses, the size of a walnut.—*December 5*, Since last report, he has suffered much from pain in the epigastrium, shooting backwards to the spine. There is now a distinct swelling, visible externally, situated in the epigastrium, which, on manipulation, feels hard and non-resistant, without any defined margin. Pressure upon it, causes considerable pain.—*December 20*, Since last report, the general emaciation and weakness have become very great. The tumour in the epigastrium, extending towards the right hypocondriac region, has rapidly augmented in bulk. For the last two days there has been great restlessness and fever, with slight delirium. Died at three P.M.

*Sectio Cadaveris, January 1st, 1847.*

*Chest.*—Upper lobe of right lung hepatized over an extent the size of the palm of the hand. Lungs otherwise emphysematous anteriorly, and congested posteriorly. Heart healthy.

*Abdomen.*—The liver somewhat enlarged, and studded throughout with circumscribed masses of cancer, varying in size from a walnut to that of a small orange. Several of these were prominent on the surface, and depressed, or cup-shaped, in the centre. The intervening tissue of the liver appeared healthy. On section the cancerous masses were of white colour, slightly granular surface, cheesy consistence, and yielded only here and there a milky juice, where softening had taken place. Scattered throughout this substance were small collections of a yellowish fawn-colour, and creamy consistence, reticulated together over the surface of the section. Several of the tumours were very vascular, especially at their circumference, and a few presented infiltrated extravasations of blood. The pyloric extremity of the stomach considerably indurated, extending over the posterior surface of the organ in an oval form, the longest diameter being five inches. Internally a cancerous ulcer extended over a corresponding portion of the mucous membrane, with an elevated, partly everted, edge. Here and there, external to the ulcer, there were a few nodules of indurated cancer, the size of peas, below the mucous membrane. The pylorus was so much constricted as scarcely to permit the entrance of the little finger. The body and cardiac end of the organ enormously distended. The cancerous portion of the stomach was half an inch thick, the muscular coat, occupying a quarter of an inch of this, being hypertrophied, and exhibiting a striated appearance. The spleen was small, adherent to the stomach, containing at the point of adhesion a cancerous mass the size of an almond. The lymphatic glands sur-



rounding the pylorus were enlarged, and infiltrated throughout with cancerous matter. The lumbar glands also much enlarged from a similar cause. Other organs healthy.

*Microscopic Examination.*—On examining the milky juice squeezed out of one of the nodules of the liver, at a point where it was found somewhat softened, it was seen to contain numerous delicate cancer cells. These were of a round or oval form, varying in their longest diameter from the 1-50th to the 1-40th of a millimetre in diameter. The cell walls were exceedingly thin and delicate, requiring in many instances considerable management of the light, in order to see them distinctly. They all contained one or two nuclei, which were generally of oval form, about the 1-100th of a millimetre in their longest diameter, containing one or more granules and molecules. These cells were mingled with a few naked nuclei, numerous granules, and several compound granular corpuscles and masses—(Fig. 39.) On the addition of weak acetic acid, the cell walls were rendered so exceedingly transparent that they could scarcely be seen, and resembled a faint halo round the nucleus, or a line that could scarcely be traced. This is imperfectly represented—(Fig. 40, *a*.) On adding strong acetic acid, the cell walls were immediately dissolved, whilst the nuclei remained unaffected—(Fig. 40, *b*.) The yellowish creamy matter of the reticulum was composed of minute molecules and granules of oil of various sizes, which strongly refracted light; some of the latter were 1-200th of a millimetre in diameter. They disappeared on the addition of ether, leaving behind a finely molecular matter only. The intervening substance of the liver was healthy. Want of time prevented my examining the other cancerous tissues in this case.

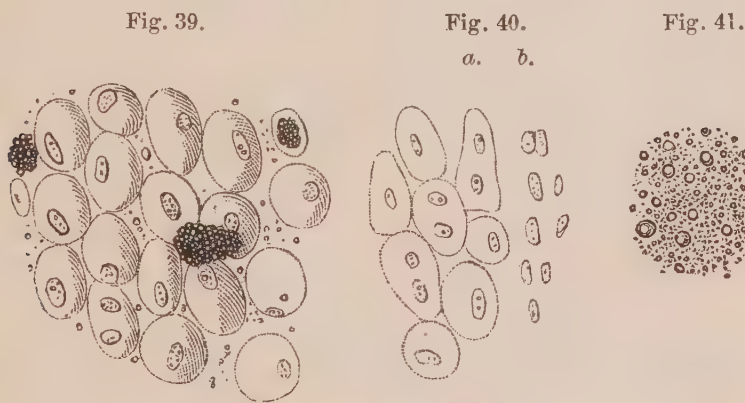


Fig. 39. Young cancer cells from the liver, described Obs. XVI. Fig. 40. The same acted on by acetic acid. Fig. 41. Molecular and granular matter of the reticulum in the cancerous masses.

*Remarks.*—In this observation we find a well-marked example of the so-called white tubercle of the liver described by Baillie and Farre. Such cases are by no means uncommon, and I have invariably found the cancerous masses to consist of a firm coagulated blastema, in which cancer cells in every stage of development could

be discovered. In the Observation just detailed, the harder nodules exhibited the morbid growth proceeding slowly in its development. Even where softening had taken place, the cells were exceedingly delicate, exhibiting a very early stage of growth. It is important to remark, that notwithstanding the early stage in development of the cancerous tubera, a section of them presented a well-marked reticulum, with the same structure as we have seen in cancer of the breast.—(Obs. V.) The question as to whether the accumulation of these fatty granules is a contemporaneous or a subsequent process, and its influence on these growths in general, can only be deduced from careful examination of their existence in relation to the cancer cells in a series of observations.

Although I had no time to make careful examinations and drawings of the changes in the stomach and other organs, I convinced myself, from a few demonstrations, that these changes depended on cancerous growths in different stages of development. From the history of the case it would appear, that in India he suffered from vomiting, epigastric pain, and other symptoms, which are commonly spoken of under the name of liver complaint. It is probable, for reasons which I shall hereafter allude to in connexion with cancer of the stomach, that that organ was the one primarily affected in this case, and had probably existed for years. It would seem that, notwithstanding the extensive cancerous deposits which existed, his general health was tolerably good, until thirteen weeks previous to admission, and about twenty weeks previous to his death, which, probably, was accelerated by the limited pneumonia which latterly made its appearance.

#### OBSERVATION XVII.

##### CANCER OF LIVER, PANCREAS, AND NEIGHBOURING LYMPHATIC GLANDS—DEATH.

JOHN LAWRIE, *æ*t. fifty, flesher.—Admitted into the Royal Infirmary, March 24th, under Dr Robertson. He has been in prison for the last four years, and has enjoyed good health until three weeks ago, but since then has become more and more emaciated. He has also felt pain in the lumbar region, and his legs and feet have become swollen. On admission, the face is sallow and haggard, and there is œdema of the legs. He complains of slight pains in the abdomen, on examining which the liver was found greatly enlarged. It extended two inches below the umbilicus in the middle, but not quite so low on each side. The edge is rounded, and it is easily moved. There is some tenderness on the

lower and outer part of the right lobe. He has huskiness of the throat, which is dry and red; the velum pendulum is aphthous. The appetite is diminished. There is great thirst. Pulse 88, weak. It is stated that before his imprisonment he was very intemperate. Died March 28th.

*Sectio Cadaveris, March 31st.*

*Head.*—The brain and its membranes were healthy.

*Chest.*—Pleura on both sides adherent posteriorly by chronic adhesions. On the left side also, there were firm adhesions towards the apex. Both lungs much engorged inferiorly, so much so that the section presented a smooth polished surface, and portions of it sunk in water. The apex of left lung somewhat puckered. The parenchyma below it, indurated from dense carbonaceous deposits. Several of the minute bronchi were obliterated, presenting lines of dense fibrous tissue, which, here and there, were of stony hardness from deposits of earthy matter. *Heart* healthy.

*Abdomen.*—The liver was greatly enlarged, occupying the whole breadth of the abdomen, and descending inferiorly two inches below the umbilicus. It weighed 13 lbs. 12 oz. Externally it presented a crimson purple ground, scattered all over with white spots and masses varying in size, running together, and giving it a porphyry-like appearance. On section it was seen to be infiltrated throughout with soft cancerous matter, which could be squeezed from its surface in the form of a milky juice. It was nowhere gathered together so as to form masses or tumours, but was scattered throughout the organ in minute points, which, by coalescing here and there, formed patches of greater or less extent. In the left extremity of the pancreas there were several tumours, the size of small marbles, of white cancerous deposit. The lymphatic glands in the neighbourhood of the pancreas and stomach, were greatly enlarged from the same soft cancerous infiltration; the largest was about the size of a walnut. The mesenteric and lumbar glands were all similarly diseased. The kidneys presented the second stage of Bright's disease, the external surface exhibiting the roe-like aspect, well marked. On the right side the tubular cones were much encroached upon; on the left, they were unaffected. Other organs healthy.

*Microscopic Examination.*—The milky juice squeezed from the liver contained numerous cancer cells of different forms. Some were round or oval, varying in size from the 1-50th to the 1-40th of a millimetre in diameter. Others were caudate, spindle-shaped, or more or less compressed at the sides. They were nearly all furnished with nuclei, of round or oval shape, varying from the 1-100dth to the 1-80th of a millimetre in their longest diameter. Several of these may be seen (Fig. 42) to contain a double nucleolus together with several molecules. One half moon-shaped cell in the figure, contains two nuclei of about the same size, both of which possess four nucleoli. On the addition of acetic acid, the cell walls were rendered more transparent, whilst the nucleus appeared somewhat contracted and with a thicker edge. Mingled with the corpuscles were numerous molecules and granules, with a few compound granular corpuscles and masses. The hepatic cells between the cancerous

infiltration were carefully examined, and found to present their normal appearance, with the exception of a few brownish irregular masses adhering to some of them, which were apparently clotted blood.

The milky fluid squeezed from an enlarged lymphatic gland, size of a walnut, below the pancreas, contained the corpuscles represented Fig. 43. Some of these were of an oblong form, with an oval nucleus and two nucleoli. A few were caudate. Several naked nuclei, blood corpuscles, granules, and compound granular masses, were also present. Scattered throughout the substance of this gland was a distinct reticulum, of a fawn colour and cheesy consistence, which was composed of broken down cancer cells, and irregular shaped bodies, exactly like those seen in Obs. X., Fig. 27.

The cancerous masses in the pancreas were not examined.

Fig. 42.

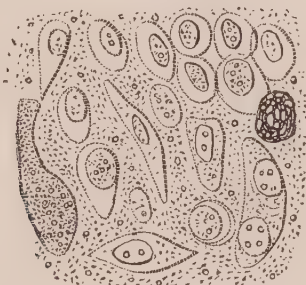


Fig. 43.



Fig. 42. Cancer cells in juice squeezed from liver, described Obs. XVII. Fig. 43. Cancer cells in juice from a lymphatic gland in the same case.

*Remarks.*—In this case, the cancer, instead of being disseminated in distinct masses, was infiltrated throughout the liver. The cells were also in a much more advanced stage of development than in the last Observation. In the lymphatic glands, they were evidently in a commencing state of disintegration.

### OBSERVATION XVIII.

CANCER OF LIVER, PYLORUS, LESSER AND GREATER OMENTUM AND LUMBAR GLANDS  
—FEVER AND DYSENTERY—DEATH.

BERNARD PAGAN, æt. thirty, from Ireland. Admitted into the Royal Infirmary, June 23, 1847, under Dr Robert Paterson. On the 21st instant he had rigors with nausea, followed by great heat, and the usual symptoms of fever, to the contagion of which he had been exposed. He is much emaciated, and, previous to admission, has suffered from want of food. Since Monday also, there has been diarrhœa, and at present the stools are frequent, watery, and slimy. The skin is dry and warm, and of a dingy hue.—*June 26th*, To-day the stools are of a light colour, with much mucus tinged with blood.—*July 4th*, The stools are muco-purulent, with some streaks of blood, and their passage

is accompanied by pain and much straining. No tympanitis or tenderness of abdomen on pressure.—*July 9th*, Much singultus.—*July 17th*, Hiccough less frequent. Tongue clean and glazed. Takes his food but sparingly. Emaciation continues. Stools still muco-purulent, with occasional masses of mucus tinged with blood.—*August 6th*, The muco-purulent and sanguineous discharges have continued, the strength has lessened gradually, and he sunk this morning.

*Sectio Cadaveris, August 8th.*

The body was much emaciated; abdomen flattened from the retraction of the parietes.

*Chest.*—The lungs were congested posteriorly, especially the lower lobe of the left lung, where pressure caused to exude from the cut surface a copious frothy fluid. *Heart* healthy.

*Abdomen.*—The opposed surfaces of the liver and diaphragm were closely united by old cellular adhesions, which were strongest in the neighbourhood of and to the right side of the insertion of the falciform ligament. Between fifteen and twenty spherical masses of a whitish colour, varying in size from a cherry to a chestnut, were disseminated through the middle third of the right lobe of the liver. Several of these masses were visible on the superior, but none on the inferior surface of the organ. They were all abruptly bounded by healthy hepatic substance, were of somewhat friable consistence, but yielded a milky fluid on pressure. Some of these masses of deposit contained softened cavities varying in size, in some cases occupying the centre, in others situated near the circumference, filled with a turbid whitish fluid. The left lobe of the liver was free of the cancerous deposit, but presented a few round cavities, varying in size from a pea to a hazel-nut, directly bounded by the surface of the organ, and filled with deep black blood of the consistence of mucilage. The small omentum surrounding the hepatic ducts and vessels, contained several cancerous tumours, varying in size from a pea to a hazel-nut. The mucous coat of the stomach was unusually pale, but healthy. The pyloric orifice barely admitted the passage of the little finger; it was constricted by a cancerous mass, situated between the mucous and muscular coat, in size between that of a pigeon and small hen's egg. The mucous and serous coats of the pyloric orifice were healthy, but the muscular coat was much hypertrophied, the sixth of an inch in thickness. On the mucous surface of the duodenum, near its commencement, two cancerous tumours of the size of peas were seen. The whole of the great omentum was studded with cancerous tumours, varying in size from a pea to that of a cherry, and some of these were of a dull, purplish hue. In the situation of the left supra-renal capsule was a mass of cysts of the size of walnuts, containing fully an ounce and a half of thick dark blood, resembling that contained in the cavities in the left lobe of the liver, and one of these cysts was half filled with a soft cancerous deposit, in part discoloured by blood. The lumbar and mesenteric glands were much enlarged, and of firm consistence. They grated somewhat under the knife on section, were generally of a pinkish white colour, and contained little yellow masses of

friable deposit, sparingly scattered through their substance. They were here and there tinged of a deep blue colour by the ramification of vessels loaded with blood.

The descending colon and rectum were contracted in size, and their coats were thickened and corrugated. Their mucous surface was here and there coated with patches of reddish granular lymph, and presented numerous circular ulcerations, occupying the situation of the glandulæ majores simplices. They were of uniform size, about a line or a line and a half in diameter, not exposing the muscular coat. They were encircled by a narrow areola, of a dark livid hue, and their borders were not elevated. They appeared, as it were, punched out of the mucous membrane. Little tumours of the size of small peas, resembling those in the omentum, were seen loosely attached to the serous surface of the rectum, and several of the meso-colic glands were of the size of hazel-nuts, and infiltrated with cancerous deposit.

*Microscopic Examination.*—The cancerous juice squeezed from the liver contained three distinct kinds of corpuscles:—*1st*, Numerous well-formed cancer cells, with one or two nuclei, and a single or a double nucleolus; *2dly*, Compound granular cells; and *3dly*, Pus corpuscles, which were mingled with the cancer cells in considerable numbers—(Fig. 44.) On the addition of acetic acid, the distinction between the cancer and pus cells was rendered very apparent. The former had their cells rendered very transparent, whilst the nuclei were either unaffected, or their margins were rendered thicker. The latter had the cell-walls dissolved, and the characteristic nucleus of two or three granules rendered apparent—(Fig. 45.) A few naked cancer nuclei and numerous granules were mingled with these corpuscles.

On examining the yellow masses in the mesenteric glands, which grated somewhat on section, they were seen to contain,—*1st*, Numerous cancer cells in a state of disintegration; the cell walls more or less collapsed, contracted, and so altered in shape as to present no distinctive form. In several, no nucleus

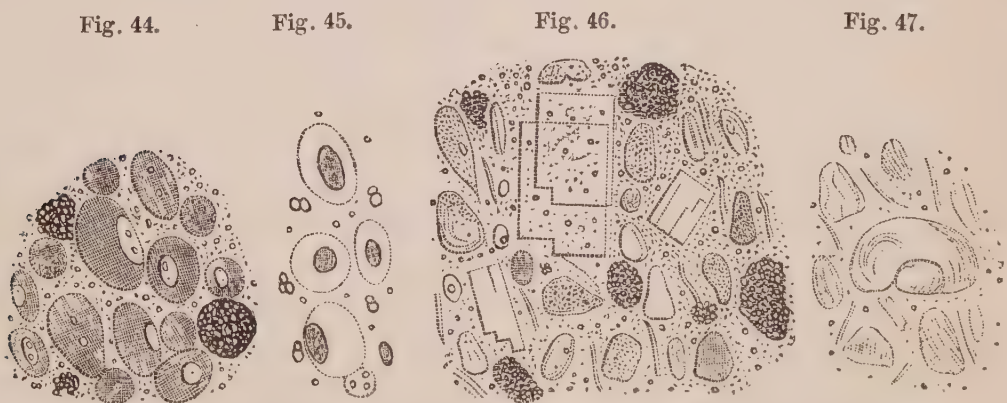


Fig. 44. Cancer and pus cells in juice squeezed from liver, Obs. XVIII. Fig. 45. The same acted on by acetic acid. Fig. 46. Retrograde cancer cells, crystals of cholesterine, and masses of mineral granules, in the yellow masses of the lymphatic glands in the same case. Fig. 47. The retrograde cancer cells acted on by acetic acid.

could be seen, and its place was occupied by a number of minute molecules; in others, two or more granules could be discerned. *2dly*, Small fusiform cor-

puscles, more or less broken down. *3dly*, Numerous laminated crystals of cholesterine. And *4thly*, Numerous granules, here and there aggregated into masses. Some of these were fatty; others, from their irregular form, were evidently mineral in their nature—(Fig. 46.) On the addition of acetic acid, the abortive cancer cells became generally more transparent, the fragments of fusiform cells and crystals of cholesterine remained unchanged, whilst the mineral granules and masses were dissolved—(Fig. 47.) One cell in this figure is seen of large size, distinctly nucleated, with its walls collapsed.

*Remarks.*—In this case there had supervened on the cancerous disease of the liver a recent exudation, which had become transformed into pus. This is an occurrence, I am inclined to think, of considerable rarity. In this also, as in the last Observation, the cancer cells of the lymphatic glands were undergoing disintegration. Conjoined with this we observe, first, an excessive formation of fat, in the form of cholesterine; and secondly, the accumulation of earthy salts, in the form of granules. We shall afterwards see, that this latter occurrence is one of the means whereby cancerous formations are so transformed as to be rendered latent in the system. This must be considered as a very chronic case of cancer, and remarkable from the circumstance that, notwithstanding the great amount of disease present, there were no symptoms which indicated its existence. The man complained of nothing but the fever which was then prevalent in Edinburgh, and of dysentery, which was also epidemic. It may be asked, whether the latter disease was in any way connected with the purulent formation in the liver?

#### OBSERVATION XIX.

CANCEROUS ULCER OF STOMACH—STRICTURE OF PYLORUS—CICATRICES IN THE LIVER—CALCAREOUS CONCRETIONS IN MESENTERIC GLANDS.

MARY ANNE RAMSAY, æt. forty-three, a widow, was admitted into the Royal Infirmary, August 25, 1844, under the care of Dr Alison. She states that two years ago the catamenia stopped, and that her health has been very indifferent ever since. For ten years she has occasionally experienced pain in the stomach after taking food, which has become more continued and violent since the period referred to. She was treated for this complaint in the Infirmary last October, and was dismissed free from pain. It returned, however, three months ago, and has continued ever since, accompanied by acid eructations and occasional diarrhœa. There has been no hemoptysis or hematemesis. She has had palpitation more or less severe for two years, leucorrhœa for three years, and dysuria for twelve months.

On admission there is severe pain in the epigastric region ; very severe half an hour after taking food. There are rather violent pains all over the abdomen, but no tenderness ; there is diarrhœa. A fœtid discharge flows from the vagina, and she experiences a sharp pain on passing urine. There is great thirst, sweating at night, temperature of skin natural ; appetite somewhat better, she says, than usual. Respiratory and heart sounds natural.—*September 14th*, Since admission has had occasional diarrhœa, which was readily checked. The pain in the stomach, with vomiting, has continued.—*October 25th*, Vomiting of acid matters and of food continues. Emaciation has made great progress. There has been occasional cardialgia, with tenderness on pressing epigastric region. To-day a circumscribed swelling could be detected in region of the pylorus.—*November 16th*, The symptoms have continued, the emaciation has increased, her strength has rapidly diminished, and she sunk this evening at 9 P.M.

*Sectio Cadaveris, November 18th.*

*Chest.*—Both lungs were adherent at their apices. On the left side there was a deep cicatrix, with considerable puckering at the apex of the lung, which to the feel resembled an indurated nodule about the size of a walnut. On section it was found to consist partly of cheesy tubercular matter, and partly of gritty calcareous matter. On the right side was also a cicatrix, with puckering at the apex, but of much smaller extent, with induration of the pulmonary tissue, without the traces of tubercular deposit. The lungs were otherwise healthy. The heart was small ; the coronary arteries rigid, from calcareous and atheromatous deposits ; the lining membrane of the arch of the aorta studded with similar deposits.

*Abdomen.*—The liver was somewhat atrophied, and presented on its surface several deep puckerings and depressions, which corresponded to indurated yellowish masses in their centres, varying in size from a pea to that of a hazel nut. These masses were of firm cheesy consistence, slightly grating under the knife, and on section presented a somewhat fibrous matrix. The hepatic substance in their immediate vicinity appeared to be healthy. The stomach was firmly adherent posteriorly to the pancreas, and to several lymphatic glands, which were enlarged and of white colour. On being opened, the organ was found to be considerably distended with a semi-fluid brownish matter. The pylorus was considerably constricted, apparently from the formation of cancerous deposit, so as scarcely to admit the forefinger. Extending from it, on the posterior wall of the stomach, corresponding to the firm adhesion between it and the pancreas, was an oval ulcer about two inches in its longest diameter. The edges were raised nearly a quarter of an inch above the level of the mucous membrane, were of soft consistence, easily breaking down between the fingers into a pultaceous dirty white substance. The base of the ulcer was formed by the muscular coat. The mesenteric and epigastric glands considerably enlarged, and of white colour. Some felt hard, from calcareous depositions ; others were infiltrated with a putty-like substance ; and a few were composed of an external shell of hard calcareous matter, whilst their interior consisted of a semi-



fluid, gritty, diffuent material, which flowed out on breaking them. The other organs were healthy. The uterus was not examined.

*Microscopic Examination.*—On squeezing a little of one of the yellow masses in the liver between glasses, and examining it under the microscope, it exhibited a substance so dense that its integrant parts could not be made out. Several stellate crystals of margarine, however, could be detected here and there, as seen on the right of Fig. 48. On diluting the mass with a little water, it was seen to be composed, 1st, of round or oval corpuscles, with faint and somewhat flaccid cell walls, containing several molecules and granules, and in a few one or even two nuclei could be detected: they varied in size from the 1-100th to the 1-35th of a millimetre in diameter; the smaller ones resembled free nuclei; 2d, of margarine, in groups of needle-shaped crystals; 3d, of numerous granules and molecules, which had a disposition to collect in small groups—Fig. 48. On the addition of acetic acid, the walls of the corpuscles became more faint, but no other change was produced. Ether at once dissolved the granules and needle-shaped crystals.

The putty-like substance, and diffuent matter in the mesenteric glands, contained similar corpuscles, though smaller, and varying more in shape. They were mingled with numerous irregular-shaped granules, and masses of mineral matter, which were entirely dissolved in weak nitric acid—Fig. 49.

A thin slice of the strictured portion of the pylorus was composed of a dense fibrous texture, which, on the addition of acetic acid, became more transparent, and exhibited elongated nuclei, such as is represented Fig. 15, and will be again figured when I describe cancer of the stomach. No cancer cells could be squeezed out of it, or were to be seen between the meshes. The surface of the ulcer in the stomach consisted of the debris of epithelium cells, shapeless flakes, and a multitude of molecules and granules, exactly similar to what is found on the surface of most sloughing ulcers. On dissecting below the epi-

Fig. 48.

Fig. 49.

Fig. 50.

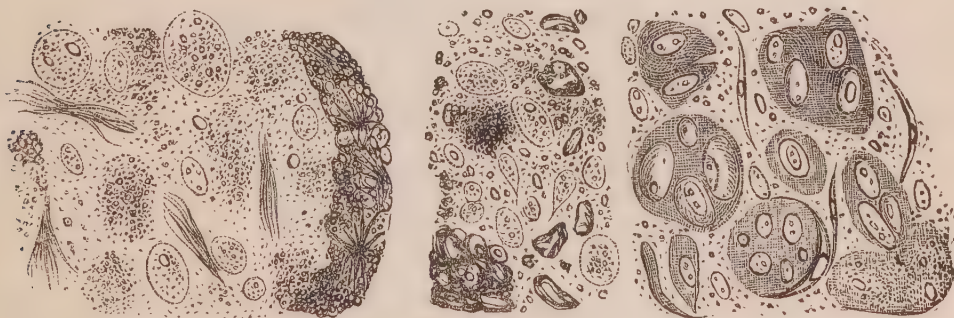

Fig. 48. Retrograde cancer cells, and crystals of margarine in yellow masses of liver, described Obs. XIX. Fig. 49. Retrograde cancer cells with mineral matters from mesenteric glands in the same case. Fig. 50. Cancer cells and nuclei imbedded in a granular blastema, with fusiform corpuscles, from the stomach.

thelium, the raised border of the ulcer was found to be continuous with an indurated mass of a flesh colour, which united the stomach firmly to the pan-

creas. This mass was composed of a fibrous matrix, in the meshes of which numerous cancer cells and free nuclei were crowded together. The fluid scraped from the surface of this growth was of an amber colour, and turbid. It contained cancer cells and nuclei imbedded in a finely granular blastema, which assumed various shapes and sizes, according as it was more or less broken up. The number of naked nuclei were in excess. The cells were in general oval, their walls very delicate, and did not exceed the 1-40th of a millimetre in their longest diameter. Several fusiform corpuscles were present, some of which, from their curved form and adhesion to masses of granular blastema, appeared to form the boundary of what seemed a compound cell—Fig. 50.

*Remarks.*—This case is an exceedingly interesting one in many points of view. It offers, in my opinion, strong proof of the spontaneous cure of cancer in an organ, and that in two different ways. Not that one case alone would be sufficient to prove this statement, but that, in conjunction with others which have been previously, and will subsequently be given, little doubt, I believe, can exist as to the true cause of the appearances described. The facts to which I would particularly direct attention in this Observation are, 1<sup>st</sup>, The retrograde course of cancer in the liver, with excess of fat formation; 2<sup>d</sup>, The retrograde course of cancer in the mesenteric glands, with excess of mineral deposition; 3<sup>d</sup>, Chronic stricture of the pylorus; and, 4<sup>th</sup>, An unequivocal cancerous ulcer in the stomach.

It is by no means uncommon to find puckerings, with yellowish masses, in the liver. This may arise from former depositions of tubercle, chronic abscesses, or cancerous formations. Either of these forms of exudation, after having gone through their ultimate stage of development, may shrivel up, become drier and drier, and cause contraction and puckering of the surrounding tissue. On examining these remains of former exudation, it is exceedingly difficult to determine from their structure what was their former nature, inasmuch as all kinds of retrograde exudation present characters more or less in common. It is only, then, from concomitant circumstances that we can be led to a correct deduction. But here this case presents a great difficulty. This woman had evidently laboured under previous tubercular exudation in the lungs; and it may be argued, that the yellow masses and puckerings in the liver, as well as the calcareous concretions in the mesenteric glands, were rather owing to similar deposits in those organs than to previous cancer. In fact, we have seen in a former observation (Obs. XIV.), how cancer

may coexist with traces of previous tubercular deposition in the lung. But here we have also stricture of the pylorus, which was evidently chronic, as it was unaccompanied by recent cell formation. Subsequent observations, I think, will render it probable that this lesion is more allied to cancerous than to tubercular exudation, and favour the supposition, that the alterations in the liver and lymphatic glands were owing to cancer also. Besides, the corpuscles in both situations exactly resemble the retrograde cancer cells we have seen previously (Obs. XI. XV. XVIII.), and are in no way like retrograde tubercle corpuscles. Neither did they resemble the hepatic cells in the immediate neighbourhood, which, although somewhat loaded with fat, were otherwise healthy. To these arguments may be added another, derived from the fact, that cancer in an active state of development existed in the stomach at the period of death.

The appearance of the cancer cells in the stomach merits special observation. Most histologists who have paid attention to the structure of cancer, have described compound cancer or mother cells. For a long time I conceived that the structures represented, Fig. 50, were beautiful specimens of this formation. Later observations, however, have convinced me that the appearances described are owing to the imprisonment of nuclei and cells in a finely granular blastema, broken up into various sized masses. I was unable to detect any cell-wall surrounding them, and, on adding water, the granular matter is separated, and the nuclei and cells float loose. Here and there clefts or divisions may be seen between these masses. This fact has been previously observed by Küss (see Sédillot on Cancer, Planche 7), who has founded upon it a theory of fissiparous multiplication of the cancer cell. In one mass, represented at the lower parts of Fig. 50, a curved fusiform corpuscle is seen to form a boundary to it, a circumstance which may also have led to the idea of such masses possessing a distinct envelope.

#### OBSERVATION XX.

##### CANCER OF THE LUNG, BRONCHIAL GLANDS, AND PERICARDIUM—DEATH.

NAPOLEON MASON, æt. forty-five, admitted into the Royal Infirmary, June 4, 1846, under the care of Dr Robertson. He has complained of dyspnoea and a dry cough for some time past, which has been gradually getting worse, and is now

attended with considerable pain. The right side of the chest is much more voluminous than the left, and is every where sonorous on percussion. In the subclavian and mammary region, the respiration is rough, and the vocal resonance increased. The chest on the left side is contracted and sunk anteriorly. On percussion there is general dulness, complete under the clavicle, limited internally by the mesian line, and gradually becoming less marked inferiorly. The respiratory sounds are heard, at the upper lobe of the lung, of a strong bronchial character, and, below this, they are faint. The vocal resonance is every where greatly diminished. The patient has a cachectic aspect, and is much emaciated. *July 3.*—Has undergone a course of mercury, during which salivation was very slight. There is now considerable dyspnoea, and he complains of pain in the cardiac region. No appetite. Loud snoring rales are heard under the clavicles on both sides, and there is great resonance of the voice posteriorly. *July 8.*—The dyspnoea has increased in intensity. The emaciation is extreme. Died at 5 P.M.

*Sectio Cadaveris, July 9, 1846.*

Body much emaciated, considerable flattening of left side of chest superiorly, which is completely dull and resistant on percussion.

*Thorax.*—The pleuræ were firmly coherent over the upper third of the left lung; so much so, that, in order to remove the organ, the costal pleura had to be stripped off. The apex of the left lung was occupied by a dense yellowish white mass, the size of a large orange, occupying one half of the upper lobe. The other portions of the lung, viewed externally, were somewhat condensed, of a bluish-green colour, but otherwise healthy. On section, the tumour presented a smooth surface of a dull white colour, of oval form, terminating with an abrupt margin externally where it was surrounded by lung; but internally it was connected with the bronchial glands, all of which were enlarged and cancerous. On pressing the tumour, a copious milky juice could be squeezed from the cut surfaces. Here and there, in the centre of the lung, surrounding the larger bronchial tubes, were isolated nodules of cancer, varying in size from a pea to a hazel-nut, apparently glands enlarged from cancerous deposit. The pericardium on the left side was considerably thickened, and closely adherent to the bronchial glands, which, by this enlargement and pressure inwards, gave it an irregular nodulated appearance when viewed internally. The heart and right lung were healthy.

The brain and abdominal organs were carefully examined, but, with the exception of general anemia and absence of blood, were healthy.

*Microscopic Examination.*—On examining the milky juice squeezed from the tumour in the lung, it was found to contain cancer cells, compound granular corpuscles, and numerous molecules and granules. The cancer cells were generally about the 1-50th of a millimetre in diameter, were both round and oval in shape, and their cell-walls were of great delicacy. They each contained an oval nucleus, varying in its longest diameter from the 1-120th to the 1-80th of a millimetre in diameter, containing one or two nucleoli, with a few molecules—(Fig. 51.) The addition of acetic acid caused the cell-wall to disappear immediately, leaving the nuclei either unchanged or slightly contracted—(Fig. 52.) A thin section of the tumour made with a common knife, exhibited the cancer cells, with numerous

masses of granules and compound granular cells, infiltrated into the filamentous tissue of the lung—(Fig. 53.)

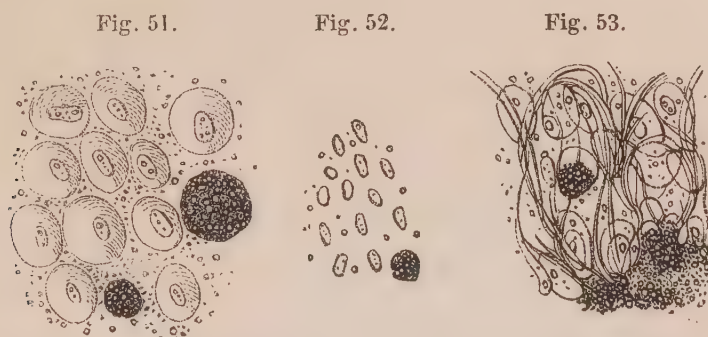


Fig. 51. Delicate cancer cells, and compound granular cells in the lungs, described Obs. XX. Fig. 52. The same after the addition of acetic acid. Fig. 53. The same infiltrated into the fibrous tissue of the lung.

*Remarks.*—This is the only case of cancer of the lung which I have ever met with; so that I presume the disease rarely attacks this organ in Scotland. There are very few specimens of it even in the museums of Edinburgh, whereas they are common in the large pathological collections of Dublin. The only circumstance worthy of remark in this Observation, is the extreme delicacy of the cells. They resembled a shadowed halo, and were very distinct, but so exceedingly transparent as to set the art of the wood-cutter at defiance. These cells were infiltrated in immense numbers into the normal structure of the lung, associated here and there with masses of fatty granules.

The only other case of cancer of the bronchial glands I have seen, occurred in the practice of Dr Taylor, who asked me to examine the body after death, June 11, 1846. In this individual (a gentleman aged 36), a tumour the size of a large orange existed above the clavicle, near its sternal articulation. On dissection, the tumour presented all the characters of soft cancer, and was evidently owing to some enlarged bronchial glands, which had become the seat of cancerous infiltration, and been pushed up behind the clavicle. Had any accidental circumstance prevented the development of the disease in this direction, the tumour would probably have pressed upon the lung, as in Obs. XX., and produced cancer of that organ. In this individual, however, there were cancerous deposits in the liver and mesenteric glands, and an enormous cancerous tumour, weighing upwards of twelve pounds, developed in the omentum, uniting all the intestines into one mass. The minute structure of these cancerous

growths presented nothing different from the forms of the disease I have already figured as occurring in the liver and mesenteric glands—(Figs. 42, 43). The abdominal tumour on section was reticulated with a fawn-coloured, and in some places bright gamboge-yellow, fatty matter (*Xanthose*, Lebert—Figs. 16, 27, and 30).

### OBSERVATION XXI.

#### CANCROID OF STOMACH, AND CANCER OF MESENTERIC AND LUMBAR GLANDS—DEATH.

MRS SINCLAIR, æt. thirty-seven, admitted October 5, 1844, into the Royal Infirmary, under the care of Dr Craigie. Sixteen months previous to admission she had fever, on recovering from which she felt severe pain beneath the lower edge of the ribs. This was followed by the occasional vomiting of slimy mucus. Two months ago she observed a swelling in the left hypocondriac region, which has continued up to the present time. *November 11.*—Since her admission has vomited daily. An indurated tumour of oval form can be distinctly felt in the cardiac region. *November 20.*—Last night she complained of intense pain in the back, and in cardiac region. The countenance was very anxious. Pulse weak and wavering. At four o'clock A.M. she became delirious, and expired at nine A.M.

*Sectio Cadaveris, November 23, 1844.*

*Chest.*—Lungs and heart healthy.

*Abdomen.*—Beneath the free margin of the liver, a hard mass formed by the enlargement of several lymphatic glands, which were adherent to the stomach and pancreas, were seen, forming the tumour spoken of in the report. The stomach itself felt hard, and, on opening it, was found greatly thickened throughout its whole extent, but more especially towards the pylorus, where it was nearly an inch thick. On section the muscular coat was seen hypertrophied, two lines thick, of a grey colour, presenting striæ at right angles with the long axis of the stomach. Within the muscular coat there was a fibrous structure of semi-cartilaginous hardness, generally half an inch in thickness, but at the pylorus an inch thick. The mucous membrane presented a brownish colour, but was otherwise healthy. Attached to the stomach externally were numerous lymphatic glands, much enlarged, varying in size from an ordinary marble to that of a walnut. They were of a light cream colour, soft to the feel, and on section presented a smooth surface, from which a copious milky-looking juice could be squeezed. The dorsal and lumbar glands, as far down as the promontory of the sacrum, were similarly affected, forming a complete coating in front of the aorta.

*Microscopic Examination.*—A thin section of the indurated and thickened portion of the stomach was found, on examination, to be composed of bands of fibrous and elastic tissue, running sometimes in a straight, and at others in a waved, direction. Here and there among these might be perceived a very few oval and round corpuscles, varying in diameter from the 1-80th to the 1-75th

of a millimetre. They contained a single round nucleus, the largest about the 1-50th of a millimetre in diameter—(See Fig. 54.) On the addition of acetic acid, the fibrous structure generally became more transparent, presenting only faint lines or striæ, whilst the filaments of elastic tissue underwent no change. The nuclei of the fibrous tissue were rendered very apparent in the form of elongated, spindle-shaped bodies—(See Fig. 55.)

The milky juice squeezed from the lymphatic glands, contained numerous cancer cells in various stages of development. They varied in size from the 1-100th to the 1-25th of a millimetre in diameter. In shape, they were for the most part round, although a few exhibited caudate prolongations of the cell wall. The nuclei varied also in size according to the stage of development of the cell, measuring in some 1-100th, and in others 1-50th of a millimetre across. Some contained one, and others two nucleoli. In a few of the larger cells no nucleus could be discovered, the contents consisting only of molecules and granules—(Fig. 56.) Many of these floated between the cells, either loose, or collected into masses more or less large.

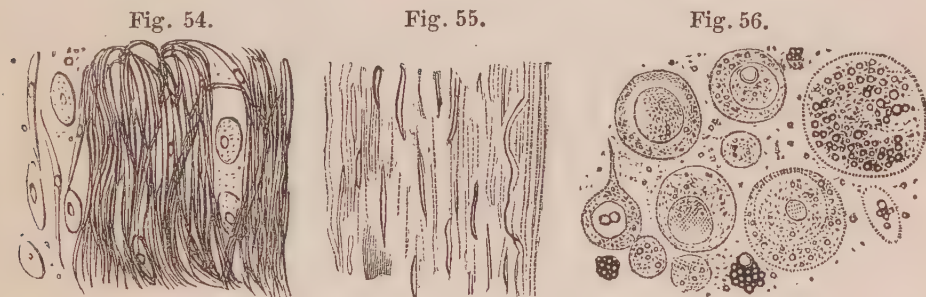


Fig. 54. Fibrous structure from thickened pylorus, described Obs. XXI. Fig. 55. The same after the addition of acetic acid. Fig. 56. Cancer cells from a lumbar gland in the same case.

*Remarks.*—In this case, the alteration which had taken place in the walls of the stomach was wholly of a fibrous character. No cancer cells could be detected, and such corpuscles as were observed, resembled in all their characters those frequently associated with filamentous tissue. These corpuscles, according to some, may ultimately be converted into fibres, and hence have been called *fibroplastic* (Lebert). At the same time, the physical characters of the thickened walls of the stomach were such as have hitherto been considered to constitute scirrhus, or hard cancer. On this account, I have ventured to call the alteration *cancroid*. It must not be overlooked, however, that whilst no cancer cells could be found in the stomach, they existed in great numbers in the mesenteric and lumbar glands. Hence a difficult question arises, as to whether the lesion in the stomach bears any relation to the cancerous formation in other structures. Are the oval corpuscles described free nuclei? These points will again be referred to in future observations.

## OBSERVATION XXII.

CANCROID OF STOMACH—STRICTURE OF PYLORUS—CONTRACTION AND THICKENING OF OMENTUM—CHRONIC PERITONITIS—DEATH.

JAMES FORREST, æt. forty-four, labourer, admitted into the Royal Infirmary, April 27, 1847, under Dr Christison. He states that he was in pretty good health until seven or eight months ago, when he first began to vomit his food, generally very soon after swallowing it, and often immediately. This was accompanied by pyrosis and pain in the stomach. He has lately become much emaciated. On admission he has no appetite, but does not now vomit his food. Tongue furred. An indurated swelling can be felt in the epigastric region, which was attributed to cancer of the stomach. He continued to be indifferent to food, and ate little. His strength gradually sank, and he died May 4.

*Sectio Cadaveris, May 6, 1847.* The body is extremely emaciated, and the countenance has a dirty yellow, cachectic appearance.

*Thorax.* All the thoracic organs healthy—blood fluid.

*Abdomen.* The peritoneal cavity contained nearly a gallon of dark transparent serum. The stomach was much contracted, its coats firm and resisting; and on section were found to be thickened universally, with the exception of a small portion towards the fundus. The cut surface of the coats of the stomach was of dirty white colour, felt tough and elastic, and thickened to the extent of half an inch in the body of the organ, but towards the pylorus the thickening amounted to fully three-fourths of an inch. The pyloric orifice, however, freely admitted the passage of the fore-finger. The thickening involved the muscular and mucous coats in equal proportions. The internal mucous surface of the stomach was smooth and healthy. The peritoneal covering of the diaphragm presented a milk-white appearance, glistening and indurated to the feel, and uniformly thickened to the extent of half an inch. The omentum was shrivelled up, felt firm, had a mammellated appearance, and resembled a round cord, about half an inch in diameter, fringing the larger curvature of the stomach. The peritoneal covering of the intestines and of the mesentery appeared to be sprinkled over with a white granular or pulverulent substance, consisting apparently of chronic lymph, and so firmly attached that it could not be separated without removing the peritoneum with it. In some places the white indurated matter was aggregated together, presenting a uniform white surface, and giving to the serous membrane an unusual firm consistence. It was evidently the same lesion that affected the diaphragm. Many of the mesenteric glands were of white colour, slightly enlarged, and very indurated, presenting on section a uniform white fibrous structure.

*Microscopic Examination.*—On making a section of the thickened portion of stomach with Valentin's knife, it was seen to consist of a dense fibrous



structure. On the addition of acetic acid this became more transparent, and exhibited elongated nuclei very distinctly at different depths—(Fig. 57). No isolated cells were to be seen. The submucous tissue presented a similar structure, mingled with a few filaments of curled elastic fibres. The white substance on the diaphragm and mesentery was also composed of bundles of fibrous tissue, presenting the same appearance on the addition of acetic acid. These, however, were mixed with numerous fusiform corpuscles, and what appeared to be free nuclei, consisting of delicate oval bodies, varying in size from the 1-100th to the 1-80th of a millimetre in their long diameter, containing one granule—(Fig. 58). These bodies underwent no change on adding acetic acid—(Fig. 59). The mesenteric glands were composed of a similar fibrous stroma, containing also free oval bodies.

Fig. 57.



Fig. 58.

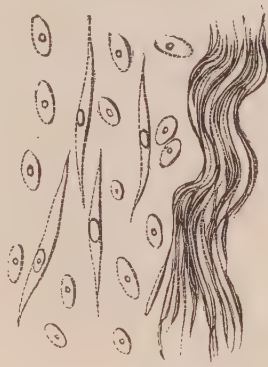

Fig. 59.



*Fig. 57. Fibrous structure constituting induration of stomach, described Obs. XXII., after the addition of acetic acid. Fig. 58. Oval bodies and fibrous structure from the thickened peritoneal coat. Fig. 59. The same after the addition of acetic acid.*

*Remarks.*—In this Observation we observe the same chronic lesion of the stomach as in the last case, associated with induration of the mesenteric glands, and partial thickening of the peritoneal coat. There are no cancer cells any where to be detected ; but in the last-named situations there are a number of transparent oval bodies, containing one granule, unaffected on the addition of acetic acid. They are evidently the same as those seen in the fibrous structure of the stomach in the last Observation. Are these oval bodies naked cancer nuclei, or are they, as previously stated, bodies connected with the fibrous tissue? This point can only be elucidated by further observations. In the mean time I may observe, that having seen them in many deposits undoubtedly not cancerous, as well as associated with perfect cancer cells, I am inclined to think that they cannot be regarded as necessarily connected with either.

The following case, for the particulars of which I am indebted to Dr John Scott, who asked me to examine the body, presents such a marked similarity to the one just described, that it may be well to give it before making further observations:—

## OBSERVATION XXIII.

CANCROID AND CHRONIC ULCER OF STOMACH—CONTRACTION AND THICKENING OF OMENTUM—ASCITES—DEATH.

“MY DEAR SIR,—The following is a brief notice of the case to which you alluded. Miss T., æt. forty, had been labouring for many years previous to my attendance under severe fits of asthma, with feverish attacks, considered as intermitting fever, which she imagined she had caught somewhere in England. During my attendance of about four years, the asthmatic attacks were never severe, but she laboured for months under feverish attacks, commencing with slight rigors, heated skin, and quick pulse, succeeded for a day or two by profuse fits of perspiration, which generally gave relief. At times she was tolerably well, and able to enjoy a certain degree of exercise. The appetite was pretty good, and animal food was found to agree best. With such attacks, however, her health and strength began to decline. The appetite became more variable, and food produced a feeling of weight and uneasiness in the stomach. About six months previous to her death, a small hard ridge-like tumour was discovered in the epigastrium. She now began to complain of severe pain in that region, and a severe inflammatory attack supervened, in which I did not see her. The tumour gradually increased in size. Food was always accompanied with great uneasiness, even in small quantities. The bowels were tolerably regular, and kept so by injections. There was occasionally vomiting at the commencement, but latterly the chief complaint was of severe fits of pain, which required large opiates for relief. Ascites now supervened, and she sunk, emaciated to the last degree.—I remain, yours very truly,  
J. SCOTT.”

*Sectio Cadaveris, September 6, 1847.*

*Head* not examined.

*Thoracic organs* healthy.

*Abdomen.*—The peritoneal cavity contained about five quarts of dark brown transparent serum. Stomach was much contracted, hard and indurated to the feel. On being opened, its coats were universally thickened to the extent of three-fourths of an inch. The muscular coat was hypertrophied, one line in thickness, of a grey gelatinous aspect; the submucous areolar tissue thickened and indurated, of white colour, and of dense fibrous structure. No stricture of pylorus. Mucous membrane corrugated, but healthy, except at the posterior part of the organ, where there was a round ulcer the size of a half-crown, with somewhat ragged edges, not elevated above the surface of the mucous

membrane. The base of the ulcer was formed by the peritoneal coat. The omentum was contracted, thickened, indurated, and resembled a roll of fibrous structure half an inch in diameter, fringing the larger curvature of the stomach. The transverse colon was contracted, and united by this roll closely to the stomach. The mesentery was thickened, and its peritoneal covering, as well as that over several coils of small intestine, studded with white glistening miliary deposits of fibrous character. Spleen atrophied, only two inches and a half long. Other organs healthy.

*Microscopic Examination.*—On making a thin section of the thickened walls of the stomach with a double-bladed knife, it was seen to be composed of a dense fibrous structure. The thickened muscular coat presented the appearance represented (Fig. 60). The thickened submucous tissue was formed of filaments running close together, constituting a fibrous texture, which was with difficulty separated by means of needles. Here and there, mingled with these filaments, were round and oval transparent corpuscles, larger than those in the last Observation, varying in their longest diameter from the 1-80th to the 1-50th of a millimetre. They contained a round granule, about the 1-300th of a millimetre in diameter, and underwent little alteration on the addition of acetic acid. This however, rendered the fibrous structure more transparent, and oval and elongated nuclei very apparent—(Fig. 61). The structure of the white deposits on the peritoneum, and of the thickened omentum, was identical with that observed in the last Observation.




Fig. 60. Fibrous structure with oval bodies in the coats of the stomach, described Obs. XXIII.  
Fig. 61. The same after the addition of acetic acid.

*Remarks.*—The only difference between the alterations found in the stomach in this and the last Observation, was the occurrence of a chronic ulcer. In all other respects, the symptoms, morbid anatomy, and minute structure, were nearly the same. The following case presented an extraordinary specimen of this peculiar alteration of the stomach :—

## OBSERVATION XXIV.

CANCROID OF STOMACH—BRONCHITIS—CRETACEOUS CONCRETIONS IN THE LUNGS—  
DEATH.

ROBERT BROWN, æt. fifty-two, admitted into the Royal Infirmary under Dr Alison, October 10, 1845. He states, that five or six weeks ago he was seized with pain in the region of the stomach, accompanied with distension of that organ, which came on about mid-day before eating, and continued until night. There was also vomiting, with thirst and anorexia. The pain was relieved by eating, but was shortly followed by nausea. Upon examination there is perceived a tympanitic swelling in the region of the stomach, and a dense unyielding tumour in the right hypocondrium, which the patient states to have been perceptible for the last three weeks, and to have varied in magnitude. *November 1.*—The vomiting has continued up to this date, and emaciation has made rapid progress. Died during the night.

*Sectio Cadaveris, November 2, 1845.*—Body much emaciated. The abdominal walls depressed, firm and unyielding to the touch.

*Chest.*—The pleuræ were adherent at the apices of the lungs only, which were deeply puckered in this situation, and contained several cretaceous and calcareous concretions, varying in size from a pin's head to that of a pea. The inferior lobes of both lungs when incised were red and engorged, yielding from the cut surface on pressure frothy mucus from some of the small bronchi, and a purulent fluid from others. One of the bronchial glands was adherent to the right bronchus, the size of a pigeon's egg, and infiltrated with a substance like dry putty, friable and cretaceous. This matter was enveloped by a fibrous cyst, which separated readily from its contents. The cyst was lined internally by black pigment, presenting a marked resemblance to the pigmentum nigrum of the eye. *Heart* healthy.

*Abdomen.*—Upon reflecting the parietes, the stomach presented a perfectly white lardaceous appearance, but was exceedingly firm and dense to the feel. Its form and size resembled the organ when in a state of contraction. On opening the stomach, its walls were seen to be thickened to the extent of an inch, and this throughout its whole extent, with the exception of a space the size of a five-shilling piece, surrounding the pylorus, which was quite healthy. The interior surface of the organ was traversed by several grooves or channels, dividing the hypertrophied structure into clefts, at the base of which the walls of the organ were of normal thickness. These grooves divided the internal hypertrophied structure of the stomach into masses, varying in size from three to five square inches. The hypertrophied structure occupied the space between the peritoneal and mucous coats. It was of a glistening white colour, of semi-cartilaginous or tendinous consistence and density, grating under the knife. No trace of the muscular coat could be observed. The mucous membrane was of a light brown colour in some portions, and of an ash grey, approaching to black, in others. In a few places its surface was raised, so as to

form papillæ or granulations the size of peas; in other places it was ragged, depressed, and irregular. No ulcerations existed any where. Other organs healthy.

*Microscopic Examination.*—On examining a thin section of the thickened coats of stomach, it was seen to consist of a dense fibrous structure, which, on being slightly teased out with needles, was found to consist of an immense number of fusiform corpuscles aggregated together. On scraping the tissue with a knife, there was removed a pulpy substance, which in some places was found to contain, in addition to the fusiform corpuscles, a number of round or oval cells, varying in size from the 1-100th to the 1-50th of a millimetre in their longest diameter—(Fig. 62). Every degree of gradation might be observed between the oval form of these cells and the fusiform corpuscles. They all possessed a small nucleus, generally about the 1-300th of a millimetre in diameter. No nucleolus could be observed. On the addition of acetic acid, the whole corpuscle was rendered somewhat paler, whilst the nucleus was unchanged. The mucous surface of the stomach was covered with irregularly formed and partly broken down epithelial cells.

Fig. 62.

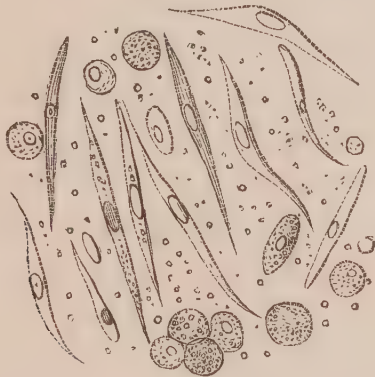


Fig. 62. Structures seen in the pulpy matter scraped from the coats of stomach, described Obs. XXIV.

*Remarks.*—In this Observation the thickening of the stomach had proceeded to an extent which I have never seen equalled, and presented characters quite peculiar. The absence of pyloric stricture and ulceration, the obliteration of the muscular coat, and formation of fibrous tissue in the walls of the organ an inch thick, and the want of cancer cells, are sufficient to raise doubts as to this alteration being strictly cancerous. Two views may be taken of the nature of this lesion: 1st, That it is a chronic cancer; 2dly, That it is a fibrous growth, resembling a simple stricture of hollow viscera.

1. It may be argued in favour of the first view, that in Observation XXI. it was evidently associated with undoubted cancerous disease of the mesenteric glands, and that in all cases of scirrhus the

growth is essentially fibrous. The round and oval bodies mingled with the fibres, it may be contended, are nuclei, identical in appearance and structure with the nuclei of cancer cells, and that there are many growths generally considered malignant which only possess these bodies.

2. On the other hand, and in favour of the second view, it may be urged, that in structure this alteration resembled in every respect a simple fibrous growth; that if in some cases it be associated with undoubted cancer in other organs, cases also occur where it constitutes the only lesion; that the round and oval bodies are found in many structures which cannot be considered cancerous, for instance, certain exudations round corpora lutea in the ovary, and in soft polypi from the nose; that these latter are more characteristic of fibrous than of other forms of growth; and, finally, it may fairly be questioned whether those tumours which only contain these bodies are really cancerous.

At the same time it cannot be denied, that the lesion of which we are now speaking has always been considered as scirrhus, and as in its nature malignant. But the idea of simple stricture of the stomach, and hypertrophy of its walls, has not been thought of. When, however, we consider the numerous cases on record of so-called cancer, which have been known to arise from swallowing irritating substances, more especially acrid poisons, we can easily imagine that the effect of such may be to produce simple inflammation and thickening, the same as occurs in the intestines, urethra, and other hollow viscera. This is certainly the view I am inclined to take of this disease,—a view which becomes strengthened on inquiring into the appearances and progress of undoubted cancer of the stomach, as in the Observations which follow.

#### OBSERVATION XXV.

CANCER OF STOMACH, INTESTINES, AND LYMPHATIC GLANDS—DOUBLE PLEURISY—PERITONITIS—DEATH.

ANDREW M'CASH, *æt.* twenty-four, admitted into the Royal Infirmary, December 6, 1844, under Dr Craigie. Six weeks ago he first observed pain in the region of the kidneys, which darted round the abdomen, and was felt at intervals. There was also dysuria and hematuria. About three weeks subsequently the abdomen began to swell, and the legs became œdematous. On admission he still has pain on passing urine, and the abdomen and legs are considerably

swollen. There is also a dull pain in the lumbar region, in the neighbourhood of the kidneys, and acute pain in the side. The chest on the right side is dull on percussion, and there is great dulness in the umbilical region. The abdomen is painful on pressure, and tense, without distinct fluctuation, except below the umbilicus. A firm body is felt in the left hypocondriac region, extending three inches from the umbilicus laterally, and two upwards. When he turns to the right side, the tumour also passes over to the right side, leaving that portion of the abdomen free from pain on pressure. The tumour itself, wherever situated, is the seat of exquisite pain when pressed. There is no vomiting.—*December 26.* During the last four days he has complained of pain in both sides of the chest, and there has been considerable dyspnoea. On percussion there is dulness all over the right side of chest, and considerable dulness on left side inferiorly. The respiratory murmurs are only heard in the inferior portions of chest, but more distinctly on the left side. Here also numerous sonorous rhonchi are distinguishable. Died on the morning of the 27th.

*Sectio Cadaveris, December 29, 1844.*

*Head* not examined.

*Chest.*—Both pleural cavities contained a quantity of opaque, yellow, flocculent fluid, of which half a gallon was removed from the right, and a quart from the left side. The right lung, collapsed and pressed against the vertebral column, was scarcely one-fourth its usual volume, and weighed only 8 oz. The pleuræ were covered with flakes of recently effused lymph. The left lung was not so much compressed as the other; it weighed 10 oz. 5 dr. The pleuræ were strongly adherent about the centre by firm adhesions, and covered with flakes of lymph here and there, as on the other side, but not so numerous. The tissue of the lungs, though dense, was healthy. The heart was not larger than a turkey's egg, but in structure healthy.

*Abdomen.*—The peritoneal cavity contained about three pints of a turbid, yellowish fluid. The peritoneal surfaces, and especially the omentum, covered with flakes of recent lymph, very soft, and scarcely adherent.

The gall-bladder, stomach, pancreas, duodenum, and transverse arch of the colon, were united together, 1st, by adhesions of firm lymph between their serous surfaces; and 2dly, by numerous deposits of white cancerous matter into and between the pancreas, lymphatic glands, and coats of the intestine. The neck of the gall-bladder was surrounded by a cancerous mass the size of an orange, apparently obstructing the flow of bile, which had accumulated in the gall-bladder, and was very thick and dark in colour. On opening the stomach it was found filled with a bright green pultaceous fluid, in which were masses of a resinous character and fracture, varying in size, but some as large as a walnut, and of a bright green colour. The pyloric orifice was slightly constricted, from the deposit of cancerous material in its walls; the coats of the duodenum, thickened throughout from a like cause, being, an inch beyond the duodenum, half an inch thick. Where the jejunum commences, the constriction of the gut was so great that the little finger could with difficulty be passed through it. The carcinomatous matter in this portion of the tube, as well as

in the walls of the stomach, was of a dead white colour, and deposited between the mucous and serous coats, the muscular coat having apparently disappeared. On squeezing a cut surface it yielded a copious milky juice. About two feet from the stricture just mentioned, there was a patch of carcinomatous matter in the jejunum, about the size of half-a-crown. The intervening portion of gut, and from this to its termination, were quite healthy.

All the mesenteric and lumbar glands were enlarged, of white colour, more or less lobulated, and infiltrated throughout with white, soft, cancerous matter. In the centre of the mesentery there was a mass of a flattened shape and irregular surface, about four inches broad, united above to the pancreas and the mass formerly spoken of, below to several coats of intestines, and laterally to several enlarged mesenteric glands. On dividing this mass, or any of the enlarged glands, the section presented a smooth white surface, of soft consistence, from which there exuded on pressure a copious thick creamy fluid.

Other organs healthy.

*Microscopic Examination.*—The juice squeezed from the cancerous deposits in the coats of the intestine, or in the mesenteric glands, contained a multitude of somewhat oval corpuscles, the edges of which, however, were by no means regular. In their longest diameter they measured about the 1-100th of a millimetre in diameter. Some contained two, and others three or four granules. These bodies were evidently nuclei of cancer cells, for, on carefully arranging the light, a faint cell-wall could be distinguished round some of them.—(Fig. *a*.) Acetic acid at once dissolved all traces of the external cell-wall, and caused the margin of the nuclei to become thickened and more distinct. The same structures were observed in the soft cancerous matter, wherever it occurred, the appearance of which was very uniform in the pylorus, intestine, and glands. The fibrous matrix was soft and loose, presenting nothing worthy of notice.

Fig. 63.

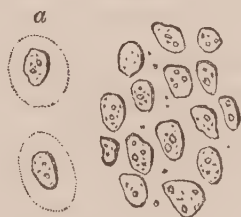

Fig. 63.—Nuclei and delicate cancer cells (*a*) squeezed from pylorus, described Obs. XXV.

*Remarks.*—The cancerous exudation in the walls of the stomach and intestines, presented a very different appearance from that observed in the former Observations. Instead of being hard and fibrous, it was soft, of a dead white colour, and yielded on pressure a copious milky juice. The presence of cancer cells in immense numbers, also, strongly contrasts with the appearances observed in the preceding cases.



## OBSERVATION XXVI.

CANCEROUS ULCER OF STOMACH—CANCER OF EPIGASTRIC AND MESENTERIC GLANDS  
—CANCER OF PLEURA, DIAPHRAGM, PERITONEUM, LIVER, AND UTERUS—PERI-  
TONITIS—DEATH.

JANET WOOD, æt. forty, married, admitted into the Royal Infirmary, October 4, 1847, under Dr Douglas. She laboured under abdominal dropsy, which had existed two months. For four months she has suffered from pain in the right shoulder and side. There has been pain in the lower part of the abdomen for five weeks. No jaundice. Has been confined to bed for three weeks. On admission the abdomen is considerably swollen, measuring in circumference thirty-one inches, and communicates to the feel a distinct sense of fluctuation. There is pain in the right shoulder, side, and region of the liver, which is not acute. The dulness of the hepatic region extends as high as the mamma, and downwards half an inch below the ribs.—*October 8.* There is pain in the hypogastrium, and tenderness in the region of the liver.—*October 12.* Abdomen is increased in size, now measures thirty-five inches in circumference—urine copious.—*November 4.* Has had her gums affected by calomel, which has now ceased. At present frequent purging, motions scanty without pain. There is sickness, depression, and marked anxiety of expression. Pulse 116, small. Considerable bearing down pain in the lower part of the abdomen.—*November 5.* Suddenly sunk, and died a little after midnight.

*Sectio Cadaveris, November 6, 1847.*

*Chest.*—The right lung was considerably engorged, yielding on section, especially superiorly, a copious frothy fluid. The pleuræ presented several crimson red tumours, varying in size from a millet seed to that of a large pea, of firm consistence; on section presenting a greyish colour, and yielding on pressure a greyish-coloured fluid. The diaphragm on the right side was adherent to the seventh true rib anteriorly, by a similar reddish mass the size of a walnut. The left lung and heart were healthy.

*Abdomen.*—The peritoneal cavity contained about two gallons of fluid, clear on the surface, but turbid from flakes of lymph and pus inferiorly. The coils of intestine were loosely adherent to each other by bands and masses of recently exuded lymph. The diaphragm towards the right side was about three quarters of an inch thick from cancerous deposition between the serous and muscular coats, and closely adherent to the liver and stomach. These organs, with several lymphatic glands, were firmly united together, and were removed *en masse* for the purpose of examination. On opening the stomach a round ulcer was discovered in its posterior wall, the size of a five-shilling piece, which had completely perforated the organ. Internally its edges, slightly raised above the mucous membrane, were soft, sloughing, and readily broke down under the fingers. Externally and posteriorly the edges were adherent to the pancreas, which constituted the base of the ulcer, except at one point, where a free com-

munication existed between the interior of the stomach and the cavity of the peritoneum. The liver was of a pale fawn colour, presenting here and there on its surface rounded dirty white spots, which on section were seen to dip from the one-sixteenth to the one-fourth of an inch into its substance. They were of firm consistence, but yielded a lactescent fluid on pressure. The epigastric glands were considerably enlarged from infiltrated cancerous deposition, and united to the stomach and liver. The mesenteric and lumbar glands were similarly affected, but to a less extent. The glands of the meso-colon and the appendicæ epiploicæ were all the seat of cancerous infiltration, and presented tumours varying in size from a pea to a hazel-nut; some of these were of a purple colour from extravasation of blood. The peritoneum was in several places indurated and thickened from the deposition of cancerous matter, in flattened round oval white plates, varying in size from a pea to that of a shilling or half-a-crown, and in thickness from a line to a quarter of an inch. Several of these were of a pink or red colour at their circumference, owing to increased vascularity. The uterus was considerably enlarged and elevated above the brim of the pelvis. The fundus of the organ was the seat of cancerous exudation, presenting on section a hard fibrous structure (scirrhus) an inch in thickness, not yielding any juice on pressure. The cervix and os uteri were healthy.

*Microscopic Examination.*—The surface of the ulcer in the stomach was composed of numerous cells irregular in form, and more or less broken down. Some contained a distinct nucleus with two nucleoli; others nothing but granules—(Fig. 64). These were mingled with several smaller bodies, apparently the debris of the corpuscles just noticed, and a large number of molecules and granules. On cutting into the base of the ulcer, and examining some of the squeezed out fluid, it was seen to contain more perfect cancer cells. These were distinguished by their oval or rounded form, varying in their longest diameter from 1-50th to the 1-75th of a millimetre in diameter, and presented the usual change on the addition of acetic acid. They contained one or two nuclei, and these one or two nucleoli—(Fig. 65). Floating among these cells were several granules and molecules, large loose drops of oil, and fusiform corpuscles. The epigastric glands and crimson red tumours on the pleura, yielded on section a copious greyish fluid, which contained several cancer cells and fusiform corpuscles, similar to those just described, together with others imbedded in finely molecular matter, resembling those represented (Fig. 50). The same elementary structures were observed in the mesenteric glands, and other cancerous exudations on the peritoneum.

The fundus of the uterus was very carefully examined. On making a thin section of it with a double-bladed knife, it was seen for the most part to be composed of a fibrous stroma, containing loculi, varying greatly in size, more or less filled with delicate transparent cells. These were oval or round in form, and varying in their longest diameter from 1-50th to 1-30th of a millimetre. Examined *in situ* a nucleus was only seen in a few; but those which had escaped from the fibrous structure, and floated round the margin of the section,

were observed to contain well-formed oval nuclei, with two nucleoli—(Fig. 66). There were also mingled with several of these, naked nuclei and fusi-form corpuscles. On the addition of acetic acid to a section, the arrangement of the fibrous stroma was well exhibited; and the spindle-shaped, elongated nuclei it contained, was strongly contrasted with the oval nuclei belonging to the cancer cells, the walls of which were entirely dissolved—(Fig. 67).

Fig. 64.

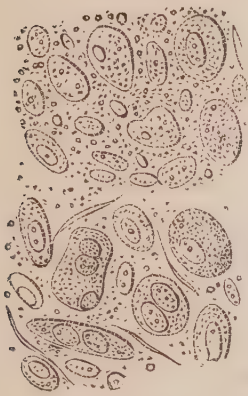


Fig. 67.

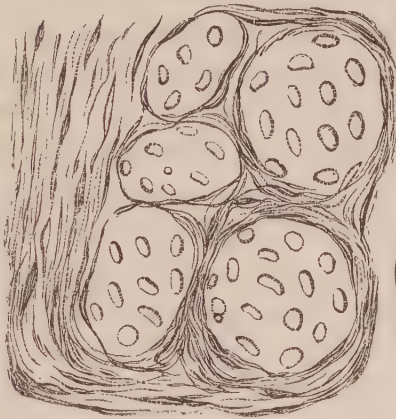

Fig. 66.

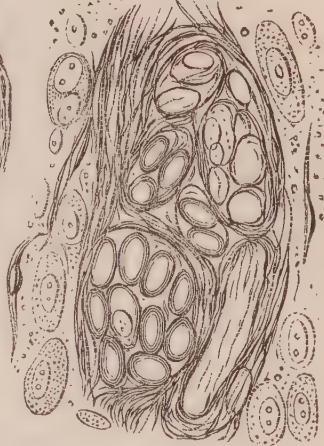

Fig. 65.

Fig. 64. Corpuscles from the surface of the ulcer in the stomach, described Obs. XXVI. Fig. 65. Corpuscles in the fluid squeezed from the base of the same ulcer. Fig. 66. Appearance of a thin section of the fundus of the uterus in the same case. Fig. 67. Another section after the addition of acetic acid.

*Remarks.*—The peculiarities in this case were—1st, the cancerous masses on the serous membranes, especially of the pleura and peritoneum; in the former, in the form of rounded crimson tubercles, in the latter, of white, flat plates. 2d, The ulcer in the stomach decidedly cancerous, with raised thickened edges, composed externally of broken down cancer cells and epithelium; and internally of more perfect cancer cells, infiltrated in a fibrous stroma, and imbedded in a molecular exudation. 3d, An incipient stage of cancer of the fundus uteri, showing that the cancerous exudation, transformed into cells, accumulates between the fibrous meshes of the organ, forming loculi. This specimen, when connected with the Observations formerly recorded, completes the history of uterine cancer.—(Obs. XII. XIII. XIV. XV.)

## OBSERVATION XXVII.

CANCER OF THE STOMACH, DUODENUM, LIVER, PANCREAS, AND LUMBAR GLANDS—  
DEATH.

JAMES WILKES, æt. fifty-eight, a porter, admitted into the Royal Infirmary, March 24, 1848, under the care of Dr Douglas. About five weeks ago, after having suf-

ferred from distressing cough with prostration of strength, was seized with severe pain in the upper part of the abdomen. He soon afterwards observed a swelling in the right hypocondrium, which has increased considerably since, and has appeared to him to become lower in the abdomen. The swelling has been constantly attended by dull gnawing pain, which is always severe, but sometimes worse than at others. The appetite has fallen off considerably, but he can always eat a little with some relish. There is considerable emaciation. Cough is now trifling. Bowels have been generally costive. *March 27.*—General state continues as at time of admission. Sleep is disturbed by paroxysms of pain. Urine reported abundant. Lower part of belly tumid and tympanitic, but free from tenderness. The tumour, tender and resisting, occupies apparently the right hypocondrium and umbilical region at its upper part, not extending to the right lateral region, where there is an imperfectly tympanitic percussion. In the left hypocondrium (and umbilical region) there is also dulness on percussion, with less tenderness than on the right. Tongue slightly grey. Pulse 70. He has not been subject to vomiting, but suffers from increased pain immediately after taking food, which continues from one to three or four hours. Experiences greater pain after taking broth. *April 1.*—Vomited last night a large quantity of watery matter, mixed with frothy mucus. *April 5.*—For the last two days, after continued uneasiness in the region of the stomach, with sickness, has vomited a large quantity of mingled, watery, and semi-digested matters. There has been considerable sweating. Urine 11 oz., still turbid. No ammoniacal odour, with sediment of lithates. No albumen. *April 10.*—Decided salivation has occurred, and he has vomited, within the last four days, once a-day. Tenderness of tumour less. Still suffers much from pain after taking food. *April 17.*—Tumour more prominent, isolated, and lower in the abdomen than on first report. He sweats considerably. He gradually sunk, became very emaciated, and died May 10, 1848.

*Sectio Cadaveris, twenty-four hours after death.*—Body pale, greatly emaciated. *Head*—Not examined.

*Thorax.*—Pericardium contained about  $\zeta$ ijj of pretty clear yellow serum. Heart healthy. Both lungs were very emphysematous, otherwise healthy.

*Abdomen.*—On reflecting the parietes, the stomach was found much distended, and pushed forwards at its pyloric extremity. The duodenum externally was much enlarged, and very dense to the touch. The transverse colon was strongly adherent to the pyloric extremity of the stomach. On removing these organs entire, a large lobulated tumour was observed closely applied to the spine, and involving the posterior surface of the duodenum, shortly after leaving the pylorus, and also the right extremity of the pancreas. It was about the size of two fists, nodulated, several of the tubera being as large as ducks' eggs. It was also found to descend along the spine on the left side—attaining there a considerable magnitude, and involving the lumbar glands. On section, the tumour was found of a yellowish white colour, distinctly lobulated and pretty tough, but on pressure yielding considerable quantities of white, curdy matter.

The stomach, on being cut open, was for the most part seen to be healthy. Towards the pylorus, however, the mucous membrane presented about half a dozen white, round elevations, the largest the size of a split pea. The duodenum was distended to twice its natural dimensions, and exhibited on its internal surface, extending four inches in length, a mass of prominent fungous ulceration of a greenish brown colour. The walls of the gut at this point were nearly an inch in thickness, externally of a hard white fibrous appearance, but internally soft and pulpy. Beyond this the gut resumed its natural dimensions and colour; but for the distance of about half an inch the mucous membrane was elevated by numerous hardened white nodules, situated in the submucous areolar tissue. The other intestines healthy. The liver was normal in size, but very dense to the touch; and its surface, which was of a dark brownish hue, was slightly elevated in various points by dense, round, whitish masses, generally having a distinct margin, and varying in size from a pea to that of a five-shilling piece. In some places they had joined together, and formed irregular masses. On section its substance was very firm, and was of a brownish hue, with numerous cancerous masses of a light grey colour scattered through it, varying much in size, the larger of them being much injected, of a reddish hue. They were dense to the touch, cutting like cartilage under the knife. The right extremity of the pancreas was involved in the tumour, to which also its upper surface, for the space of an inch and a half, was attached. On its inferior surface was situated a small white tumour, not very distinctly limited, and of the size of a common bean. The spleen was normal in size, but soft and pulpy, and of a dark colour. The kidneys were very dense to the touch, and well injected; their size was below the average, but on section their structure seemed healthy. Other organs healthy.

*Microscopic Examination.*—On making a section through one of the small white nodules, near the pyloric extremity of the stomach, with a Valentin's knife, the appearance was presented given (Fig. 68).

Fig. 68.

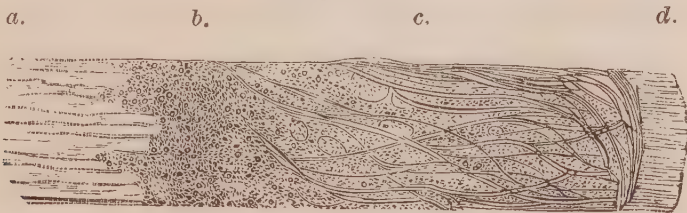

Fig. 68. Section of a small cancerous nodule, size of a split pea, from stomach; (a) muscular coat; (b) fine molecular matter, in which a few nuclei and corpuscles are obscurely visible; (c) fibrous tissue, in the meshes of which molecular matter is infiltrated; (d) epithelium.

A finely molecular and granular exudation was poured out between the muscular and mucous coats, and infiltrated into the areolar tissue below the latter. A few rounded and oval bodies (probably incipient cancer cells) were obscurely visible among them. On examining the milky juice which flowed from an incision into the fungous projections in the duodenum, numerous cancer cells in their highest stage of development were observed. They varied in size from

the 1-50th to the 1-10th of a millimetre in diameter. They were generally round or oval in shape, the smaller containing one or two round or oval nuclei, the larger from two to five. There were very generally two granular nucleoli in the nuclei; but, here and there, these were in turn developed into oval bodies, varying from the 1-50th to the 1-80th of a millimetre in diameter. In some of the larger cells the nucleus could be seen in the cell-wall, while the cell itself was distended with fluid. Several compound granular corpuscles, and numerous molecules and granules, were associated with the cancer cells. On the addition of acetic acid the external cell-wall became more transparent, whilst the included nuclei and cells were rendered more distinct.

The mesenteric glands contained similar cancer cells to those just described. In the liver and pancreas, however, the cancer cells resembled those in Figs. 42 and 43.

Fig. 69.

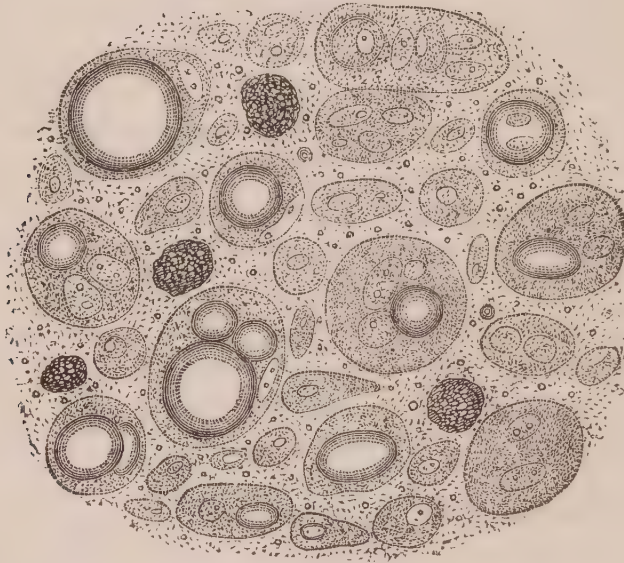


Fig. 69. Simple and compound cancer cells from the cancerous duodenum, described Obs. XXVII.

*Remarks.*—In this Observation the duodenum was the part of the alimentary canal principally affected, and the cancerous exudation had here ulcerated through the mucous coat, and produced large fungous excrescences on the internal surface of the gut. In the stomach the disease was in an incipient stage, and enabled me to see that it commenced in a firmly molecular and granular exudation between the muscular and mucous coats, in which cells become developed. As the disease progresses, the mucous coat gives way, and then no check existing to the further development of cell growth, it proceeds with the utmost activity, forming large fungus-like projections. The juice squeezed from these in the duodenum presented very characteristic compound, or mother cancer cells, exhibiting several nuclei and cells enclosed in an envelope, or the original cell-

wall. These cells were very different from those described (Obs. XIX., Fig. 50); for, on adding water, they could be seen to turn round with their included structure, the external envelope remaining distinct and entire. In some of these cells one of the nuclei had become greatly enlarged, apparently from the absorption of fluid, and presented all the appearances of a transparent vesicle.

## OBSERVATION XXVIII.

CANCER OF DUODENUM—JAUNDICE—PERICARDITIS—CRETACEOUS CONCRETIONS IN THE LUNGS—DEATH.

MARY GALLOWAY, æt. forty-five, admitted April 17, 1845, into the Royal Infirmary, under Dr Craigie. States that she had jaundice in September and October last, from which she recovered, and resumed her occupation as a servant, till three weeks ago, when the skin again became yellow. She has never had pain in the right hypocondrium, but pressure either there or in the epigastrium cannot be borne. The urine is dark brown in colour, and the stools white. No abdominal swelling or fluctuation.—*April 21*, Jaundice diminishing. There is no pain, sickness, or vomiting.—*April 22*, She had a severe rigor last night, followed by fever and sweating. At present the pulse is 100, full, tongue furred, skin hot, thirst.—*April 30*, The rigors have not returned, fever continues. Total loss of appetite. A blister applied to epigastrium discharges copiously. Great thirst.—*May 2*, Febrile symptoms unabated. Strength greatly diminished. Died in the evening.

*Sectio Cadaveris, May 4, 1845.*—Integuments and tissues throughout of a yellow colour.

*Head*—Not examined.

*Chest.*—Slight adhesion of the pleuræ at the apex of left cavity. Both lungs at the apex deeply puckered, containing numerous calcareous and cretaceous concretions in the parenchyma. Posteriorly the lungs engorged, and œdematous, yielding on section a copious yellow frothy fluid. The cavity of the pericardium contained half an ounce of dirty yellow, turbid fluid. The serous membrane itself presented its usual white glistening character. Heart healthy.

*Abdomen.*—Liver of natural size and structure, but tinged of a deep green colour. The gall bladder was greatly distended with fluid bile of a grass green colour. The hepatic and common ducts were much increased in calibre. The mucous surface of the duodenum at the entrance of the ductus communis presented a round opening, an inch and a half in diameter, caused by ulceration, with raised thickened edges formed of cancerous matter. It constituted a tumour half an inch in thickness, projecting into the gut, ulcerated in its centre, and so pressing upon the termination of the common duct as completely to obstruct it. On section it presented a smooth white surface, and yielded on pressure a copious milky juice. Other organs healthy.

*Microscopic Examination.*—The fluid squeezed from the cancerous tumour contained numerous cancer cells, which varied greatly in shape and size. Some were round or oval, others elongated, approaching the caudate form, and a few more or less oblong. They were all nucleated; some containing one, others two, and a few three nuclei. One of these last is represented in the figure. The nuclei were round or oval. Some contained nothing but molecules, others one or two distinct nucleoli. In size, these cells varied from the 1-80th to the 1-12th of a millimetre in their longest diameter, the generality of them being of large size—(Fig. 70). On the addition of acetic acid, the cell-wall was rendered very transparent, whilst the nuclei appeared unusually dark and contracted—(Fig. 71). The fibrous tissue in which they were imbedded was loose, and the filaments widely separated.

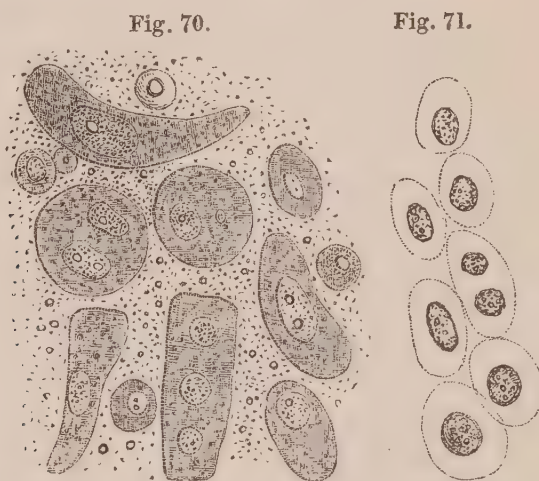


Fig. 70. Cancer cells from cancerous tumour in the duodenum, described Obs. XXVIII. Fig. 71. The same after the addition of acetic acid.

*Remarks.*—In this as in the last Observation, the cancerous exudation in the duodenum had proceeded to ulceration; and the juice squeezed from the parts contained highly developed cancer cells, with from one to three large nuclei. In this case, jaundice resulted, which was not observed in the last Observation.

## OBSERVATION XXIX.

CANCER OF THE RECTUM AND OF THE PROSTATE—PERFORATION OF INTESTINE—  
PERITONITIS—DEATH.

MR N——, æt. seventy, a gentleman of literary habits, had for many years suffered from irritation of the rectum and urethra, and had undergone several operations for fistula in ano. For many years he had passed little water except by means of a flexible catheter, which he passed himself. About two years before his death, he applied to Mr Syme, labouring under symptoms of



urinary irritation. It was then discovered that a small hard swelling existed at the verge of the anus, in the situation of the former incision for fistula, which was considered malignant, and therefore left undisturbed. It gradually increased, extending up and round the anus, accompanied by a glandular swelling in the groin. The treatment pursued was entirely of a soothing kind, consisting of opiate injections, hip baths, gentle laxatives, and a restricted diet. Though unable for a full amount of exertion, he continued to be engaged in literary pursuits as formerly, until two or three days before his death, when he was found in a confused state, unable to explain his feelings, but apparently suffering great distress. His strength gradually failed, and he died under the symptoms of intestinal perforation, which was supposed to be the cause of death.

*Sectio Cadaveris.*—On the following day it was ascertained by dissection, that a cancerous stricture, in some places half an inch in thickness, and about an inch broad, extended round the lower portion of the anus. On being cut into, it presented a white, glistening, fibrous structure, crunching under the knife, and not yielding a milky juice on pressure. Immediately above the stricture, an ulceration the size of a pea had perforated the rectum anteriorly, causing the peritonitis, which had proved fatal. The middle lobe of the prostate was the size of a walnut, projecting into the bladder. On section, it presented a uniform white appearance, and yielded on pressure a copious milky fluid.

*Microscopic Examination.*—On making a thin section of the scirrhus intestine, it presented a fibrous structure running in waved parallel lines, intermixed with large well developed curled filaments of yellow elastic tissue—(Fig. 72). It was infiltrated throughout with numerous cancer cells, which were best seen by scraping a fresh cut surface. They were round, oval, caudate, or club shaped, varying in size, and furnished with one or more round or oval nuclei, also varying in size—(Fig. 73). They were mingled with numerous molecules and granules, and presented the usual reaction on the addition of acetic acid—(Fig. 74). The same cells, but in greater abundance, were contained in the milky juice squeezed from the cancerous prostate.

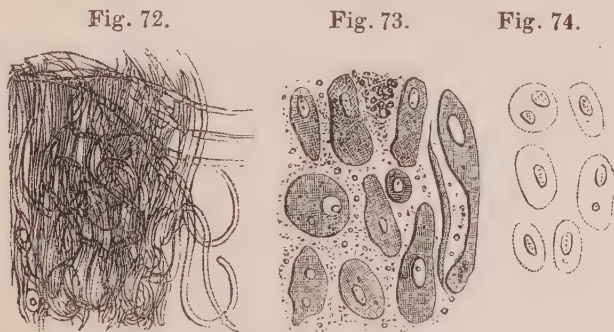


Fig. 72. Dense fibrous and elastic tissue, in which cancer cells are infiltrated from cancer of rectum, described Obs. XXIX. Fig. 73. Cancer cells scraped from the surface, in the same case. Fig. 74. The same after the addition of acetic acid.

*Remarks.*—In this case, although the indurated stricture of the gut resembled, to the naked eye, the cancrroid induration of the stomach described Obs. XXI. to XXV. the presence of well formed cancer cells infiltrated among the fibrous elements, evinced its real character. This is the only specimen of cancer of the rectum I have had an opportunity of examining; but there is every reason to believe that this portion of the gut is subject to the same chronic cancrroid disease as affects the stomach.

## OBSERVATION XXX.

CANCEROUS MASSES ON DIAPHRAGM—CANCEROUS TUMOUR IN ABDOMEN—ANEURISM OF AORTA—DISEASE OF AORTIC VALVES—CICATRICES WITH CRETACEOUS MASSES IN APICES OF BOTH LUNGS—ASCITES—DEATH.

WM. FINNIE, æt. forty, a soldier, admitted into the Royal Infirmary, April 6, 1848, under Dr Paterson. He has been in the army for twenty-two years, from which he was discharged in August last. He has served for three years in the West Indies, and for the remaining years in various stations in the Mediterranean. With the exception of an attack of cholera at Malta in 1833, he enjoyed good health while in the army, though his habits there were rather intemperate. About eight months before leaving the army, he began to be affected with pains in the shoulder. He continued well till December last, when he was seized with cough, not causing pain, but accompanied with dyspnœa. On the morning of the 4th of March, after a night's severe coughing, he first noticed a considerable swelling in the lower part of the abdomen, which was firm, but not painful, to the touch. Since then it has increased in size. His urine, which was previously passed freely and in natural quantity, now became scanty, and was voided with difficulty. Soon afterwards his right leg and foot became somewhat swollen. The left was unaffected. For some time back he has suffered from dyspeptic symptoms, with occasional pain in the epigastrium, frequently aggravated by taking food. Has vomited his food occasionally, but not at regular intervals. Frequently has pyrosis in the mornings.

On admission the countenance is pale and sallow. Suffers a good deal of cough, not causing pain in chest, but accompanied with dyspnœa, which is increased by lying on his back or right side. Expectoration frothy, somewhat tenacious. Has some pain in the right side of neck and shoulder, somewhat increased on coughing; as also a dull heavy pain in the lower part of the abdomen, with a sense of stiffness; the pain is somewhat increased on pressure. On examination, the abdomen is somewhat distended. A large solid mass can be felt filling the whole of the pubic and right iliac regions, extending above the umbilicus, and presenting a distinct margin. It extends little to the left side, but the left iliac region is dull, although no hardness can be felt. There is fulness with fluctuation in the lower part of the abdomen. Heart's action moderate, impulse

almost imperceptible; seems to beat below the sixth rib. Cardiac dulness increased, reaching from left margin of sternum to outside of nipple. Sternum above the second intercostal space is dull on percussion. The dulness extends beyond the bone on both sides, so that its greatest width is three inches. The first sound at the base is very short, while the second is much prolonged, and converted into a loud blowing murmur, which is propagated up the aorta, but is heard loudest at the aortic valves. This sound appears to be communicated to apex, as there is a slight bruit there with the second sound. Pulse 108, regular; distinct in the left, but can scarcely be felt in the right wrist. Percussion of lung natural, except some dulness over lower right back. Sonorous and sibilant rales every where audible, with occasional coarse crepitation. Appetite very bad; has much thirst.—*April 18, Weaker.* This morning became affected with severe dyspnoea, accompanied with great exhaustion. Pulse weak. Skin cold. Wine and stimulants were given; but he died in half an hour, about 8 A.M.

*Sectio Cadaveris, —twenty-fours after death. —*Body pale, considerably emaciated.

*Head*—Not examined.

*Chest.*—On raising the sternum, a rough uneven mass was perceived applied against the posterior surface of the superior fourth of this bone, which at this place was carious, and excavated to the depth of three-fourths of its thickness, and to the size of a five-shilling piece. The tumour was an aneurism arising from the summit of the arch of the aorta, a minute description of which it is unnecessary to give in this place. The heart weighed about 14 oz. The left cavity was considerably dilated, but its walls maintained their normal thickness. The aortic valves were incompetent, opaque, thickened, and considerably contracted. Their free margins presented a very thick, almost cartilaginous cord, which increased in thickness towards their attachments. The aorta, as far as the commencement of its thoracic portion, was considerably dilated, and studded over internally with atheromatous deposits. The pericardium contained nearly  $\zeta$ ij of clear yellow serum. The left pleura contained about half a pint of yellowish serum. The lung itself was strongly adherent at its apex and diaphragmatic surface, and also at the lower part of the costal pleura. It was congested—frothy mucous flowed in small quantity from the cut section on pressure. The apex presented some well-marked cicatrices, on cutting into which several cretaceous masses were discovered of a white colour, very hard, and enclosed in a distinct cyst of a dark colour. A few similar masses were also found in the apex of the right lung, which was adherent at that point to the pleura; inferiorly the lung was congested. Right pleura otherwise healthy.

*Abdomen.*—On opening the abdomen nearly the whole of the small intestines, with the sigmoid flexure of the colon, were found involved in a mass of disease, which was traced into the pelvis, completely filling that cavity and enclosing all its viscera. It reached as high as the umbilicus, below which it presented a globular swelling the size of a large cocoa-nut. Superiorly, it

had a whitish colour, breaking down under slight pressure of the finger into a milky pulp. Inferiorly, the tumour was firmer to the touch, and was strongly adherent to the parietes of the pelvis. On section it was very soft, and had a spongy reticulated appearance, of a light reddish brown colour below, from which on pressure a pulpy mass was exuded. The stomach was healthy. The intestines (as many as were free of the tumour) were greatly distended with flatus, and externally presented a dull leaden colour. In one or two places, small cancerous masses of the size of garden peas were situated on the peritoneum covering the small intestines at their free margin. A great quantity of fatty tissue was accumulated along the spine, in which were found imbedded many enlarged glands, which on section contained a white pulpy substance. The liver was natural in size—its structure, otherwise healthy, was soft, and paler than usual. Its superior surface presented two or three rounded indentations, corresponding to several tumours on the abdominal surface of the diaphragm. These tumours, flattened transversely of the size of chestnuts, were of a dull white colour, of soft consistence, and yielded on pressure a milk-white pulpy matter. The spleen was about half the usual size. It was paler than natural, and its fibrous structure was unusually evident. The kidneys were natural in size, and externally healthy. On a cut section, the tubes, as they converged towards the pelvis, were of a dull white colour, resulting from some mineral deposit. The cortical substance seemed healthy.

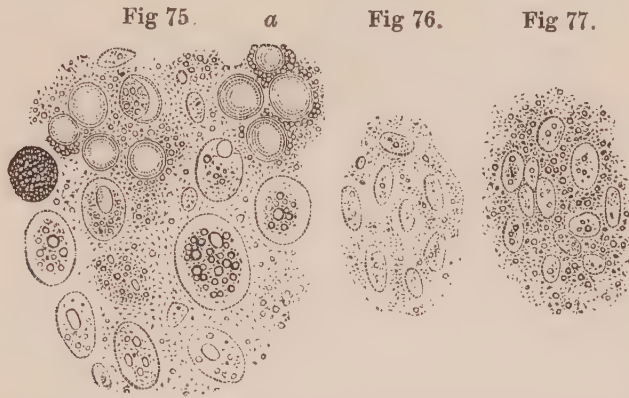
The abdominal aorta, cava, and iliacs were healthy. The prostate gland was found attached to the inferior part of the tumour, but was evidently not involved in the disease. It was very dense to the touch, and presented on section a white fibrous appearance. In the depending parts of the abdominal cavity were several pints of amber-coloured serum.

*Microscopic Examination.*—The juice squeezed from one of the cancerous nodules attached to the diaphragm contained numerous round and oval cells; varying in their longest diameter from the 1-50th to the 1-35th of a millimetre in length. They for the most part contained a round or oval nucleus, varying from the 1-100th to the 1-80th of a millimetre in diameter. Between the nucleus and cell-wall were several oily granules, and in some cells these entirely obscured the nucleus—(Fig. 75). On the addition of acetic acid the nuclei became very apparent, and the cell-walls were reduced to a molecular and granular matter—(Fig. 76). Mingled with the cells just noticed, were several naked nuclei, a few compound granular corpuscles, and a large number of perfectly round transparent vesicles, of great delicacy, to which a greater or less number of molecules and granules attached themselves externally—(Fig. 75, a).

The pulpy matter of the large tumour in the abdomen consisted entirely of nuclei, some of which contained several granules. They were imbedded in a quantity of molecular and granular matter—(Fig. 77).

The prostate gland consisted of dense fibrous tissue, entirely destitute of cells, but containing a large number of bright yellow mineral bodies, of a round or

oval form, having externally a number of concentric laminæ, and internally what seemed to be a distinct nucleus. A minute description of those peculiar concretions, as they are in no way connected with the subject of cancer, is in this place unnecessary.



*Fig. 75. Cells from cancerous mass on the diaphragm, described Obs. XXX. Fig. 76. The same after the addition of acetic acid. Fig. 77. Corpuscles from abdominal tumour in the same case.*

*Remarks.*—The abdominal cancerous tumour in this case probably originated in the lumbar glands, and proceeded downwards, involving the pelvic viscera, and all the soft parts in their neighbourhood. It is singular, notwithstanding the cancerous nodules on the lower parts of the diaphragm caused by their pressure deep depressions in the substance of the liver, that this organ should have escaped, and that even no adhesions should have been formed.

In Fig. 75 is well exhibited the manner in which cancer cells sometimes undergo the fatty degeneration, and ultimately break down to form the reticulum. The process is exhibited in a more advanced stage in Fig. 38. The transparent vesicles seen (Fig. 75, *a*), are common to many morbid products. Their exact mode of formation I have not been able to trace, although they are very probably formed of a thin albuminous layer, surrounding some oleaginous matter. Although only naked nuclei were observed in the abdominal tumour, there can be little doubt that this was owing to the disintegration and breaking down of the cell-walls which had previously existed, as in Obs. XXV.—(Fig. 63.)

#### OBSERVATION XXXI.

CANCER OF OMENTUM AND PERITONEUM, LOADED WITH CALCAREOUS DEPOSIT—ASCITES—  
DEATH.

MRS LINDORES, æt. forty, admitted into the Royal Infirmary, November 17, 1843, under Dr Paterson. Four weeks previously, while undergoing

a mercurial course (for what is not stated), she bathed in the sea. To this she ascribes the origin of her complaints. A few days afterwards the abdomen became painful, but this went off, without medical attendance, in the course of two or three days. But the urine now became scanty and high coloured. The abdomen also gradually enlarged. On admission the urine continued to be scanty and high coloured—not albuminous—but depositing a copious lateritious sediment. The abdomen was firmly distended, bulging laterally, fluctuating, with considerable tympanitis. There was no hepatic or other dulness, except in the parts where the fluid gravitates. No tumour of any kind could be felt. The menses were regular, and there was no heart or other chest disease. A variety of diuretics were employed, the mouth affected with mercury, and watery evacuations procured from the bowels by gamboge and other cathartics. By these means a temporary diminution of the swelling was procured from time to time—but one after another they lost their efficacy, and the dropsical symptoms again obtained the ascendancy. At length, having been five months in the hospital, and becoming worse instead of better, she was by her own desire dismissed, the size of the swelling in no way diminished, and her strength much reduced. A few weeks before her dismissal, a tumour of irregular shape and nodulated on the surface was detected in the abdomen, below the inferior edge of the liver, and apparently unconnected with it, extending across to the left side, and easily moveable. It was considered to be connected with the omentum or mesentery.

Some time after leaving the hospital, and in compliance with her own urgent request, she was tapped. A large quantity of dark coloured fluid was drawn off. The tumour, which had been obscured by the accumulated fluid, was now found to have increased considerably, and was easily traceable—passing transversely across the upper part of the abdomen, and then apparently directing its course downwards to the left iliac and hypogastric regions. After the tapping she experienced considerable relief, but soon the fluid began again to collect—again she was tapped, and this operation was performed altogether four times, the strength gradually declining and the bulk of the diseased mass increasing. The last tapping was about three weeks before her death, which took place in the beginning of January 1845, about eighteen months from the commencement of the symptoms.

*Sectio Cadaveris.*—January 11, 1844. Body greatly emaciated. The abdomen greatly swollen.

*Abdomen.*—The peritoneal cavity was distended with a large quantity of dark coloured fluid, similar to what had been drawn off by tapping. Lying across the abdomen, and attached to the omentum, was a large tumour of irregular form, nodulated all over the surface, and several of the nodules presenting much of the cauliflower character. On being cut into, the tumour was generally hard, semi-cartilaginous, and gritty to the feel. Here and there some of the nodules were soft, readily breaking down under the finger, and yielding on pressure a milky juice, loaded with minute particles of calcareous matter. The surface of the abdominal peritoneum was sprinkled over with

masses varying in size, similar in appearance and consistence to the nodules on the tumour. At the point where the trocar had been introduced, a large mass of the same kind had formed. The organs at the lower part of the abdomen, especially the uterus and ovaria, were imbedded in a mass of the same morbid structure, originating from the peritoneum. The organs themselves were healthy. The liver was somewhat contracted; the cut surfaces presented the nutmeg appearance, and its peritoneal coat was covered with the same masses as those seen on other parts of the membrane.

*Microscopic Examination.*—On examining a drop of the milky juice squeezed from a softened nodule, it was seen to contain; 1st, numerous molecules and granules; 2d, round, oval, or irregularly shaped cells, varying in size from the 1-100th to the 1-50th of a millimetre in their long diameter, some containing a small round nucleus, and others only granules and molecules; 3d, a few fusiform corpuscles; and, 4thly, numerous irregular masses of mineral matter, which disappeared on the addition of muriatic acid—(Fig. 78). A section could not be obtained, on account of the friable nature of the structure, and the quantity of calcareous salts deposited in it.

Fig. 78.

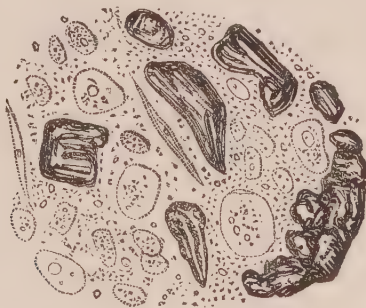


Fig. 78. *Corpuscles with mineral matter, removed from abdominal tumour, described Obs. XXXI.*

*Remarks.*—The cells in the morbid growth of this case, were also in a stage of disintegration. The nucleus was absent in the majority, and replaced by a greater or less number of granules, somewhat similar to those represented Figs. 38, 48, 75. Associated with these retrograde cells were a few fusiform corpuscles and an immense quantity of mineral matter, which every where pervaded the tumour. On drying a slice of it, the whole was converted into a calcareous mass, of little less bulk than when moist. This case then, independent of others which may be adduced, proves that in some instances a cancerous as well as a tubercular exudation may undergo the calcareous degeneration. The progress of the disease must have been very slow, as there can be little doubt that the tumour existed long before it was detected, and was the cause of the dropsical symptoms.

## OBSERVATION XXXII.

CANCROID TUMOUR ATTACHED TO THE TENTORIUM PRESSING UPON THE CEREBELLUM—  
INFLAMMATORY SOFTENING OF CEREBELLUM—CHRONIC TUBERCULAR CAVERN IN  
LEFT LUNG, WITH VEGETATIONS—DEATH.

MARGARET BOYNE, æt. forty, admitted into the Royal Infirmary, March 3, 1847, under Dr Andrew. She has never enjoyed good health, on account of stomachic derangement more or less severe. Latterly she has become much emaciated, and been subject to fits, said to be hysterical. On admission there is extreme emaciation, and severe headach occurring at irregular intervals, but more acute towards evening and during the night. She frequently utters loud screams, and, on awakening from sleep, appears quite bewildered. The memory is much impaired. There is occasional vomiting, with pains in the stomach. The bowels are constipated. The menstrual discharge has been absent for some time. No fever; pulse 100.—*March 12*, She was observed to-day to squint with both eyes, and says that she sees double. The pain in the head is much increased, and the memory greatly impaired.—*March 13*, The articulation is defective.—*March 14*, Cannot be induced to speak; moans constantly. The strabismus continues, and she now passes urine involuntarily. There is no paralysis.—*March 15*, Comatose, sunk gradually, and expired in the evening.

*Sectio Cadaveris, March 17, 1847.* Body greatly emaciated.

*Head.*—The membranes of the brain were unusually dry, but otherwise healthy. Substance of the cerebral lobes healthy. From the two lateral ventricles nine drachms of clear serum were collected. On removing the base of the brain, it was discovered that the left lobe of the cerebellum was unusually soft, and pressed upon by a tumour firmly adherent to the inferior surface of the tentorium. The tumour was externally soft, the size of a hen's egg, and imbedded in the left lobe of the cerebellum. The substance of the cerebellum immediately in contact with it, and to the depth of a quarter of an inch, was softened, and of a light yellow fawn colour. This lesion gradually terminated in the healthy substance of the cerebellum. Leaving the tumour within the cranium, the cerebellum was now removed: on being subjected to a stream of water, it presented a deep cup-shaped cavity, corresponding to the size of the tumour, and a portion of its softened substance which had been washed away. The tumour was externally soft and pulpy, but on section was found to increase in density towards the centre. The nucleus, which was about the size of a walnut, was exceedingly tough under the knife, and its section displayed a smooth white surface, slightly tinged of a pale yellow. It was firmly adherent to the tentorium by a broad base.

*Chest.*—The pleuræ on the left side were strongly adherent over two superior thirds of the chest. It was found impossible to remove the lung without breaking into a chronic cavity in its apex the size of a hen's egg. The whole of the superior lobe was much condensed, indurated to the feel, and contained numerous



cavities, varying in size from a hazel-nut to the large one in the apex just mentioned. Their walls were hard and rigid, of a mahogany brown colour, lined by a distinct membrane, free from pus or recent tubercle, and studded here and there with calcareous concretions. The large cavern at the apex contained a brown, corrugated, inspissated matter, of cheesy consistence and friable, covered all over with a white mould. The inferior lobe of this lung was healthy. The pleuræ on the right side were also strongly adherent at the apex, over a space the size of a five-shilling piece. Here also was a chronic cavern the size of a nutmeg—its walls containing several calcareous concretions, and its cavity a quantity of friable cretaceous matter. It was surrounded by considerable puckering, and numerous obliterated bronchi, composed of fibrous tissue arranged in a stellate manner around it.

The abdominal organs were healthy, with the exception of a few small tubercular deposits in the glands in front of the ileo-cæcal valve.

*Microscopic Examination.*—On examining a thin section removed from the centre of the tumour, it presented a dense amorphous mass. On adding water and breaking it up somewhat, it was found to consist of numerous tubercle corpuscles, innumerable molecules and granules, a few fusiform corpuscles, and globules with double lines, closely aggregated together (Fig. 79). The softening in the cerebellum was composed of fragments of cylindrical and varicose tubes, mingled with numerous molecules, granules, and compound granular corpuscles and masses (Fig. 80).

The mould in the pulmonary cavern consisted of beautiful cryptogamic formations, the description of which in this place is unnecessary.

Fig. 79.

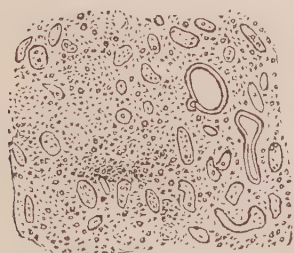
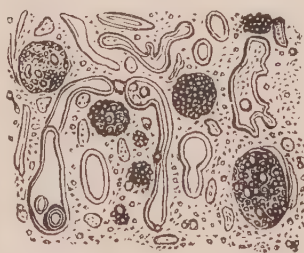


Fig. 80.



*Fig. 79. Structure of the centre of tumour, described Obs. XXI., composed of molecules, granules, and tubercle corpuscles, associated with a few fragments of nerve tubes. Fig. 80. External and more softened portion of the tumour, containing a larger number of fragments of the nerve tubes, with numerous compound granular corpuscles and masses.*

*Remarks.*—This singular case admits of many observations having reference to the brain and lungs—which, however, are not in any way connected with the present inquiry. The position of the tumour, attached to the under surface of the tentorium, and exerting its pressure and disorganizing powers directly downwards on the lobe of the cerebellum, instead of on the pons varolii, explains

the absence of paralysis in the extremities. On the other hand, the strabismus may have been induced by the collection of fluid in the ventricles, which might also, by means of pressure on the cerebral lobes, be connected with the loss of memory and other cerebral derangements. On this subject, however, I need not dwell. The lesions of the lungs exhibited an unequivocal proof of tubercular caverns in progress of cure.

The tumour contained none of the cells we have seen so constant in cancer, but was composed of an agglomeration of imperfectly formed bodies, usually denominated tubercle corpuscles. From this circumstance, as much as from the occurrence of old tubercular caverns in the lungs, we can have little hesitation in considering its nature to be tuberculous instead of cancerous, as it was first supposed to be by all who saw it. Many such growths in the brain have doubtless been recorded as cancer of that organ.

#### OBSERVATION XXXIII.

##### CANCROID TUMOUR ATTACHED TO THE TENTORIUM—INFLAMMATORY SOFTENING OF THE RIGHT CORPUS STRIATUM AND OPTIC THALAMUS—DEATH.<sup>1</sup>

MRS M., at the period of her death aged seventy-eight, had always enjoyed good health until the 1st of October 1845, when she was found lying on the floor comatose, although perfectly sensible and well a few minutes previously. Complete stupor continued for many hours, with stertorous breathing, and when consciousness returned the left side of the body was found to be paralysed. In the course of three weeks the paralytic arm began to stiffen, and this went on gradually increasing; so that, in the course of a few months, the arm was strongly contracted, and the fingers bent and fixed like a bird's claw. During this period intelligence partially returned, and she was able to recognise friends, and answer a few simple and direct questions. She talked much, however, incoherently, and laboured under numerous hallucinations. Her manner was now very childish. She had frequent fits of crying and irritability, and now and then fell into a stupor, marked by lividity of countenance and a quick pulse. This condition passed off in a few hours, after a stimulant was exhibited. The left leg underwent the same gradual progress of stiffening as the upper extremity, but not to so great an extent, although it was the seat of some pain, and she was constantly entreating that it should be rubbed. About six months prior to death, she became worse in every respect, had very short intervals of partial consciousness, was extremely

<sup>1</sup> This case occurred in the practice of Dr Peddie, who kindly invited me to witness the examination.

irritable, uttered piercing cries, had involuntary evacuations, and became dropsical, with sloughing over the sacrum. She died on the 11th of March 1847.

*Sectio Cadaveris, March 13, 1847.* The head only was examined.

The membranes and external surface of the brain were healthy. On exposing the right lateral ventricle, the whole of the corpus striatum and anterior half of the optic thalamus were found to be softened, of pulpy consistence, and in one place diffluent, and of an ochry yellow colour. On cutting through the softened part transversely, the lesion was found to extend internally into the substance of the hemisphere over a space the size of a large walnut, the colour becoming lighter and lighter as it terminated in the healthy substance of the brain. A tumour was firmly attached to the under surface of the tentorium, and pressing on the substance of the left lobe of the cerebellum superiorly. It was the size of a small walnut, surrounded by a distinct cyst, and, when cut into, the substance presented a soft granular and slightly fibrous consistence, and pale yellow colour. The other parts of the brain were healthy.

*Microscopic Examination.*—The softening of the corpus striatum and optic thalamus contained numerous compound granular corpuscles, masses, and granules, mingled with broken down fragments of the nerve tubes, as in all cases of inflammatory softening.

On examining a minute portion of the substance of the tumour, it was found to consist of very peculiar bodies, imbedded in what at first appeared amorphous and granular matter (Fig. 81). The addition of water enabled me to separate the constituents of the tumour, composed, first, of the bodies alluded to, and, secondly, of the substance in which they were imbedded (Fig. 82).

1. These bodies were round or oval in shape, and varied in size from the 1-100th to the 1-20th of a millimetre in diameter. They were solid, transparent, with dark abrupt edges, shadowed gradually toward the centre. Each was inclosed in a sheath of filamentous tissue, varying in thickness from the 1-120th to the 1-80th of a millimetre in diameter. Direct pressure caused them to crack in various ways, but generally in a radiated manner, from the centre to the circumference, with two or several segments (*b, c, d*). An excess of ether, and even boiling in that fluid, produced no change in them. Acetic acid made the sheath more transparent, and rendered visible several oval and elongated nuclei of the filamentous tissue (Fig. 83). Alcohol and caustic ammonia produced no change. Friction caused them to assume a cylindrical form (*e*). On the addition of diluted nitric acid, they gradually became more transparent, and exhibited a concentric fibrous arrangement around a circular or oval space. This space, which now resembled a nucleus, contained one or two distinct nucleoli, which in its turn contained or was composed of one or more granules (Fig. 84).

From this it became evident that these were organic bodies impregnated with mineral matter, the nature of which my friend, Dr Douglas Maclagan, was so good as to determine. On incinerating a portion of the tumour in a platina crucible, it was reduced to a white ash, in which the globular bodies could still be detected by a microscopic examination. The investing membrane had been destroyed, but

the bodies themselves were unchanged, with the exception of a crenated margin, and the presence of distinct concentric rings. Dr Maclagan then determined the earthy matter to consist principally of phosphates.

2. The substance in which these bodies were imbedded, when diluted with water, was seen to consist of nucleated fibro-plastic corpuscles (Lebert), oval, elongated, and passing into fusiform corpuscles, of which there were great numbers. These were mingled with a considerable quantity of molecules and granules (Fig. 82).

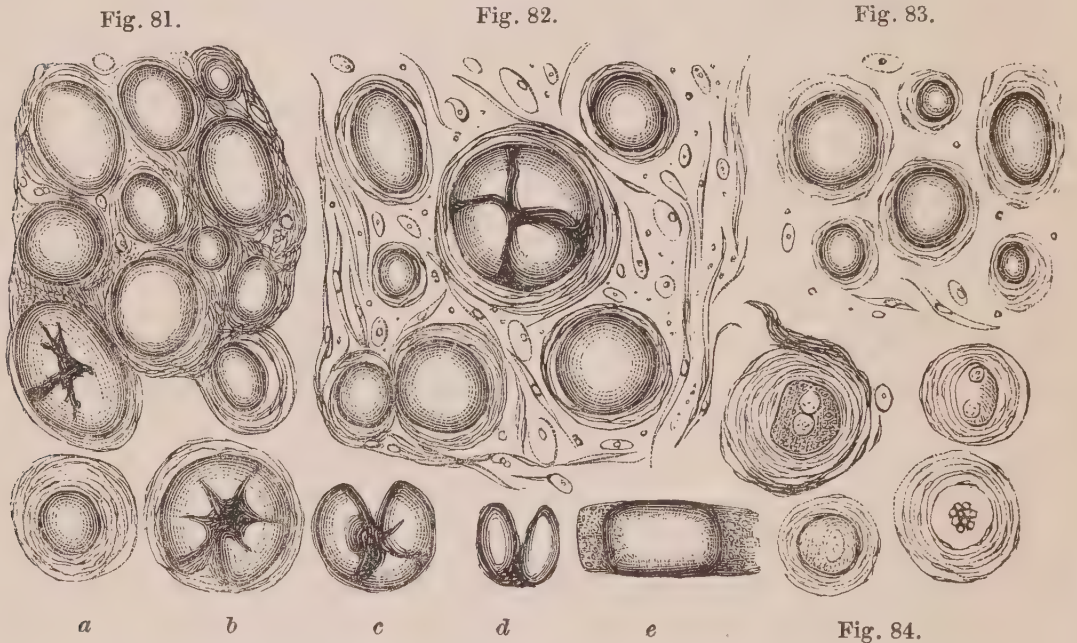


Fig. 81. Mineral bodies imbedded in a seemingly amorphous matter, described Obs. XXII. Fig. 82. The same after dilution with water. Fig. 83. The same after the addition of acetic acid. Fig. 84. The same after the addition of nitric acid. *a.* One of these bodies with a thick investing capsule. *b* to *d*, Others exhibiting various methods in which they crack on pressure. *e.* Cylindrical form produced by friction.

*Remarks.*—The structure of this tumour appeared to me to be so peculiar, that I requested Dr Richard Quain to exhibit it to the Pathological Society of London. This he kindly did at its meeting of the 5th of April 1847. At the following meeting, it is reported that Dr Garrod had also made a chemical examination of these bodies, and found them composed chiefly of phosphate of lime and animal matter; that when incinerated, they were insoluble in acetic acid and alkalies, but soluble in hydrochloric and nitric acids, and precipitated from its solutions by ammonia.

Mr Nathaniel Ward remarked, that the bodies under consideration appeared analogous to those described by Valentin as occurring in the choroid plexus and pineal gland; and which, he states, appear under the microscope at first sight something like air bubbles, but on closer examination are found surrounded by a clear transparent

membrane, so as to appear to be contained in a cell formation. On being pressed, they break in a radiated manner, transversely or irregularly. After treatment with acids, the organic skeleton remains, and the concentric structure is still visible. They are with difficulty converted into an ash under the blow-pipe, and even then preserve their laminated arrangement. They are composed of carbonate of lime, with the basic phosphate, mixed up with a little phosphate of magnesia and ammonia.

On referring to the plate and description of Valentin alluded to, there can, I think, be little doubt that the bodies he has described are analogous to, if not identical, with those occurring in the preceding Observation. Lebert has figured similar mineral bodies presenting concentric laminae, found in a cyst, with walls apparently ossified, from the ovary (*Physiologie Pathologique*, Plate XI. Fig. 10). He has also given three representations of cancer cells with several concentric circles, apparently owing to the regular growth of cell within cell (Plate XVIII. Fig. 9; Plate XXI. Figs. 4 and 9). In one of these latter (Fig. 4), there were both single and double nuclei, as I have figured the bodies in Obs. XXII., after the addition of nitric acid (see Fig. 84). Gluge also, in the Sixteenth Part of his *Atlas of Pathological Anatomy*, figures similar bodies (Plate II.) removed from an encysted tumour in the dura mater at the base of the brain. He describes them as dividing into four segments on pressure, and as being entirely soluble in mineral acids. Nothing is said of their possessing an organic basis.

The true nature of these bodies is involved in some obscurity, but since writing the above Observations, I have had several occasions of witnessing the mode of their formation in the choroid plexus. At first there seems to be deposited a quantity of mineral granules in round or oval patches more or less large. As these become more numerous, a clear centre, composed of transparent homogeneous mineral substance, may be seen in the centre, which gradually extends to the circumference, until the whole presents a uniform mass. The bodies thus formed exactly resemble those represented Fig. 82, with the exception of the fibrous sheath, which in the choroid plexus was absent. They are in many respects very similar to the mineral concretions so common in the prostate gland.

I may allude to another point in the structure of this singular tumour which is deserving of notice, namely, the peculiar oval cor-

puscles found in the soft mass of the growth. To me it seems certain that these bodies are connected with the fibrous tissue, and are nuclei from which fusiform corpuscles and filaments are produced. As stated in the remarks appended to Obs. XXI. and XXIV., they ought not in any way to be considered as an essential part of a cancerous structure.

With respect to the case itself, there can be little doubt that all the symptoms were produced by the softening of the corpus striatum, optic thalamus, and cerebral hemisphere. The tumour had caused no corresponding depression in the cerebellum, or induced organic lesion in it, and had probably in no way contributed to the fatal event.

#### OBSERVATION XXXIV.

CANCROID TUMOUR BELOW THE INTEGUMENTS OF THIGH—EXCISION—RETURN IN SIX YEARS—RE-EXCISION.

A young lady, æt. twenty-five, strong and healthy in appearance, applied to Mr Miller, labouring under a tumour on the outside of the left thigh, near and rather in front of the trochanter. It seemed to be the size of an almond or small walnut, quite superficial, moveable, and connected with the skin. She stated, that eleven years ago a tumour began to grow in this situation, which she attributed to a weakness in the ankle that prevented her walking. The uneasiness in the ankle and in the tumour seemed to be connected with one another. Seven years ago the growth was dissected out ; but there always remained a small hard knot or kernel in the cicatrix. For six years she perceived no change in it ; but twelve months since it began to enlarge, and has gradually attained its present size.

Mr Miller excised the growth, May 5, 1848, and the operation was followed by no bad symptom. The wound healed principally by the first intention. The patient has since perfectly recovered, and now (August 1848) only complains of slight weakness in the limb.

*Description of the Tumour removed.*—The tumour was of an oval form, about the size of a small almond nut, situated immediately below the skin, to which it was intimately adherent anteriorly. It was hard and dense to the feel, grating under the knife on section, its cut surface smooth, of slightly yellowish tinge, and yielding no juice on pressure. In texture it seemed to be densely fibrous.

*Microscopic Examination.*—On gently scraping a fresh cut surface of the tumour, the pulp so produced was found to contain numerous oval transparent corpuscles, varying in their longest diameter from the 1-100th to the 1-50th of

a millimetre in length. Several contained a single granule about 1-500th of a millimetre in diameter, others contained two of these—(Fig. 85). They were mingled with several molecules and granules. On adding acetic acid their outline became more and more distinct, but they otherwise underwent little change—(Fig. 86). A thin section made by means of Valentin's knife showed the stroma of the organ to consist of fine filaments, among which the oval bodies just described were every where infiltrated. Here and there a peculiar structure in the form of large oval rings was observed, about 1-50th of a millimetre in thickness, marked by converging irregular lines. In a few places oval concentric circles were observed—(Fig. 87). On adding acetic acid to a section, the fine filaments of the stroma became very transparent, and numerous oval and elongated nuclei, following the direction of the fibres, were rendered very distinct—(Fig. 88).

Fig. 85.

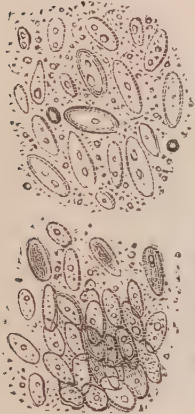

Fig. 87.



Fig. 88.



Fig. 86.

*Fig. 85. Corpuscles scraped from the surface of tumour, described Obs. XXXIV. Fig. 86. The same after the addition of acetic acid. Fig. 87. Appearance of a thin section of the tumour. Fig. 88. Another section treated with acetic acid.*

*Remarks.*—What was the nature of this growth? The oval bodies with one or two nucleoli were evidently naked nuclei, as was shown not only by their form and structure, but by their persistence under the action of acetic acid. The transverse irregular lines in the oval rings were clearly layers of epithelium, probably lining the internal surface of some duct or follicle. The concentric rings were also a divided duct. No trace of cell growth could be observed in connexion with the nuclei; and although these exactly resembled such as we have seen included within cancer cells—(Fig. 3)—it would seem that they may also be connected, as in the last Observation, with a purely fibrous structure, and possess no power of re-development. Must we consider, then, such a growth as cancerous, or simply fibrous in its nature? I am inclined to adopt the latter opinion, which is also favoured by the particulars of the case.

It would appear that this young lady first perceived the growth at the age of eleven years, a period of life highly unfavourable to the formation of cancerous growths. Four years afterwards it was excised, but a hard nodule or knot remained in the cicatrix, which continued stationary for six years, and during the last twelve months gradually reached the size of an almond nut. This history, the appearance of the growth, and its density, would lead us to suppose that the oval bodies described are portions of the fibrous element; and numerous Observations, to which I shall afterwards refer, as well as some of those which have preceded (Obs. XXI., XXII., XXIII.,) certainly tend to support this opinion.

#### OBSERVATION XXXV.

##### CANCEROUS TUMOUR OF MOUTH—EXCISION—RETURN—RE-EXCISION.

MISS M——, æt. forty, twelve years ago observed a tumour growing from the mucous surface covering the hard palate, on the right side of the mouth. It was excised by Mr Mackenzie of Glasgow several years ago. Numerous substances were applied to the wound, and among others she believes caustic. Not long after the wound had healed, a tumour again made its appearance. When first seen by Mr Miller it was the size of a pigeon's egg, situated beneath the mucous membrane of the hard palate, and incorporated with it, close on the alveolar range, at the back part of the right side of the upper jaw. It was fixed, elastic, painful on pressure, and felt as if a soft tumour had begun in the interior of the bone, and had projected through. A carious tooth existed in its neighbourhood, which was extracted, and the tumour in the course of a week became less painful in consequence. It now also seemed more moveable, and not to be incorporated with the bone, and its removal was determined on. On the 17th of June 1848, Mr Miller excised the tumour close down to the bone, and applied potassa pura to the base of the wound. On examining the tumour, it was seen that a portion of it had been left attached to the alveoli. This was entirely removed next day, but no more caustic applied. The wound healed rapidly, without a bad symptom, and is now (July 30) completely healed.

*Description of Tumour removed.*—The tumour was of oval form, the size of a pigeon's egg, hard and dense to the feel, and closely attached to the mucous membrane of the mouth. At one place it had been cut through, exhibiting a pale yellow, waxy coloured surface, from which no fluid could be squeezed on pressure. It was evidently fibrous in texture, and could be torn up in certain directions without difficulty.



*Microscopic Examination.*—On scraping the fresh cut surface of the tumour with a knife, the pulp so removed was found to contain numerous cancer cells, generally oval and round in form, although a few were caudate. In size they varied from 1-70th to 1-35th of a millimetre in their longest diameter, and contained a round or oval nucleus, furnished with one or two nucleoli. Some of these nuclei floated naked among them, associated with granules and molecules—(Fig. 89). On the addition of acetic acid, the external cell-wall was either dissolved or rendered very transparent, whilst the nuclei were unaffected—(Fig. 90). A section of the tumour, made with a Valentin's knife, exhibited a fibrous stroma, the filaments of which in many places were in concentric circles; the whole was densely infiltrated with the cancer cells, giving it a confused appearance—(Fig. 91). On adding acetic acid the filamentous structure became more transparent, whilst the nuclei became very distinct.

Fig. 89.

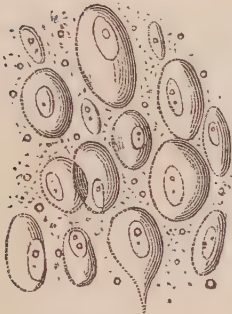


Fig. 90.



Fig. 91.



*Fig. 89. Cancer cells scraped from the cut surface of the tumour, described Obs. XXXV. Fig. 90. The same after the addition of acetic acid. Fig. 91. Appearance of a thin section of the tumour.*

*Remarks.*—The form and general appearance of the tumour, as well as the history of the case, are very much the same as that recorded in the last Observation. In both, the tumour returned after excision, but in one the patient's age was much more advanced than in the other. The minute structure of the two growths, however, was very different; the fibrous stroma in Obs. XXXIV. being infiltrated with naked nuclei, whilst in Obs. XXXV. it was infiltrated with cancer cells. What conclusion are we to draw from this circumstance? Is one growth more malignant or capable of reproduction than the other? The future history of the cases may perhaps throw light on these questions—to the discussion of which I shall refer at length in the second part of the work.

## OBSERVATION XXXVI.

## CANCROID TUMOUR OF THE MAMMA—EXCISION—CURE.

HELEN WHITEFIELD, æt. forty-seven, married, admitted into the Royal Infirmary, March 13, 1848, under the care of Mr Miller, with a tumour of the breast, which commenced eight years ago, but within the last six months it has grown much larger. The tumour is about the size of a small cocoa-nut, of firm consistence, and unattended with pain.

On the following day the tumour was excised, and as on dissection it was found to be in a distinct cyst, and quite separate from the substance of the gland, it was not thought necessary to remove the latter. Three arteries were tied.

Slight inflammation occurred around the lips of the wound, which retarded its cure; but she was dismissed by desire, March 28, 1848.

*Description of the Tumour removed.*—Half of the tumour removed was brought to me to examine. It was the size of half a small cocoa-nut. The external surface was nodulated, but surrounded by a distinct fibrous cyst, which completely isolated it from the substance of the gland. The cut surface was of a fawn colour, presenting a fibrous structure, the filaments being arranged here and there in loops and concentric circles. Its substance was solid and dense, without any trace of cysts, and no fluid could be squeezed from it on pressure.

*Microscopic Examination.*—On scraping a fresh cut surface with a knife, and examining the pulp so removed, it was seen to contain groups of transparent oval cells, more or less compressed together—(Fig. 92 *b*). Some of these floated loose, when they were seen to be about the 1-50th of a millimetre in their longest diameter, and each to be furnished with an oval nucleus about one-half their volume. On adding acetic acid the cell-walls became very transparent, whilst the nuclei were unaffected, and became more distinct in appearance—(Fig. 92 *a*). Here and there oval or rounded bodies could be observed characterised by a distinct ring, about the 1-50th of a millimetre in thickness, marked by interrupted radiated lines, enclosing groups of the cells just described—(Fig. 92 *c*).

On making a section of the tumour with a double-bladed knife, and adding acetic acid in order to render it more transparent, it presented on examination the appearance represented Fig. 93. The basis or stroma of the growth was made up of fibrous tissue, in which well-developed elongated nuclei were scattered at intervals. Imbedded in this were oval or round rings, such as have just been described, enclosing the cells formerly noticed. On making another section at right angles to the former, and treating it with acetic acid, large tubes could be seen ramifying in the fibrous stroma, crowded with nucleated cells, the walls of which were rendered transparent by the acid, whilst the nuclei were greatly crowded together—(Fig. 94.)

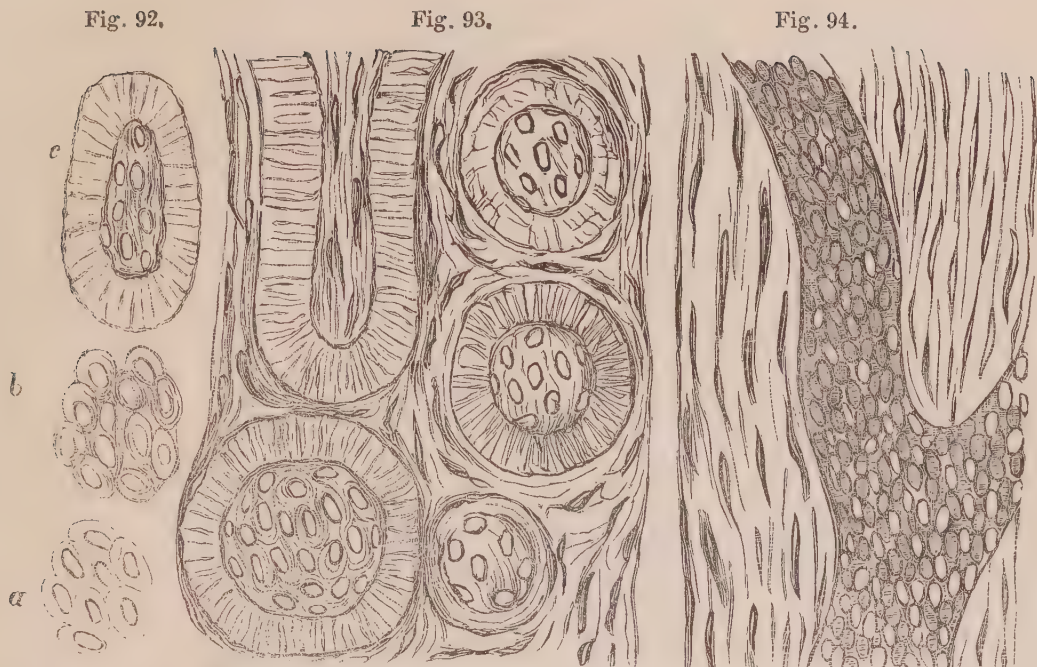


Fig. 92. c. Section of the epithelium from one of the tubes from the tumour, described Obs. XXXVI. b. Group of epithelial cells from the same. a. The same after the addition of acetic acid. Fig. 93. Thin section of the same tumour, after the addition of acetic acid. Fig. 94. Another section transverse to the former, similarly treated.

*Remarks.*—This tumour closely resembled the one described Obs. III., and consisted of hypertrophy of the fibrous structure of the gland, with hypertrophy of the included ducts and their epithelial linings. The loose annular bodies seen in the pulp of the tumour appeared inexplicable, until an examination of sections of it showed that they were coherent masses of epithelium, which had been squeezed out of the ducts. The appearance of the transversely and obliquely divided ducts is well seen—(Fig. 93). A longitudinal section, on the other hand, exhibited these ducts to be crowded and obstructed by an excess of epithelium formation. This view of them exactly resembled the appearance of the tubes in the kidney, when affected with a similar lesion.

#### OBSERVATION XXXVII.

##### CANCROID TUMOUR OF THE PAROTID GLAND—HEMIPLEGIA OF THE FACE—DEATH.

MRS S., æt. fifty-eight, of spare but otherwise healthy frame of body, consulted me about the commencement of 1845, for an unpleasant sensation she experienced in the left eye. On examination, I found that the eyelids could not be closed, that the under one was dragged down, that there was constant epiphora, and that the mouth was slightly dragged towards the right side. Paralysis, depending upon lesion of the portio dura, was diagnosed. The symptoms gradually increased in intensity. Towards the end of 1845, her face and

features presented all the symptoms of the lesion in a very marked manner. About this time, also, a small indurated swelling was observed immediately below the left ear. This slowly increased, and towards the end of 1846, had obtained the size of a hen's egg, the motor paralysis of the face being in no way diminished, and her general health continuing good. In the spring of 1847, the tumour had considerably extended downwards and backwards, and was irregular and nodulated on the external surface. She never suffered pain, and only experienced inconvenience from the tears occasionally rolling over the left eyelid upon the cheek, the difficulty of mastication, and the facial deformity. On the 18th of August, I found her labouring under the most violent pain in the right hip and knee joints, apparently rheumatic. She had gone into the country a few miles, thinly clad, and exposed to a cold evening breeze, in an open phaeton. The pains, very intense, were increased on the slightest movement. The parotid tumour was now much increased in size, presenting a nodulated prominent mass the size of the fist, extending downwards and inwards towards the throat, and its most prominent part of a deep crimson, and even purplish hue. It was, however, every where hard, non-resistant, and free from pain. The intense rheumatic pains in the two joints continued intense, and defied all kinds of treatment, internal and external, for four weeks. The confinement to bed reduced her strength considerably, and it was with the greatest difficulty bed-sores on the back were prevented.—*September 16th*, she complained of slight difficulty of swallowing, which in a few days became so great, that nothing but liquid food could be taken, and even that with great difficulty.—*September 22d*, she complained of an incessant discharge of thick, glairy mucus, apparently from the throat, which caused her much trouble to get up.—*September 24th*, the strength was now greatly diminished. She could take little nourishment, or none: the pulse was feeble, and accumulation of mucus in the throat threatened suffocation. Died on the 28th at 4 A.M., preserving her intelligence nearly to the last, and without any symptom having been manifested referrible to derangement of the thoracic or abdominal organs.

*Sectio Cadaveris, September 30th, 1847.*—The tumour and the cervical region only were allowed to be examined. The former was the size of a man's fist, nodulated on the surface, hard to the feel, and the skin covering it of a deep red colour, but not ulcerated. It occupied the whole region at the angle of the jaw, overlapping the mastoid process posteriorly, pushing up the ear, and descending inferiorly to the middle of the neck. The skin was thin over the tumour, and so firmly adherent that it could not be dissected off. The edges of the tumour could easily be raised from the parts it covered; but its roots sunk deep into the space at the angle of the jaw, and could be traced back as far as the vertebræ. It closely embraced the bloodvessels and nerves, causing more or less atrophy of them, and the sterno-mastoid muscle was completely atrophied anteriorly in front of the tumour, and converted into fibrous tissue.

The tumour on section was of a yellowish-white colour, and of tolerably firm consistence, resembling an hypertrophied parotid gland. A glutinous substance

was deposited in it, which could be scraped from the cut surface by the knife ; but no cancerous juice could be squeezed out. All the lymphatic glands of the neck were much enlarged, and were similarly affected.

The trachea, esophagus, and other structures of the neck, were healthy.

*Microscopic Examination.*—On examining the viscous juice scraped from the section of tumour, it was seen to contain numerous corpuscles, as represented Fig. 95. They were of oval form, and great delicacy, varying in size

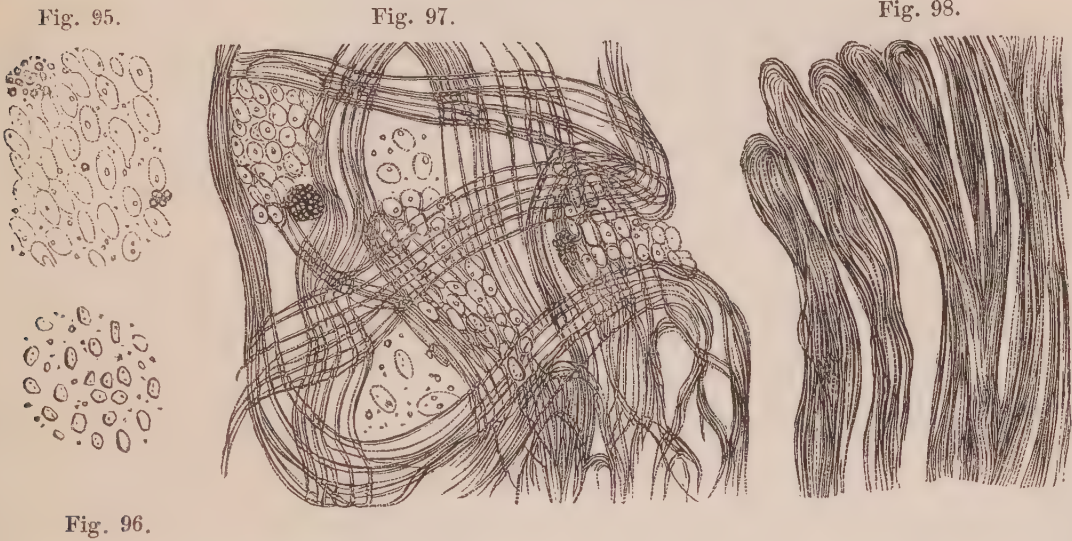


Fig. 95. Corpuscles in tumour, described Obs. XXXVII. Fig. 96. The same after the addition of acetic acid. Fig. 97. Fibrous matrix of the tumour, with loculi and groups of corpuscles. Fig. 98. Fibrous bands from another portion of the tumour.

from the 1·100th to the 1·75th of a millimetre in their longest diameter. They generally contained one, although sometimes two granules. Here and there one of these corpuscles might be seen somewhat elongated, and a few were distinctly caudate. They were imbedded in a transparent blastema, sprinkled throughout which were numerous granules. On the addition of acetic acid, the corpuscles were contracted to one half or one third their for-

Fig. 99.

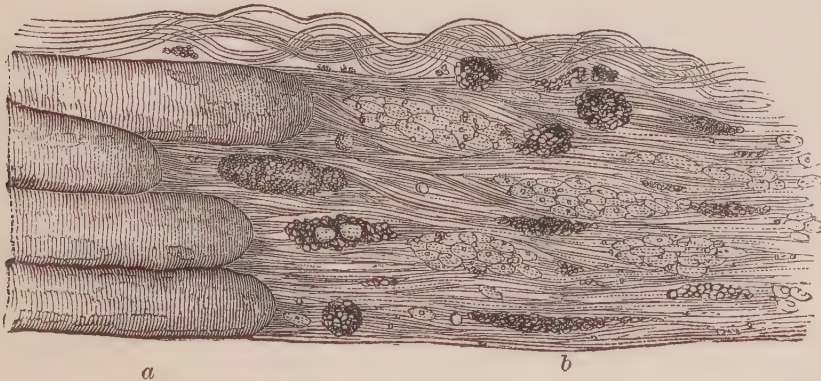

Fig. 99. Section of the sterno-mastoid muscle where it appeared atrophied, and converted into fibrous tissue. a. Muscular fasciculi. b. Fibrous tissue, containing groups of corpuscles peculiar to the tumour, with granules and compound granular corpuscles.

mer volume, and the external margin, which previously was very delicate and transparent, became thicker and more distinct. A section of the tumour with Valentin's knife, exhibited the arrangement of its fibrous matrix, consisting in some places of an open network of filamentous tissue, containing groups of the corpuscles formerly described—Fig. 97; or dense bands of the same tissue, forming loop-like terminations—Fig. 98. The addition of acetic acid did not bring into view any nuclei amongst the fibrous tissue.

A section through the sterno-mastoid muscle, where it passed over the tumour anteriorly, and where the muscular fibres seemed lost in it, displayed inferiorly the fasciculi, terminating in a rounded abrupt manner. The transverse striæ were distinct nearly up to these terminations, when the fasciculus seemed to be composed wholly of minute molecules and granules, (not sufficiently well represented by the engraver—Fig. 99). From these rounded ends of the muscular fasciculi, fibrous tissue seemed to arise abruptly, which became identified with that of the tumour, except that for some distance they followed the course of the muscle. Between the fibres oval groups of the corpuscles might be seen here and there, together with other groups of granules, and compound granular corpuscles.

*Remarks.*—The only other case similar to the above which has ever been minutely examined, so far as I am aware, is one recorded by Sédillot. It was that of a man, aged fifty-one years, in whom a tumour of the parotid, the size of a nut, was of fifteen months' growth. It then became painful, the skin assumed a bluish livid appearance, and ulcerated. The ulceration extended rapidly, the pains became lancinating, suppuration was abundant, and he died after the disease had destroyed the parotid gland, half the ear, and the mastoid process. Portions of tissue removed from the ulcer were examined by M. Küss, who found evidently the same corpuscles as I have described, with this difference, that they were more granular. Unfortunately, he does not inform us what effect acetic acid had upon them. He further says, that the tissue in some points had a vaguely fibrous aspect, but that true fibres were rare. This probably arose from the circumstance, that nearly all the tumour had ulcerated away.

Now, it may be asked what was the nature of this tumour? Mr Syme, who was early consulted in the case, considered it to be malignant, and beyond the reach of art from the first, and I myself had no doubt of its cancerous nature. Yet on examination not one of the cancer cells, which we have seen to be always present in undoubted cancer, was to be discovered. It must be remembered also, that Mrs S. never felt pain in the tumour, and that it continued hard

up to the period of her death; a result evidently produced from paralysis of the nerves of deglutition, rather than from any particular change in the tumour itself. Any false conclusions we might derive from these points, however, are at once corrected by the case of Sédillot, in which there were lancinating pains, ulceration, and sinking from an exhausting discharge. Notwithstanding these symptoms, so indicative of a malignant growth, Sédillot appears to arrive at the conclusion, that it was not cancerous. At least, although he expresses doubts on the subject, the case is denominated "*cancroid* of the parotid region."

What is the nature of the corpuscles described? May we consider them as nuclei of cancer cells? Certainly, their general size and structure would warrant such a supposition. But the occurrence of cancer nuclei in a tissue, which increases in size so gradually without any trace of cell formation, is opposed to what we have hitherto seen in undoubted cancerous structures. On the other hand, the corpuscles resembled those described Obs. XXI., XXII., XXIII., XXXIV.; and I have already ventured the surmise, that these and similar bodies are more connected with the fibrous than with the cell element of these growths. At least it seems to me certain, that they are not a necessary or characteristic constituent of true cancer.

#### OBSERVATION XXXVIII.

CANCROID TUMOUR OF THE NECK—EXCISION—RETURN IN TWO YEARS—  
RE-EXCISION AFTER TWENTY-ONE YEARS—CURE.

WILLIAM CARR, æt. fifty-three, a seaman from Newcastle, entered the Royal Infirmary, January 12, 1847, under the care of Mr Syme. About twenty-nine years ago, a tumour commenced growing on the left side of his face, a short distance below the ear. It had attained the size of a pea before his attention was directed to it, and was then felt to be hard and moveable. He is not aware of having sustained any injury in the neck to account for its origin. The tumour gradually increased, and eight years after its commencement was as large as a hen's egg. He then applied to Sir Astley Cooper, who excised it. For two years afterwards he observed a hard lump about the size of a pea again appearing in the same situation. This has been gradually increasing, but latterly with greater rapidity for the last twenty-one years. It has now attained the size of a large lemon, but of a very irregular lobulated shape.

On admission, the longest diameter of the tumour is transverse, and it is situated over the parotid gland, extending upwards to the cartilage of the ear, to which it appears somewhat closely connected; downwards below the angle

of the jaw; forwards on the cheek, to almost midway between the lower part of the ear and ala of the nose; and backwards beyond the mastoid process. It is quite moveable, apparently of a fibrous nature, with one or two small cysts on its surface.

On the 13th of January Mr Syme excised the tumour. The recovery was retarded by a pretty smart attack of erysipelas; but he was dismissed cured on the 8th of March, the cicatrix from the wound producing little deformity.

*Description of the Tumour.*—The tumour was of irregular form, consisting of nodules of various sizes, but approached the oval or pear shape, being nearly twice as long as it was broad. Its upper portion was considerably thicker than the under. It was of considerable density, firm and unyielding, except inferiorly, where two or three nodules were somewhat softened, and doughy to the feel. On section, the cut surfaces presented a glistening white, passing here and there into a grey colour. The form of numerous nodules, in some places compressed together, were still to be traced by circular or concentric bands of fibrous tissue. Each nodule varied considerably in consistence. Some were dense, semi-cartilaginous to the feel, crunching under the knife, and of a dull uniform white. Others were softened, of greyish colour, and almost gelatinous consistence, yielding on pressure a transparent greyish thick jelly. Between these two extremes were infinite varieties, some nodules being partly solid and partly gelatinous.

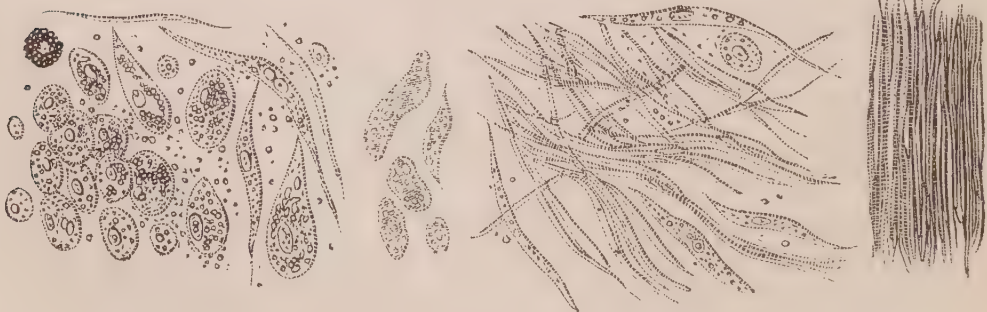*Microscopic Examination.*—On examining the grey transparent juice squeezed from the softer nodules, it was found to contain numerous cells, mingled with a few fusiform corpuscles. These cells were generally round or oval, varying in size from the 1-100th to the 1-50th of a millimetre in diameter, for the most part they were of the latter size—(Fig. 100). They each contained a small round or oval nucleus, about the 1-200th of a millimetre in its longest diameter. Some of these cells were somewhat larger, caudate, or spindle-shaped, and indeed presented all the different stages between the oval cell and fusiform corpuscle, and again between this last and the round filament—(Fig. 102). On

Fig. 100.

Fig. 101.

Fig. 102.

Fig. 103.



*Structure of a lobulated fibrous tumour removed from the neck by Mr Syme.* Fig. 100. Nucleated cells, varying in size, some round, others oval, caudate, and spindle-shaped. Fig. 101. The same, after the addition of acetic acid. Fig. 102. Fibres in various stages of development from a nodule of semi-gelatinous consistence. Fig. 103. Perfect fibrous tissue, from a nodule of considerable density.



adding acetic acid, the whole cell became more transparent, without exhibiting any different relation between the cell-wall and nucleus—(Fig. 101). In the harder nodules the structure was entirely composed of dense fibrous tissue—(Fig. 103); and in some of the others every gradation would be observed between the cell formation and their passage into fibres.

*Remarks.*—The true nature of this tumour admits of considerable difference of opinion. Mr Syme, before the operation commenced, considered it to be fibrous; but, during the operation, on feeling the softened nodules, he changed his opinion, and conceived it to be malignant. Some might be disposed to take the same view from the circumstance of its return after excision. On the other hand, it may be urged that the kind of softening which existed, was very different from that which occurs in really cancerous tumours. There was no milky or turbid juice; it more resembled the pulpy consistence of cystic sarcomatous tissues, which it so closely resembled in structure. The return of the disease in the same spot is no proof of cancer *per se*; and, when we take into consideration its slow growth, we cannot attribute much importance to this fact. Again, the corpuscles were not analogous to those of cancer. The small size of the nucleus, the effect of acetic acid, and the evident passage of these cells into fusiform corpuscles and fibres, evidently show that the tumour was essentially fibrous; that the soft gelatinous portions were the most recently formed parts; and that the cells had none of the properties we have seen to be characteristic of those undoubtedly cancerous.

### OBSERVATION XXXIX.

CANCROID TUMOUR OF THE NECK (ENCHONDROMA) EXCISION—CURE.

JOAN MACPHERSON, æt. thirty-eight, married, admitted into the Royal Infirmary, July 3, 1848, under Mr Miller. About three years ago she noticed a small hard swelling situated in front of the left ear, over the ascending ramus of the jaw. Cannot assign any cause for its appearance. During the next two years it remained nearly stationary, but for the last twelvemonth it has increased rapidly in size. It has never given any pain or inconvenience. With the exception of occasional attacks of rheumatism, her general health has been good. On admission there is a firm hard swelling, about the size of an egg, situated over the ascending ramus of the jaw on the left side. It also extends behind this bone, occupying part of the parotid region. It has no attachment to the bone, being readily moved by manipulation.

*July 5th.*—To-day the tumour was removed. Two lobules dipt down pretty

deeply ; but by exerting traction, and by careful dissection, they were removed in safety. There was very little bleeding. The wound was brought together by sutures, and dressed with lint dipped in cold water ; it healed kindly, and the patient was dismissed “cured” on the 14th of July 1848.

*Description of the Tumour removed.*—The tumour removed was of an oval form, about three inches long, and an inch and a half thick near the middle. It was nodulated on the surface ; in form resembled a rough kidney potato ; and was distinctly defined, the external surface being covered with a smooth membrane and entire. On section the cut surface presented a yellowish moist appearance, not unlike that of a potato, with little white cartilaginous-looking masses scattered here and there. These last could be felt harder than the surrounding yellowish matter. Pressure yielded no juice, but a soft pulp could readily be removed from the surface by means of scraping.

*Microscopic Examination.*—On examining the pulp scraped from the surface, it was found to contain numerous oval and caudate-shaped transparent corpuscles, varying in size, and measuring in their longest diameter from 1-50th to 1-40th of a millimetre. They each contained an oval nucleus, about 1-100th of a millimetre long, some of which floated loose amongst the corpuscles—(Fig. 104). A few were of somewhat triangular shape. Acetic acid caused the cell-walls to dissolve, or become very transparent, whilst the nucleus remained unaffected—(Fig. 105). Mixed with these cells were numerous compound granular corpuscles, round in form, of pretty equal size, varying only from the 1-50th to the 1-40th of a millimetre in diameter—(Fig. 104). On making a section through the yellowish and softer portion of the structure with Valentin’s knife, the same corpuscles were observed infiltrated in a mesh-work of exceedingly fine filaments. These, on washing out the corpuscles, presented the appearance represented Fig. 107. A section through the white and harder

Fig. 104.

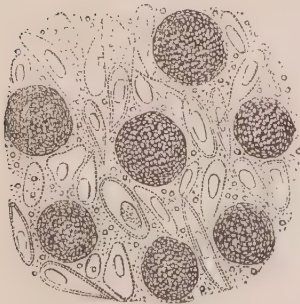


Fig. 105.

Fig. 106.

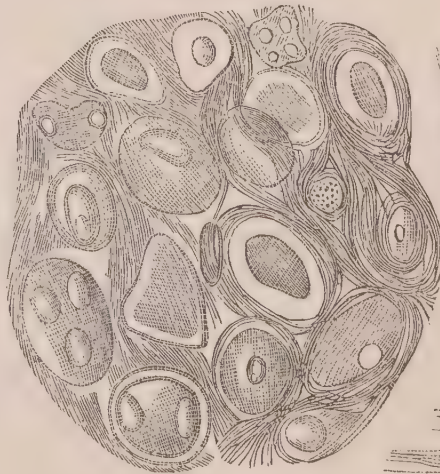


Fig. 107.



Fig. 104. Structures observed in the pulp scraped from the section of tumour, described Obs. XXXIX. Fig. 105. The same after the addition of acetic acid. Fig. 106. Thin section through a cartilaginous nodule in the same tumour. Fig. 107. Filaments which interlace the cells, these having been washed out.

nodules of the growth exhibited the usual characters of fibro-cartilage, consisting of large cartilage cells, with one or more included nuclei, surrounded in some places by a hyaline blastema, and in others by more or less of the fibrous elements—(Fig. 106).

*Remarks.*—All who saw the tumour judged, from its limited character and from its appearance, that it was fibrous, and not malignant. It was proved by microscopic examination to be partly cartilaginous, and partly composed of cells, the nature of which cannot be exactly stated. We shall hereafter see, however, that enchondromatous structures sometimes soften and break down; and that under such circumstances the cartilage cells become loose and isolated. It seems to me probable that this process was commencing in the tumour now under discussion, and that the cells figured (Fig. 104) may be softened cartilage cells. The triangular form of some, appears to favour this view. At the same time, it is possible that enchondroma may be associated with other forms of growth, and with true cancer, although it does not appear to me that the cells which have been described, at all resemble those observed in really cancerous formations.

## OBSERVATION XL.

### MELANIC CANCER OF THE CHEEK—EXCISION—CURE.

AGNES THOMSON, æt. thirty-five, admitted into the Royal Infirmary, December 2, 1845, under Mr Miller. Since her birth this patient has had an erectile tumour on her left cheek, which has been slowly increasing with her years. It opened spontaneously about three years ago, and a dark brown, semi-fluid substance was discharged. Last August she received a blow on the part, since which time it has become doubled in volume. On admission, the tumour in the cheek is as large as an orange, and extends from the lower eyelid to the angle of the mouth, and from the nasal bones to the zygomatic process of the malar bone. The tumour is tense, somewhat elastic, intimately involving the skin, and presents dark points on various portions of its surface. It appeared to be perfectly free from any connexion with the bone below, and was easily moveable.

On the 3d of December, Mr Miller removed the tumour, which, with the surrounding textures, were highly vascular. The skin was so much affected that none could be saved to cover the wound. Pressure from the morbid growth had caused partial absorption of the malar bone.—*Dec. 27.* She has been affected with erysipelas of the face and head to a considerable extent. The surface of the sore presents an unhealthy appearance.—*Jan. 2.* She has been living in lodgings for a few days, and the sore is now covered with healthy

granulations. Cicatrization proceeded favourably, so that on the 29th of January she was dismissed cured.

I had no opportunity of examining the tumour, only a portion of it, about the size of a pea, having been submitted to me for microscopic examination.

*Microscopic Examination.*—A minute portion of the tumour, examined microscopically, was seen to contain corpuscles varying in size from the 1-100th to the 1-25th of a millimetre in diameter. Some presented the usual appearance of cancer cells, being of round or oval form, and containing one or two oval nuclei, with one or two nucleoli. Others contained a quantity of pigmentary matter in the granular form, varying in intensity of colour from a bistre brown to a deep black. This pigmentary matter was seen to be accumulated generally between the nucleus and cell-wall, but here and there the nucleus only seemed to be crowded with them. Some of the corpuscles were large and irregular in form, whilst others had been lacerated by pressure between the glasses, causing extravasation of their contents—(Fig. 108). On the addition of acetic acid the transparent cancer cells had their walls partially dissolved, and the nuclei rendered very apparent. It produced no effect on the black pigmentary matter. Nitric acid, however, caused the melanotic appearance to disappear, and resolved the whole into a light brown granular mass.

Fig. 108.

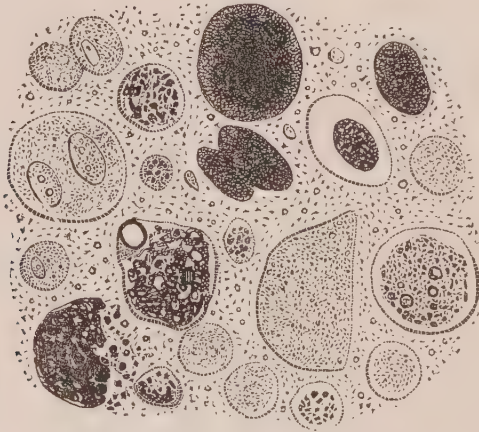


Fig. 108. Cells more or less loaded with black pigment from the tumour, described Obs. XL.

*Remarks.*—This is the only specimen of melanic cancer which I have ever had an opportunity of examining in the human subject. It evidently contains large cancer cells, in which black pigmentary matter has been accumulated. Structurally, the pigment is composed of exceedingly minute molecules, so minute that they readily pass through membranous walls by endosmosis, and hence their accumulation within cells. Occasionally they become aggregated together in dense masses, without any traces of organic structure. The so-called malignancy of melanic cancer is not owing to the colouring matter, but to the power of cell development in the growth. In this

respect it in no way differs from other forms of cancer. I shall speak more at length of the pigmentary matter in the second part of the work.

## OBSERVATION XLI.

## CANCROID OF LIP—EXCISION—CURE.

DUNCAN GRANT, æt. sixty-two, admitted into the Royal Infirmary, December 13, 1847, under Mr Syme. He states that about five years ago, in consequence, as he supposes, of the irritation of the pipe, a small lump formed at the right side of his lower lip. This has continued to increase slowly ever since. He has had caustic applied several times without benefit. Mr Syme at once removed the growth by a V incision. He was dismissed on the 19th of December, cured, the incision having every where healed by the first intention.

*Description of the Tumour.*—The portion of substance removed was in the shape of a V, in the expanded part of which was an indurated tumour, the size of a large cherry. Externally, it was incrustated with a light greenish scale of horny hardness, cracked in one or more places, from which a slight purulent-looking matter could be pressed. On being bisected, its substance was composed of two structures, passing gradually into each other,—a central greyish soft substance, closely resembling encephaloma, and a cortical indurated white substance, more than the eighth of an inch in thickness, grating under the knife, and exactly like scirrhus. No juice could be squeezed from its surface.

*Microscopic Examination.*—The purulent-looking matter squeezed from the surface of the tumour, contained several flat epidermic scales, which turned on their edges, and, closely aggregated together, gave a fibrous appearance to masses of them. Between these there floated numerous nucleated corpuscles, which closely resembled pus, being round in form, varying in size from the 1-100th

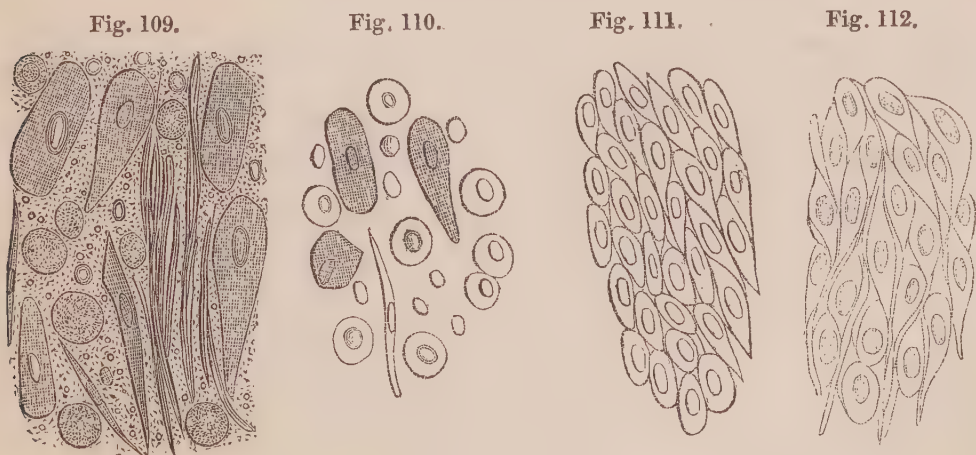


Fig. 109. Epithelial and fibro-plastic cells from surface of ulcer, described Obs. XLI. Fig. 110. The same after the addition of acetic acid. Fig. 111. Appearance of a thin section in the substance of the growth. Fig. 112. The same after the addition of acetic acid.

to the 1-80th of a millimetre in diameter, with a finely granular surface, through which a dim nucleus was observable—(Fig. 109). On the addition of acetic acid, the epidermic scales became slightly more transparent, but were otherwise unchanged. The walls of the corpuscles were partially dissolved, and round transparent nuclei, strongly refracting light, were brought into view, about the 1-200th of a millimetre in diameter—(Fig. 110).

On making a thin section of the tumour with Valentin's knife, the central greyish soft portion was seen to be composed of broad muscular fasciculi, which were unusually transparent, and readily broken up into fragments. The indurated white cortical substance was composed of spindle-shaped cells, of tolerably uniform size, closely fitted into each other. They each contained a round or oval nucleus, varying in size from the 1-150th to the 1-80th of a millimetre in diameter, and were connected together in some places by filamentous tissue—(Fig. 111). On adding acetic acid to the section, the whole was rendered more transparent. The cell-walls became very transparent, and the nuclei more distinct. The relative position between these and the filamentous substance was at the same time rendered very apparent—(Fig. 112).

*Remarks.*—The disease in this case presented all the characters of cancer to the naked eye, consisting of a scirrhous tumour composed of white carcinomatous-looking matter externally, with grey encephaloid matter internally. A microscopic examination showed that the latter was altered muscular tissue, and that the former was an hypertrophy of the epidermis. The epidermic alteration consisted externally of numerous large epidermic scales, mixed with fusiform corpuscles, and a number of round cells with round nuclei, such as are frequently found in certain fibrous growths, and therefore called by Lebert *fibro-plastic*. I have seen exactly similar cells mingled with loose filamentous tissue in polypi removed from the mucous membrane of the nose, and have no doubt that they are connected with the fibrous element. I have never seen such cells in truly cancerous growths, and from the observations of Lebert, as well as my own, think them common in epidermic and epithelial tumours. A section of the white indurated matter showed a tissue of young epidermic cells compressed together, which, on the addition of acetic acid, exhibited filaments binding them together.

An examination of the figures representing the structure of this peculiar growth, must satisfy any one who has read the preceding Observations, that it differs widely from those previously examined; and here it is of importance to remark, that the experience of surgeons has decided that so-called cancers in the lip are much less liable to return than when situated elsewhere.

## OBSERVATION XLII.

## CANCROID OF THE LIP—EXCISION—CURE.

ALEXANDER THOM, æt. fifty-six, of healthy constitution, had been troubled for about two years with sores on his lower lip, toward the angle of the mouth, on each side. He attributed these sores to constantly smoking a short tobacco-pipe. He applied to Mr Spence on the 18th of December 1847, who found both sores painful to the touch, with hard everted edges, and considerable induration of the lip for some distance around the sores. The affected parts were at once excised, and a week afterwards the wounds had completely healed by the first intention.

*Description of the tumours.*—One tumour was as large as a cherry, the other the size of a large pea. They had both round concave ulcers on their surface, the base covered with a yellowish matter of cheesy consistence, and the edges hard and everted. On section, the surface presented an indurated white cortical part, as in Obs. XLI., and a central pink or muscular portion.

*Microscopic Examination.*—On examining the softened substance covering the ulcers, it was found to consist of epidermic scales, much enlarged, isolated and in groups. They varied greatly in form, being round, oval, or elongated in shape. Their general size was about the 1-30th of a millimetre in their longest diameter. Some were as small as the 1-50th, and a few as large as the 1-10th of a millimetre in diameter—(Fig. 113). One of the latter with two enlarged nuclei is seen Fig. 114. The nucleus in many of these epidermic cells contained several oil granules; some were greatly enlarged, and crowded with these granules—(Fig. 114). Between the epidermic cells were innumerable molecules and granules, with numerous round and oval corpuscles, about the 1-200th of a millimetre in their long diameter. They underwent no change on the addition of acetic acid, and were evidently free nuclei, and such as existed within cells in the last Observation—(Fig. 110).

Fig. 113.

Fig. 114.

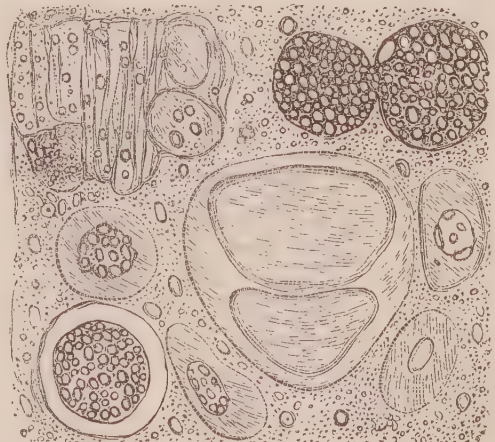
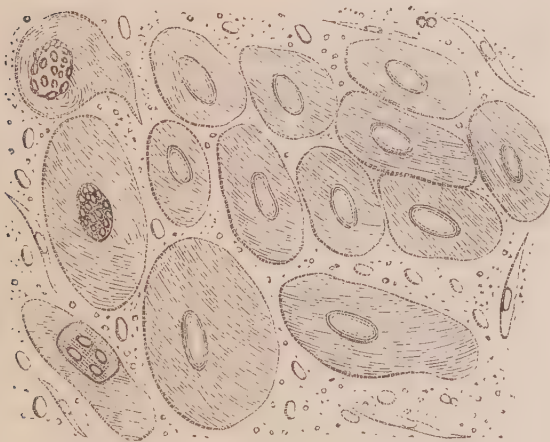


Fig. 113. Epidermic cells from the edge of the ulcers, described Obs. XLII. Fig. 114. Other cells from the central softened portion.

*Remarks.*—This case was precisely similar to the last, with this exception, that the ulceration and softening process had proceeded further. In consequence of this, the epidermic cells were greatly swollen out by endosmosis, and their disintegration had commenced by the formation of fatty granules, and their accumulation within the nuclei. These latter were greatly enlarged, and encroached upon the cell structure. The fibro-plastic bodies also observed intact in the last Observation, had in this one become universally broken down, leaving nothing but their comparatively hard and persistent nuclei behind.

I have examined numerous other specimens of so-called cancer of the lip; but have never observed any other kind of structure than that described in the two preceding Observations. Two other cases illustrative of this form of cancroïd growth are given, Obs. LV., LVI.

The next case occurred in the practice of Mr Norman of Bath, and I am indebted to Dr Davies of that city for the following particulars of it.

#### OBSERVATION XLIII.

##### CANCROID TUMOUR OF THE LEG—AMPUTATION—RECOVERY.

A young woman, about twenty-five years of age, delicately formed, and of small stature, with limbs somewhat bent in consequence of imperfect ossification when young; her general health had been tolerably good, though far from robust; she had been subject to frequent but irregular attacks of intense headach, with intolerance of light and sound, generally lasting for two or three days, and then terminating rather suddenly, uninfluenced by any particular kind of treatment, and unconnected with any irregularity of the menstrual discharge, or any disturbance of the alimentary canal.

About thirteen months before the limb was amputated, there appeared a small puffy swelling on the inner side of the gastrocnemius muscle of the left leg; the tumour continued for several months to increase very slowly, and gave very little inconvenience. About six weeks before the operation the tumour was the size of a hen's egg, and yielded to the touch an indistinct sense of fluctuation, so as to induce Mr Norman to consider it as a collection of matter situated beneath the fascia. A small puncture was made, but nothing flowed out except a little blood. The opening healed kindly; but, shortly thereafter, an erysipelatous blush spread over the limb below the seat of puncture, which point subsequently became involved, re-opened, and gave issue to a little bloody discharge; the skin sloughed, and a dark-looking fungous mass protruded. Part of this mass sloughed off (some of which was the first specimen I sent you), which was followed by a considerable oozing of blood. From this time the tumour increased very rapidly, thrust its foul bleeding surface beyond the level of the sound integuments, and at the end



of a week from the time the first portion sloughed off, the limb was amputated above the knee by Mr Norman. The stump healed rapidly and perfectly; and the patient is at the present time (Jan. 8, 1848) in as good health as she has ever enjoyed.

The appearances presented on making a section of the limb including the tumour, were as follows:—Externally there was a layer of dark-coloured matter, hard and glazed, about an eighth of an inch in thickness, obviously coagulated blood. Then came a mass of white, or rather pinkish-white, brain-like looking matter, intersected in various parts with streaks of blood. Internal to this mass, in one half of the section, there was a quantity of healthy pus separating it from the muscle; in the other half, it lay in contact with the muscle. The tumour was the size of an ordinary orange.

The muscular structure in which the tumour was situated, appeared paler than the other muscles in the neighbourhood. This paleness extended upwards and downwards for some distance in the course of the muscular fibres, but did not cross the nearest intermuscular septum.

The case has gone on well since amputation.

On the 15th of March, Dr Davies informs me that the patient still continues in good health,—better, indeed, than she had enjoyed for some time previous to the removal of her leg. Since the general wound of the stump healed, there have been a few pustules, or small abscesses, appearing on the face of the stump from time to time; but when they have discharged their matter they heal kindly, and produce no other ill effect than slight annoyance.

The portion of the tumour first sent to me for examination, was contained in a bottle of spirit, and its structure, therefore, could not be determined. The second portion was fresh, and consisted of a soft, pulpy, cream-looking mass, about an inch square, readily breaking down under the fingers. I exhibited it to Drs Alison and Duncan, both of whom pronounced it to be part of a cerebriform tumour, to which it bore the closest resemblance.

*Microscopic Examination.*—A small portion of the soft, pulpy matter, simply

Fig. 115.

Fig. 116.

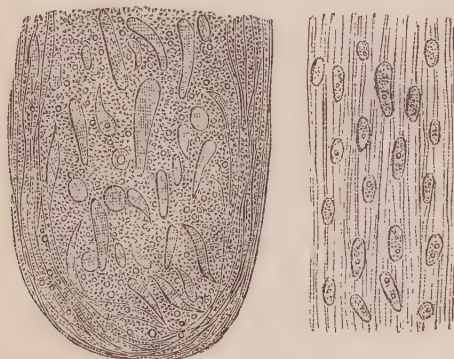


Fig. 115. Naked nuclei and fusiform corpuscles from the tumour, described Obs. XLIII. Fig. 116. A portion of the same treated with acetic acid.

squeezed between glasses, was seen, under the microscope, to consist of fusiform corpuscles in different stages of development, mingled with naked nuclei, a

multitude of molecules and granules, and a few blood globules—(Fig. 115). Some corpuscles were of oval form, others elongated and caudate, others truncated at one end, or spindle-shaped. None exceeded the 1-200th of a millimetre in breadth; and in length they varied from the 1-100th to the 1-25th of a millimetre. Several contained a minute granule, about the 1-500th of a millimetre in diameter. On the addition of acetic acid, most of the loose molecules and granules were dissolved, and a faintly fibrous structure produced, in which oval bodies were scattered, varying, in their longest diameter, from the 1-100th to the 1-50th of a millimetre.

*Remarks.*—Although the local lesion in this case was considered by all who saw it to be cancerous, there were none of the cells we have seen to be present in undoubted cancerous growths, and no kind of structure which, in accordance with our present views, could be supposed to have the power of self-development. The whole consisted of an imperfect fibrous material, composed of fusiform corpuscles, more or less broken down, which had apparently arisen either in a quantity of coagulated exudation, or in the clot following a hemorrhage. The former is the more probable, as we are told that the tumour, small at first, gradually increased in size, which it could only have done from fresh additions of exudation.

The facts of this very singular case can only be properly appreciated by comparing them with others previously recorded. And especially with Obs. XXI., XXII., XXIII., XXXIV., in all which, conjoined with a fibrous matrix, were naked nuclei. In the present Observation we have a similar structure, but evidently in a state of disintegration, so that instead of resembling hard cancer (scirrhus) it appeared to the naked eye exactly like soft cancer (encephaloma.) These five Observations, I think, exhibit a series of changes highly illustrative of a peculiar form of cancroid growth.

#### OBSERVATION XLIV.

##### CANCEROUS TUMOURS ON THE FINGER AND TOE—AMPUTATION—RECOVERY.

JOHN ALLIS, æt. fifty, labourer from Dunfermline, admitted into the Royal Infirmary, May 22, 1848, under Mr Miller. His general health has always been good. About three months ago the great toe of his right foot received a slight injury from a stone. A small piece of the nail on the outer surface of the toe was broken off. At this time he wore a pair of tight shoes, which squeezed the toe. Soon afterwards he noticed a small growth in the situation where the toe-nail had been injured. It grew from the outer corner of the great toe. He showed it to a medical man, who touched it with blue

stone. This, however, produced no effect, and the growth has proceeded in spite of the repeated applications of blue stone, nitrate of silver, and caustic potash. There has in general been considerable bleeding after these applications; at other times the bleeding has occurred spontaneously. He has in consequence lost a good deal of blood, which has greatly reduced his strength. About a month after this growth appeared in the toe, he received a slight injury from a stone on the extremity of the little finger of the left hand. This was speedily followed by the appearance of a growth similar to that which had formed on the toe. It has not bled, however, nearly so much. During the last fortnight, the tumour of the toe has increased in size very rapidly.

On admission, complexion rather pale; some emaciation. A tumour about the size of a small orange is found to be growing from the distal phalanx of the great toe of the right foot. The tumour is of a dark, almost black, colour, and presents somewhat of a fungating or cauliflower appearance. He does not feel much pain in it; it very readily bleeds. From the distal phalanx of the little finger of the left hand a tumour, about half the size of the other, is found growing. It has not the dark colour of the other, but presents the same fungous appearance.

24th. The finger and toe were amputated to-day. A little purulent matter formed subsequently in the wounds, which are reported on the 21st day of June as now healed. General health has improved within the last fortnight, and the patient was dismissed "cured" next day.

*Description of the Tumours removed.*—The extremity of the great toe removed was expanded into a tumour approaching the globular form, and the size of a small orange. The greatest diameter measured three inches across. Externally one-half of its surface was covered with a hard blackish slough. On making a section through it, its structure was observed to be soft and pulpy, generally of cream colour; but here and there considerable masses of blood had been extravasated into its substance. Small plates and spicula of bone were imbedded in its circumference, owing apparently to expansion, and breaking down of the external bony lamina of the phalanx. The swelling of the finger presented on section exactly the same appearance, but it was only the size of a walnut.

*Microscopic Examination.*—On examining a little of the pulpy matter of the tumour, it was seen to contain numerous cancer cells varying greatly in size, some being so small as 1-50th of a millimetre in diameter, and others so large as to measure only 1-10th of a millimetre across. The former were furnished with one or two oval or round nuclei, which resisted the action of acetic acid. The latter were round or oval, and some had a short caudal appendage—(Fig. 117). They contained included cells and nuclei, varying in number from three to seven. One cell seen in the figure contained a group of transparent vesicles. These cells more closely resembled those observed in Obs. XXVII. than any others previously alluded to. They had distinct external walls.

Fig. 117.

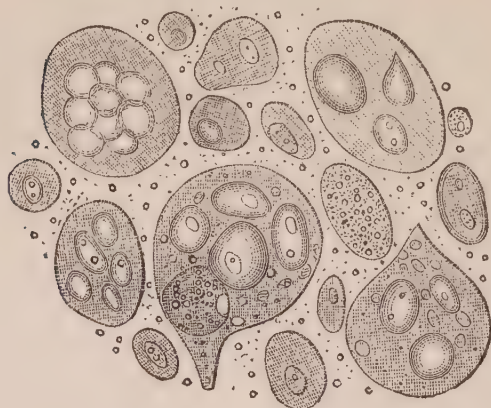


Fig. 117. Simple and compound cancer cells from the tumour of the toe, described Obs. XLIV.

*Remarks.*—In this Observation, we have another opportunity of examining true cancer in its furthest stage of development. The cells had reached a large size, and included within them several others. Such a degree of development seems to occur most readily when the situation of the lesion allows of free expansion, and room for growth. This does not invariably take place in bone, as will be seen from the following Observation.

#### OBSERVATION XLV.

CANCER OF STERNUM, RIBS, AND LEFT MAMMA—CHRONIC ULCER OF STOMACH—CRETA-  
CEOUS CONCRETIONS IN MESENTERIC GLANDS—CYSTITIS—DEATH.

CHRISTINA WALKER, æt. sixty-four, was admitted into the Royal Infirmary, July 3, 1844, under Dr Paterson—complaining of general pains and vomiting. Shortly afterwards a prominence of the sternum was observed, unattended with pulsation below. Sounds of the heart were normal. The left mamma also presented an indurated swelling, which gave rise occasionally to lancinating pains. Towards the latter end of September, the prominence of the sternum had considerably increased, the mammary tumour was as large as an orange, and ulcerated on the surface, discharging a foetid sanies. The fat and inferior extremities also became cold and livid. On the 28th of September she was seized with acute pain in the region of the bladder, accompanied by strangury and great distension of the organ. From this time a catheter was used three or four times daily, whereby a quantity of ammoniacal bloody urine was drawn off. She died October 4, having been comatose the last three days of her life.

*Sectio Cadaveris*, October 7. Body greatly emaciated.

*Head* not examined.

*Chest.*—The chest was much deformed owing to the existence of a promi-

nence over the superior third of the sternum, and to flattening and even indentation of the ribs on both sides. On reflecting the integuments, and removing the sternum and the ribs forming the anterior walls of the thorax (which were sawed far back for this purpose), the bones were found to be cancerous in several places. The sternum throughout its whole extent was thickened and soft, the knife readily sinking into it, and yielding on pressure a thick creamy fluid. About the middle, it was an inch and a half in thickness, and at its two extremities three quarters of an inch thick, on section presenting a granular tolerably uniform surface, with few traces of osseous substance, which was replaced by a soft, whitish cancerous matter. Several of the ribs presented small tumours about the size of a hazel-nut or walnut, formed of the same material. In the fifth rib especially, on both sides, was a tumour of the latter size, about three inches from the vertebral column. The osseous matter of the third, fourth, fifth, and sixth ribs anteriorly, half an inch from the sternal cartilages, was absorbed, and only held together by a ligamentous substance. It was here the greatest flattening of the chest was observable. All the bones of the ribs were remarkably brittle, and readily cut through by the knife. In the left mamma was a tumour the size of an orange, nodulated on the surface, not connected to the bone. On section, it presented all the appearances of medullary cancer, and contained several cavities filled with grumous blood. The glands in the left axilla were greatly enlarged, and infiltrated with cancerous matter.

The pleuræ were slightly adherent on both sides, by chronic bands of lymph. On being separated, the costal pleuræ were seen to be studded with minute white depositions, varying in size from a pin's head to a pea, of soft cancerous matter, situated in the sub-pleural areolar tissue.

*Lungs and Heart healthy.*

*Abdomen.*—The peritoneal surface of the diaphragm was studded, here and there, with small rounded white tumours, generally the size of peas, composed of soft cancerous matter. The stomach contained a large quantity of bile, with which the mucous membrane was deeply tinged. A round chronic ulcer, the size of a shilling, had completely perforated the posterior wall of the organ, but was blocked up by adherent omentum. The mesenteric glands were generally healthy, but here and there contained cretaceous matter. The coats of the bladder were much thickened, and the organ contained a large quantity of dirty-yellow grumous matter. In the fundus was an ulcer as large as the palm of the hand, with ragged edges, lined with greenish-yellow muco-purulent matter. The base of the ulcer was formed of the thickened peritoneal coat. The mucous membrane was destroyed, whilst the muscular bands appeared as if cleanly dissected out, and were seen stretching across the ulcer. Other organs healthy.

*Microscopic Examination.*—On examining the juice squeezed from the softened sternum, it was seen to contain transparent cancer cells, generally about the 1-50th of a millimetre, furnished with one or two nuclei. These were mingled with numerous naked nuclei, molecules, and granules—(Fig. 118). Acetic acid dissolved the cell-walls, but left the nuclei unaffected—(Fig. 119).

The juice squeezed from the tumours of the ribs presented the same appearances. In the fluid matter obtained from the cancerous mamma were observed several nuclei, apparently in a state of disintegration, mingled with a few fusiform corpuscles and numerous molecules and granules—(Fig. 120). No trace of cancer cells could be observed in the ulcer of the stomach or of the bladder. In the mesenteric glands debris of cell formations, mixed with a few fusiform corpuscles, numerous molecules, granules, and masses of mineral matter, were alone visible.

Fig. 118.

Fig. 119.

Fig. 120.



Fig. 118. Cancer cells and naked nuclei, squeezed from the sternum, described Obs. XLV. Fig. 119. The same after the addition of acetic acid. Fig. 120. Corpuscles from the mamma in the same case.

*Remarks.*—This was a very extensive case of cancerous deposition and growth, evidently affecting the bones and the mamma. The history of the case evinces that, previous to the detection of the disease in these situations, she laboured under disease of the stomach. Here it may be asked if the ulcer in that viscus detected after death was of cancerous origin? or was it a specimen of so-called chronic ulcer? If the former, every cancerous character had disappeared; if the latter, it must have commenced and ran its course independent of the predisposition to cancerous formation. On the other hand, may we consider it as a cancerous ulcer in the process of cure? This does not appear to be so improbable a supposition on taking into account that the mesenteric glands in the neighbourhood had been previously diseased, and had partly undergone the calcareous transformation. This we have seen to occur in a former Observation, (Obs. XIX.), and it appears to me likely that the disease of the stomach and mesenteric glands had a common origin, and that they were both gradually undergoing spontaneous cure, when fresh cancerous exudation was poured into the mamma and bones. In this state an acute attack of cystitis occasioned death.

## OBSERVATION XLVI.

OSTEO-MEDULLARY SARCOMA OF THE OS FEMORIS—AMPUTATION OF THE HIP-JOINT  
—RETURN OF THE DISEASE IN THE ORBIT AND STUMP—DEATH.

On the 30th of June 1843, I received from Dr Handyside a portion of a tumour growing from the os femoris of a boy, on whom he had that day performed amputation at the hip joint. The following is a condensed history of the case:—<sup>1</sup>

JOHN WRIGHT, aged thirteen, was admitted into the Royal Infirmary, June 13, 1843, under Dr Handyside. Six months ago, he was suddenly seized during the night with violent pain in the left thigh, which shortly after commenced to enlarge, and has gone on increasing up to the time of admission. On examination the thigh was found to be much enlarged, especially at its middle, whence it tapered gradually towards each extremity. The tumour was hard and inelastic, connected evidently with the os femoris, and occupied about three middle-fifths of that bone, having its extremities about the normal size. Its surface was smooth and regular, and over it the muscles and other soft parts could be moved freely. The integument covering it presented a somewhat glistening appearance, but was not discoloured. The tumour was the seat of acute darting pain, which became increased towards night, and underwent occasionally severe exacerbations.

On the 30th of June Dr Handyside performed amputation at the hip-joint, by the double flap operation. After the removal of the limb, a small portion of the tumour was observed to remain on the posterior flap, which was carefully and completely removed. Fifteen vessels in all required ligature. About six ounces only of blood were lost. The patient bore the operation well: but symptoms of the shock exhibited themselves before he left the table, although  $\zeta$ iv of brandy and  $\zeta$ ij of wine were administered. He was replaced in bed fifteen minutes after leaving it, the removal of the limb having occupied about one-third of a minute.

The patient remained in the hospital till the 5th of August, during which time every thing advanced favourably. His general health and appetite improved daily, and during the last ten days he had occasional airing in the grounds. Some ligatures still remained attached, from around which there was a moderate discharge; the stump itself was firm and free from pain. After leaving the Infirmary he resided in the neighbourhood of Edinburgh, and soon afterwards he complained of pain in the left orbit and eyeball. About the middle of August a small chronic abscess formed over the occiput. Towards the beginning of September the pain in the orbit diminished, and he took exercise on crutches in the open air daily, using also the stump freely by sitting on it. On the 11th of September he returned home to his friends in Stirlingshire, four of the ligatures still adhering.

About the end of September the pain in the left frontal and orbital regions

<sup>1</sup> Monthly Journal of Medical Science, April 1845.

became so severe as to oblige him to remain in the house. The eyeball was now prominent, and there was considerable tumefaction of the eyelids. One ligature now only remained, but a mass of œdematous granulations surrounded it, which were free from pain. Towards the end of October the eyeball was very prominent and discoloured, with almost complete loss of vision. The eyelids were so much tumefied as almost to conceal the eyeball, and the veins of the eyelids were very conspicuous, being enlarged and tortuous. The orbit was the seat of continual stinging pain, which prevented sleep, and was fast undermining his strength. Three chronic abscesses were situated over various parts of the head. There was a tumour of the size of an egg on the left hypochondrium, which was firmly adherent to, and connected with the cartilages of the upper false ribs. It was slightly elastic to the feel, had grown rapidly, and was the seat of acute darting pains. In the stump, where the last ligature had passed out, a small, pale-coloured fungus protruded. The patient was much emaciated, and his strength worn down by the continued pain and hectic. He expired on the 11th of November, four months and a half after the operation. No examination of the body could be obtained.

*Dissection of the Amputated Limb.*—On the muscles and other soft parts which lay over the bone and tumour being dissected off, it was seen to be of an oval form, nodulated on the surface, and measuring about four inches at its widest portion, which was around the centre of the femur, gradually tapering towards the extremity. On section the shaft of the bone was seen to be entire, except near its middle, where it appears as if compressed by the tumour. At this point the medullary canal was filled up with apparently new osseous deposit, of a more soft consistence than usual. The spongy substance at both extremities of the bone was infiltrated with the sarcomatous substance which constituted the bulk of the tumour. This was situated between the bone and periosteum, which membrane extended over it. It appeared to consist of a mixture of the osteo-sarcoma and of the fibro-medullary formations, there being distinct radiating bands between the surface of the bone and the periosteal covering of the tumour. Some of these striæ were osteo-cartilaginous, and others fibrous, and in their interstices were deposited the sarcomatous and encephalomatous substances.

*Microscopic Examination.*—The portion of structure I received for examination was composed of muscle removed from the cut surface of the limb. It was pale and somewhat gelatinous. Under the microscope the fasciculi were observed to be pale, and easily separable from each other. They exhibited an unusual disposition to crack across, and no transverse striæ could be observed, each fasciculus being converted into a finely molecular substance. Between the fasciculi, and in the fluid squeezed out by the pressure of the glasses, there existed a multitude of molecules and granules, with numerous colourless cells of round form, finely granular surface, and generally measuring about the 1-75th of a millimetre in diameter—(Fig. 121.) On the addition of acetic acid, some of these cells seemed to be partly, and others wholly dissolved, and exhibited



round and oval nuclei, about the 1-200th of a millimetre in diameter, with dark borders—(Fig. 121 *a*). Some nuclei were set free by the entire disappearance of the cell-wall.

Fig. 121.

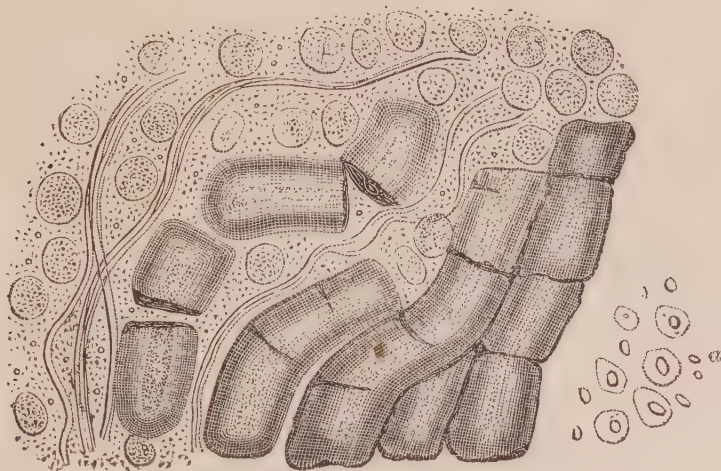


Fig. 121. Muscular fasciculi and cells from the neighbourhood of the tumour, described Obs. XLVI.

*Remarks.*—I had no opportunity of examining the substance of the tumour, and have recorded the case with a view of exhibiting the alteration which took place in the surrounding muscles. This was of two kinds:—1st, The change occurring in the muscular fasciculi as the result of pressure, causing obliteration of the transverse striæ, friability and a readiness to break across, and commencing fatty degeneration; 2d, The presence of a multitude of colourless cells, the nature of which is not very clear. Are they incipient cancer cells? If so, the return of the disease can be easily understood when it is remembered, that the knife went through muscles every where infiltrated with them.

#### OBSERVATION XLVII.

CANCROID TUMOUR (MEDULLARY-SARCOMA) OF HUMERUS—AMPUTATION AT THE SHOULDER JOINT—DEATH.

ALEXANDER YOUNG, æt. thirty-one years, occupation a shepherd, was admitted into the Royal Infirmary of Aberdeen, February 18, 1848, under the care of Dr Keith. He is a strong healthy-looking man, of florid complexion, and states that seventeen years ago he was bitten by a horse in the left arm, which merely caused a slight bruise and abrasion of the surface, from which he speedily recovered. In June last, he felt what he describes to be rheumatic pains in the left shoulder, which were often so painful as to prevent his lying on that side. In about six weeks the pain shifted to the anterior and middle part of the humerus of the same side (leaving the shoulder altogether), and on the same spot where he was

seized by the horse seventeen years previously. This pain was of a peculiarly severe and lancinating character, and extended down the arm to the thumb and two adjacent fingers. In September last, he first perceived a swelling commencing, which gradually increased until last Christmas, since which time its progress has been more rapid. Its circumference is now six inches greater than that of the right arm. The skin investing the tumour is natural. It feels semi-solid and elastic; is of an irregular form. No fluctuation can be detected. The integument is moveable on the tumour, and large veins are seen coursing beneath it. It feels slightly adherent to the bone on the anterior and inner side. He does not complain of any fixed pain in it, and his health and spirits are both good.

*March 11,* To-day his arm was amputated at the shoulder-joint. He was placed under the influence of chloroform, and evinced no symptom of pain.

On examining the tumour after removal, it was found to have no attachment to the bone, being developed in the soft tissues on the anterior and inner side of the arm, at about the junction of the middle with its upper third; from the lower end of the tumour a tail-like process extended downwards along the sheath of the vessels as far as the bend of the elbow; at the same time implicating the median nerve, so that it presented an enlarged and gelatinous appearance, even to its minute terminations. Internally the tumour presented very much the usual appearance of medullary sarcoma, being of a whitish opaque substance, of the colour and consistence of brain, and having a small quantity of decomposed coagulated blood in cavities which were filled with straw-coloured serum.

On his being put to bed after the operation, a quantity of blood was found to be oozing out at the edges of the wound, for which the wound was opened, and a few muscular twigs were secured.

The case went on most favourably until the 19th of March, when a round mass, the size of a nutmeg, appeared at the inferior angle of the wound, which superficially appeared partly muscular, and partly covered with dirty lymph. On the 20th a ligature was tied round it, as high up towards the pectoral muscle as possible. On the 21st the ligature was tightened, and the inclosed structure seemed very dense. The protruding tumour was now the size of an egg, and as it prevented closure of the lips of the wound, it was sliced off, leaving exposed apparently healthy muscular structure. A few days subsequently another mass protruded, which was kept down by chloride of zinc. The wound was flabby and lifeless, the patient dispirited and nervous, and now he fell into a cachectic state, and sunk on the 1st of April.

On examining the body no appearance of medullary disease was detected any where. In the lungs several points of purulent deposit were observed, without any evidence of inflammatory action in the neighbouring tissues sufficient to account for their presence.

*Microscopic Examination.*—A small portion of the tumour only was sent to me for examination, which was of pulpy consistence generally, but firmer at one part. It was of yellowish-white colour, smooth on the surface, did not yield a milky juice on pressure, and resembled specimens of so-called medullary-sar-

coma. Two portions of the median nerve, one cut from above, and the other from below the tumour, accompanied it.

On examining a thin section of the tumour, at the densest part of the piece sent, it was seen to consist of numerous bodies of oval form, containing one, two, or more granules, infiltrated among a fibrous stroma—(Fig. 122). In the softer part of the structure these bodies were isolated, and accompanied by numerous molecules and granules, and several fusiform corpuscles—(Fig. 123). On adding acetic acid the fibrous structure became more transparent, but the oval bodies underwent no change—(Fig. 124). The median nerve taken from above the tumour was perfectly healthy, presenting the usual appearance of nerve tubes, somewhat collapsed, and their contents coagulated from long keeping. The nerve below the tumour, however, although to the naked eye white and of healthy appearance, contained no trace of tubular structure. The whole was converted into fibres, between which numerous oil granules, granular masses, and compound granular cells had formed—(Fig. 125).

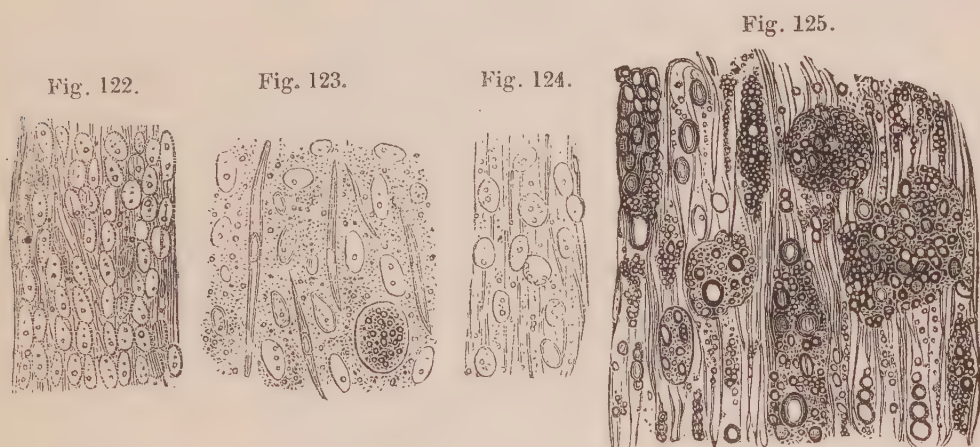


Fig. 122. Naked nuclei in a fibrous stroma from the tumour, described Obs. XLVIII. Fig. 123. Structures seen in the softer part of the same tumour. Fig. 124. The same after the addition of acetic acid. Fig. 125. Structure of the median nerve taken from below the tumour.

*Remarks.*—The oval bodies observed in the tumour were evidently naked nuclei, but whether these were a primary growth, or the result of disintegration, it is difficult from the facts ascertained to say. In several Observations previously detailed, similar bodies were observed, generally associated with the fibrous element, and destitute of all formation. In most of these the morbid growth was hard, and apparently advancing. In one, however (Observation XLIII.), the structure, as in the present case, was softened, pulpy, and apparently in a state of disintegration, and it is difficult to say whether in either, cells had previously existed, more especially as I had only an opportunity of examining one portion of the morbid growth.

In this case the man seems to have sunk from the depressing effects of the operation, as the disease had not returned previous to

death, nor was it found to exist in any other tissue afterwards; but in another, and somewhat similar case of medullary-sarcoma in the humerus, which I examined with great care, I found the softer parts to consist of naked nuclei, mingled with numerous molecules and granules, and a faint fibrous stroma. Here and there, however, I could detect a transparent cell-wall surrounding them, as in Fig. 63, and some such cells had even commenced to undergo the fatty degeneration. The more solid portion of the tumour was composed of fibrous tissue, which, on the addition of acetic acid, displayed elongated nuclei, as in Fig. 57. The bony spiculæ, found here and there, consisted of thin plates of bone, with large and irregular loculi perforating them. The surrounding muscles had undergone the fatty degeneration, and readily cracked across, as in Fig. 121. In this case, which also occurred to Dr Keith, he tells me that the patient, a young girl, *æt.* ten, underwent amputation at the shoulder-joint; that the wound healed readily; but, three months afterwards, the disease returned in the cicatrix, which presented a tumour the size of a pigeon's egg. Thirteen days after, a soft pulpy tumour appeared in the occiput, which increased until her death, two months afterwards. On dissection, medullary tumours were found surrounding the glenoid cavity, attached to the occipital bone externally, and causing caries in it, and also between that bone and the dura mater.

## OBSERVATION XLVIII.

## CANCROID TUMOUR (ENCHONDROMA) OF THE HUMERUS—AMPUTATION AT THE SHOULDER-JOINT—CURE.

CHRISTINA FERRIER, *æt.* fourteen, was admitted into the Royal Infirmary, June 10, 1847, under Mr Syme. About six months ago she felt a slight pain on the outer side of the upper third of the left humerus, which gradually became worse, and in the morning for about three hours was intolerable. During the day she had scarcely any pain. A month afterwards she first noticed a small round lump immediately below the seat of pain. A surgeon then applied three blisters, which rendered the symptoms worse. The tumour has gone on gradually increasing ever since. On admission a large tumour is seen bulging out under the belly of the deltoid muscle, the arm being slightly atrophied, and the hand generally cold. It is of oval form, apparently four inches in its thickest diameter, and tapers away towards each extremity. It has an elastic feel, and is firmly fixed in its position.

On the 16th of June Mr Syme performed amputation at the shoulder-joint,

according to the mode proposed by Lisfranc. The flaps rapidly united by the first intention, and she was discharged cured on the 17th of July.

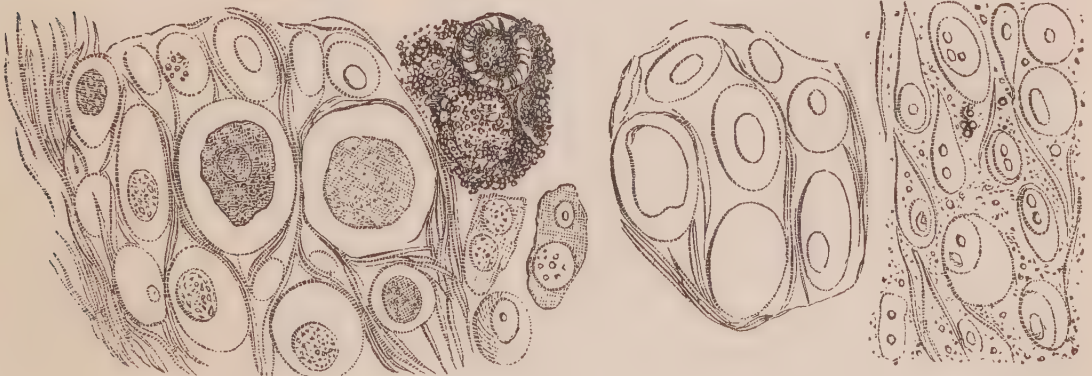*Description of the Tumour.*—The tumour occupied the middle of the humerus, was of a spindle form, about four inches thick in the centre, tapering towards the two extremities. When I first saw it, the soft parts had been carefully dissected from its surface, so that of their condition I can say nothing. The surface of the tumour was nodulated, and it was found that, while some were hard and of cartilaginous texture, others were soft and pulpy, readily breaking down under the fingers. As the specimen was preserved entire for the University Museum, my examination was limited to ascertaining these facts, and removing thin sections from an indurated and softened nodule for more minute examination. The bone was afterwards macerated, and now presents a beautiful specimen of irregular bony plates and spiculæ, standing out in large numbers from the shaft.

*Microscopic Examination.*—On making a thin section of one of the hard nodules with Valentin's knife, it was seen to be composed of nucleated cells, imbedded in a transparant blastema, which, however, was partly fibrous. The cells varied greatly in size, some being as small as the 1-100th, and others as large as the 1-25th of a millimetre in diameter. They were round or oval in form, and some more or less compressed from contiguous pressure. They were all nucleated, some containing one, and others two nuclei. They varied in size as much as the cells, some being as small as the 1-200th, and others as large as the 1-30th of a millimetre in diameter. Some were finely granular throughout, others contained from one to four nucleoli. In some of the sections with the double knife, small collections of earthy matter were cut through, which existed in the form of minute granules surrounding the cells, and in some instances filling up their interior—(Fig. 126). In the hyaline intercellular substance, delicate filaments and numerous fusiform corpuscles constituted a fibrous mesh-work. On adding acetic acid to the section, it was rendered very transparent. The edge of the cell was still

Fig. 126.

Fig. 127.

Fig. 128.



*Structure of an enchondromatous tumour of the humerus, for which Mr Syme amputated the arm at the shoulder-joint.* Fig. 126. Section of a firm cartilaginous nodule. The right of the figure exhibits above mineral deposit in and around the cells, and below some isolated cartilage corpuscles. Fig. 127. Exhibits the effect of acetic acid, rendering the whole, and especially the nucleus, more transparent. Fig. 128. Shows the cartilage cells, and fibrous tissue, isolated, broken up, and mixed with numerous molecules, in a nodule of soft and almost diffuent consistence.

very perceptible, and the nucleus was rendered singularly pale, so that nothing but its outline was discernible—(Fig. 127).

On examining a portion of a softened nodule, it was seen to consist of numerous isolated cells and nuclei, similar to those just described, floating in a fluid containing innumerable molecules and granules, with some fusiform corpuscles, and fragments of filaments—(Fig. 128).

*Remarks.*—That cartilaginous tumours soften and break down into a pulp, and under such circumstances closely resemble a cancerous growth, is a fact of considerable importance. True cancer of bone, as in Obs. XLIV., so-called medullary-sarcoma, as in Obs. XLVIII., and enchondroma, as in the present case, so closely resemble each other to the naked eye, that they have always been confounded together. Whether their separation, by means of a microscopic examination, will be attended with any useful results, can only be determined by future observations.

#### OBSERVATION XLIX.

CANCROID TUMOUR (ENCHONDROMA) OF THE ISCHIUM AND PUBIS—VEGETATIONS ON THE MARGIN OF THE AORTIC VALVES—DEATH.

DANIEL MAITLAND, æt. forty-five, a wood-turner, admitted December 7th into the Royal Infirmary, under Dr Robertson. Body emaciated. Has always been healthy until about four months, but since then has been troubled with an aching in the loins and hips, extending down to his knees; it is worse in the left hip, and always aggravated at night. About the same time he perceived a painful swelling in the perineum about the size of a nut; it continued to enlarge till about five weeks ago, when leeches and poultices were applied, and he took iodine. Under this treatment the swelling and pain were considerably diminished. Since then, however, it has been gradually growing larger, and is now about the size of an orange, hard, inelastic, and immoveable, and lying on the ramus of the left ischium and pubis. Within the last fortnight has had acute pain in his right elbow and forearm; it is not increased by pressure, and there is no redness or swelling of the joint, or enlargement of the bones. Complains of occasional darting pains in his neck and shoulder.

Soon after this he was dismissed, but was re-admitted on January 2, 1848, when the tumour is reported to have increased in size, and the lymphatic glands in both groins to have become affected, and he gradually sunk and died January 12, 1848.

*Sectio Cadaveris, January 14th.*

*Head* not examined.

*Thorax.*—Pericardium contained ʒii of turbid yellow serum. The aortic valves were not quite competent, and on their free margin were situated several small

masses of vegetations. Slight chronic adhesions existed between the pleuræ on the left side.

*Abdomen.*—All its organs were healthy. The bladder was strongly contracted. The lumbar and mesenteric glands perfectly healthy. Inguinal glands on left side somewhat indurated and enlarged.

In the groin and perineum, on the left side, there appeared externally a large tumour about the size of a cocoa nut. The scrotum contained only the right testicle. On dissection this tumour was found to be situated below the fascia and muscles, and firmly attached to, and intimately connected with, the front of the left os pubis, and the ascending ramus of the ischium. No trace could be found of the left testicle. On cutting into the tumour, it was seen to be of soft creamy consistence, presenting the ordinary appearance of degenerated encephaloid matter. At one place the softening was more complete than elsewhere, and of a florid red colour from admixture of blood. On making a complete section of the morbid growth with a saw, it was seen to be surrounded by a shell of bone, evidently caused by the expansion of the external lamina of the pubic and ischiac bones. The tumour became more and more soft towards the centre, where in several places it was altogether diffuent. Thin spiculæ and laminae of bone existed every where in its substance, but were most abundant towards the circumference.

*Microscopic Examination.*—On making a thin section of the circumference of the tumour with a Valentin's knife, the appearance was observed represented Fig. 129, consisting externally of a shell of bone, presenting the characteristic structure of that tissue, which internally gradually passed into cartilage. The cartilage cells were round or oval, occasionally spindle-shaped, and varied from the 1-50th to the 1-25th of a millimetre in their longest diameter. Some possessed a distinct oval or round nucleus with one or more nucleoli; others contained from one to three granules in the situation of the nucleus, and a few were filled

Fig. 129.

Fig. 130.

Fig. 131.

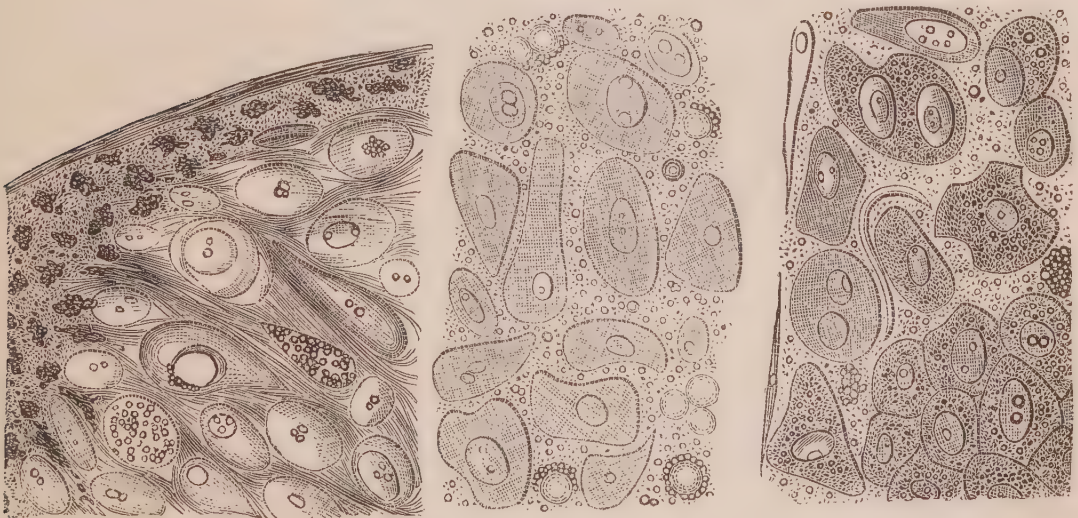


Fig. 129. Thin section of the circumference of the tumour, described Obs. XLIX. Fig. 130. Corpuscles from the softened part of the same tumour. Fig. 131. The same after the addition of acetic acid.

with granules. These cells were imbedded here and there in a perfectly hyaline blastema; more generally, however, delicate filaments surrounded them, giving to the structure more or less the appearance of fibro-cartilage.

On examining the softened pulpy matter towards the centre of the tumour, it was seen to be composed of nucleated cells, floating among molecules or granules—(Fig. 130). The cells were delicate, some round or oval, others of a somewhat triangular form, a few canted, oblong, or notched at their edges. They varied in size from the 1-50th to the 1-20th of a millimetre in their longest diameter. They contained one or two nuclei, which also varied in size, and these, in turn, contained one or two nucleoli. Floating among these cells might be observed several delicate, diaphanous round corpuscles, about the 1-100th or 1-30th of a millimetre in diameter, to several of which numerous granules were adherent externally. On adding water to these cells, they became more opaque, and their opacity was increased on the addition of acetic acid, without in any way altering the form of the cell-walls, or of the nucleus—(Fig. 131).

*Remarks.*—This tumour was considered by all who saw it to be cancerous, and a hurried examination of the softened part with a microscope seemed to confirm the opinion, the cells represented Fig. 130 looking at first like those of cancer. A more careful scrutiny, however, enabled me to detect peculiarities in their shape and appearance which threw doubts on this conclusion; and when, on the addition of water and acetic acid, instead of seeing them first enlarge, and then the cell-wall become more transparent, it was observed that no change took place in size, while the cell became more opaque, I was led to investigate the growth more narrowly. Sections with Valentin's knife soon proved that the tumour was really cartilaginous, softened in some places, and closely resembling cancer. The effect of water and acetic acid were very peculiar. It is worthy of remark, also, that neither the lumbar glands, nor any of the structures of the neighbourhood, were similarly affected, although the inguinal glands were somewhat enlarged and indurated from simple hypertrophy.

#### OBSERVATION L.

COLLOID CANCER OF OMENTUM, AND THE PERITONEUM LINING THE VARIOUS ABDOMINAL VISCERA—COMPOUND ENCYSTED COLLOID TUMOURS OF OVARIES—PERITONITIS—DEATH.

MRS K., æt. twenty-eight, had no children, consulted Mr Woodhead in October 1845, considering herself to be in a pregnant state. She thought that she had been in the family way about seven months; during which time, however, the catamenia had appeared regularly, but were scanty. There was a visible enlargement of the abdomen, but no particular examination was made. In November she



complained of pains in her back and abdomen, and passed very restless nights. These symptoms were treated by palliatives, and attributed to the spurious pains so common in advanced pregnancy. In the beginning of December an examination of the abdomen was made, which was considerably enlarged, so much so as to resemble a woman about the eighth or ninth month of utero-gestation. A distinct fluctuation was perceived, and an indurated tumour which remarkably resembled a foetal head. About the commencement of January 1846 she was examined *per vaginam*, when the *os uteri* was felt unusually high, which led to the suspicion that she was not pregnant. At this time the peritoneal fluid was much increased in amount, and the abdomen was very tense. The respiration was considerably embarrassed, and the nights rendered restless from dyspnoea. About the middle of January Dr Simpson was consulted. The following day paracentesis was performed at the umbilicus, which was unusually prominent, and a wash-hand basinful and a half of fluid was drawn off. This fluid was of a reddish colour, and contained numerous flocculi and white nodules. The former were seen on a microscopic examination to be composed of several corpuscles, both nucleated and granular, similar to those hereafter to be described, entangled together in groups by numerous filaments. There were also many blood globules. The white nodules were entirely composed of filamentous tissue, containing several fusiform corpuscles.

The breathing was much relieved by the tapping, but from this time she could not carry on her usual occupation, which she had hitherto done. The pains in the back and abdomen continued: a febrile action was excited; the pulse rose to above 100; the nights continued restless: no vomiting; and a cachectic state made its appearance. The wound did not close, but continued to discharge a reddish fluid, which afterwards became dark, often mixed with flocculi, and latterly with a quantity of jelly-like substance. About the second week in February the tumour was felt hard, unequal on the surface, and apparently attached to the parietal walls of the abdomen anteriorly. On placing the ear over the abdomen a distinct to and fro friction murmur could be heard. Fluctuation could also be felt at the lower part of the abdomen. Two other openings now took place in the umbilicus, from which a continual discharge escaped. The other symptoms continued; the pains could only be relieved by morphia, and she sunk exhausted on the morning of March 8.

*Sectio cadaveris*, March 9, eight P.M.

The body was much emaciated; head not examined.

The thoracic organs were healthy.

*Abdomen*.—On cutting through the peritoneum, about a pint of dirty yellow purulent fluid escaped. The pelvis and abdomen inferiorly were occupied by an encysted tumour, which had burst anteriorly, exposing several cysts containing an amber-coloured jelly-like matter. The peritoneum superiorly and anteriorly was united to a firm tumour underneath by gelatinous adhesions, which were easily broken through. This tumour occupied the whole breadth of the abdomen, and extended from the ensiform cartilage to midway between

the umbilicus and pubis. It varied in thickness from one to two inches, and was evidently a growth in the substance of the omentum, being attached superiorly to the stomach and transverse colon, lying over the intestines, and terminating inferiorly in a rounded edge. When removed from its attachments the tumour weighed three pounds thirteen ounces. To its anterior and posterior surface were attached numerous shreds and patches of chronic lymph. On cutting into it in various directions, it presented numerous cells, varying in size from a pin's head to that of a large pea, filled with a clear, glistening, gelatinous matter, surrounded by a firm fibrous substance or mesh-work. In some places it was of a greenish hue, in others of an ochrey or orange yellow. Here and there the meshes of the tissue were tinged of a greyish hue by black pigmentary deposits.

The peritoneal membrane lining the abdominal parietes was coated with a layer of the same colloid cancer about two lines in thickness, covered with patches and flocculi of lymph. This layer could in many places be stripped from the serous membrane below, which appeared to be healthy. Between the liver and diaphragm a mass existed half an inch thick. The spleen was surrounded by a similar layer. The lymphatic glands in the neighbourhood of the pancreas and stomach were much enlarged, and apparently quite converted into the colloid cancer. A mass surrounded the uterus more than an inch thick, circumscribing the cavity of the pelvis. The lumbar glands and *appendices epiploicæ* of the large intestines were greatly enlarged and similarly affected. On cutting into the liver, spleen, and kidneys, they were found healthy; the peritoneal membrane covering them being alone affected. The peritoneum surrounding the pyloric extremity of the stomach, and extending a third over the surface of that viscus, was upwards of an inch thick from deposit of colloid cancer. Its muscular and mucous coats were healthy. The small intestines were united together by bands of chronic lymph, of a bluish-black colour from pigmentary deposit. Anteriorly they were covered *en masse* by a layer of lymph, of greenish colour, about a line in thickness.

Both ovaries were the seat of a compound cystic tumour, that on the left side was in circumference about the size of the crown of a hat. When viewed anteriorly, it presented the appearance of a mass of trembling calves'-feet jelly, with numerous blood-vessels ramifying upon it. Shreds of the external sac were seen attached to it here and there, which had evidently sloughed, and in some places been adherent to the abdominal parietes. Posteriorly the fibrous sac was still entire, and presented numerous rounded elevations, marking out the forms of distinct cysts. On incising this mass it was found to consist of numerous cysts, the walls of which were very thin, but richly supplied with blood-vessels. They for the most part contained a trembling transparent, gelatinous substance, generally of an amber colour, but here and there of a brownish-red. Imbedded in some of this jelly, there existed opaque white masses, resembling blanc-mange, or thick cream. In other places the gelatinous matter might be observed semi-transparent, and of a light yellow colour.

The tumour of the right ovary was about the size of a small orange. In the

fibrous capsule anteriorly was a round perforation the size of a fourpenny piece, from which a similar amber-coloured jelly to that which existed on the opposite side could be squeezed. On section it was found entirely full of cysts, all filled with the same gelatinous matter.

*Microscopic Examination.*—On making a thin section of the peculiar growth on the peritoneum, it every where presented a network of transparent filaments, forming loculi of various sizes; the filaments surrounding one opening often running in those forming others—(Fig. 132). Some of these loculi contained nothing but a perfectly transparent fluid; others contained cells, generally of oval form, although a few were round or caudate. They varied in their longest diameter from the 1-50th to the 1-30th of a millimetre in length. They all contained a nucleus of oval shape, varying in its longest diameter from the 1-200th to the 1-80th of a millimetre in length. The larger of these contained an oval nucleolus. These cells occurred in groups, and many of them floated loose in the fluid squeezed from the section. Here and there numerous fat granules, and compound granular masses and corpuscles, existed in groups. On the addition of acetic acid the fibres became somewhat more transparent, the external walls of the cells were partly dissolved, while the nucleus was unaffected. The dirty yellow purulent matter was composed of broken down pus corpuscles, mixed with innumerable granules and molecules.

Fig. 132.

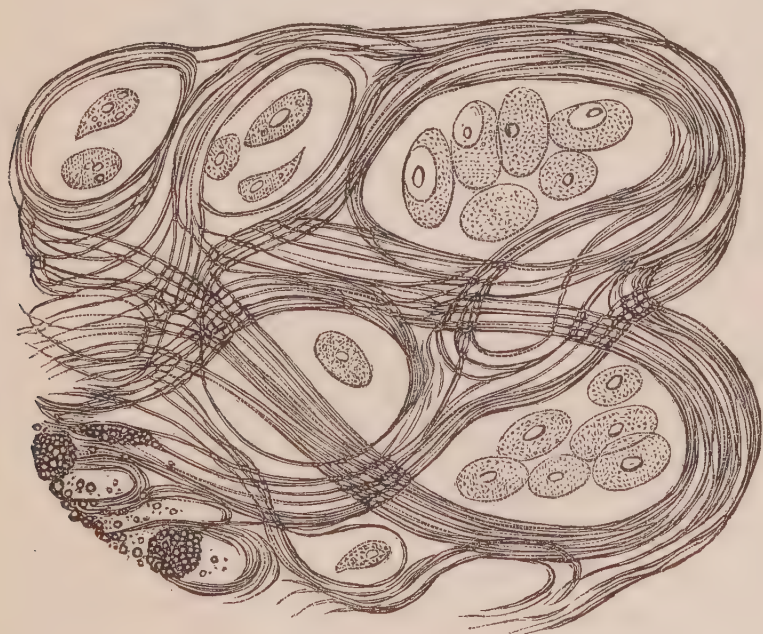

Fig. 132. Appearance of a thin section of the colloid cancer of the peritoneum, described Obs. L.

The lymph attached to the omental tumour and parietal walls of the abdomen was composed of filamentous tissue, interspersed with the same broken down corpuscles and granules which have just been alluded to. It was also studded over with crystals of the triple phosphate.

The amber-coloured transparent jelly within the cysts of the ovaries, at first appeared to be structureless. On careful examination, however, with the rays of light directed obliquely, very faint cells could be distinguished of an oval form, varying in their longest diameter from the 1-100th to the 1-35th of a millimetre in diameter. Some of these were distinctly nucleated—(Fig. 133.) A few oily granules could also be seen isolated and in groups.

In the light yellow semi-transparent gelatinous matter delicate filaments could be seen crossing each other, together with numerous faint cells, round in shape, about the size of pus corpuscles, containing from one to six granules—(Fig. 134).

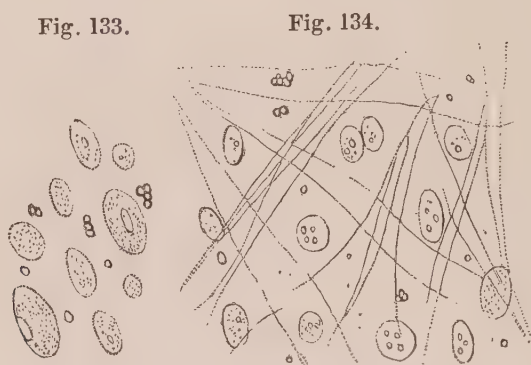


Fig. 133. Delicate oval corpuscles in an early stage of development, from amber-coloured transparent colloid matter in the ovary. Fig. 134. Round and oval nuclei with filaments, in the light yellow semi-transparent gelatinous colloid matter in the ovary.

The white opaque creamy matter in the cysts was entirely composed of minute granules and molecules, united together by delicate filaments. These granules were of two distinct sizes. Those in one group being generally about the 1-500th, those in the other being about the 1-600th or 1-700th of a millimetre in diameter—(Fig. 135). These granules were densely grouped together, and in some places constituted granular masses, similar to those seen in inflammatory exudation.

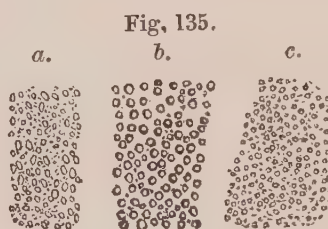


Fig. 135. Groups of granules found in the centre of colloid masses in the ovary; a, granules of irregular shape; b, granules generally about 1-500th of a millimetre in diameter; c, others half the size.

The walls of the cysts themselves were composed of fibrous tissue, more or less covered with numerous granules. In a few places only could granular cells be seen.<sup>1</sup>

*Remarks.*—This case presents the largest quantity of colloid cancer present in one individual, that, so far as I am aware, has

<sup>1</sup> For figures illustrative of the structure of encysted tumours of the ovary, the writer must refer to a paper of his inserted in the *Edin. Med. and Surg. Journal* for January 1846.

ever been recorded. It is worthy of observation, that it was only found on the free surface of the peritoneum, leaving the organs it surrounded untouched. Even the masses which covered the pyloric end of the stomach in no way produced constriction of the organ, or disease of its muscular coat. I am inclined to think, that the colloid matter in the ovary was in nature the same as that found in the fibrous growth of the peritoneum. Although not so much loaded with cells, it contained several in progress of development. A series of preparations illustrative of the morbid changes in this case, is preserved in my collection. The colloid matter of the ovary, which when recent was perfectly transparent, has been rendered opaque and white by the action of the spirit, while that on the peritoneum has remained unaltered.

## OBSERVATION LI.

COLLOID CANCER OF PERITONEUM, STOMACH, AND OVARIES—PLEURO-PNEUMONIA  
—DEATH.

MARION GREENHILL, æt. thirty-one, was admitted into the Royal Infirmary, October 17, 1846, under the care of Dr Paterson. She dated the decline of her health from a difficult labour she had about three or four months previously. About a month subsequently she began to lose flesh, and became languid and jaundiced. At this time also, a small round swelling appeared in the left iliac region. She soon after felt a swelling at the epigastric region, accompanied by a burning heat shooting through the back. The abdomen also commenced to swell. For the last six weeks the urine has been scanty, with frequent desire to micturate, and for the last two weeks she has experienced excessive vomiting. On admission, no tumours could be felt, but there was considerable distension, with some tenderness of the abdomen. There was thirst, white tongue, weak pulse, scanty urine, and constipation. The treatment was palliative only. She died at the end of November, the emaciation and debility increasing, with occasional vomiting, and latterly symptoms of pleurisy and pneumonia.

*Sectio Cadaveris, Dec. 2.*—Skin of yellow cachectic hue—extreme emaciation—abdomen distended by fluid.

*Head* was not examined.

*Thorax.*—Heart small—felt very dense—coronary veins very turgid. About four oz. of dark brown turbid serum, containing flocculi of lymph, were effused into the right pleura. The pleura over the lower lobe of the same lung, was coated with patches of recent lymph. The inferior portion of this lobe was partly grey, partly red on section, from hepatization, and presented two

indurated portions the size of a walnut, and of a plum colour, as if from recent extravasation of blood. There were about six oz. of serum in the left pleura; the inferior margin of the lower lobe of left lung also hepatized, but to a less extent than the right. A few patches of recent lymph also covered its pleural surface.

*Abdomen.*—The peritoneal cavity contained about a gallon and half of dark yellowish brown clear fluid. Under the right lobe of liver a pouch was formed by a band of membranous lymph, stretching from its fissure to the anterior abdominal wall, which contained about a pint of fluid similar in its character.

The whole of the peritoneal surface was of a dark red or purple colour, mottled with round and square patches of a white colour, varying in size from a small pea and under, to three-fourths of an inch square. The dark colour of the peritoneum was owing to a covering of chronic lymph, deeply tinged with blood, which could be removed in layers from the surface of the intestines. The white patches consisted of the healthy serous membrane shining through the red exudation on its surface. Scattered over the peritoneum were numerous rounded semi-transparent masses of colloid cancer, resembling in appearance gum arabic, and varying in size from a small pea to that of a hazel nut. Over the transverse or descending colon these masses were very common, and closely aggregated together. The peritoneal surface of the diaphragm was covered with similar masses, some of them as large as an almond, and its posterior portion adhered strongly to the liver through the medium of the same deposit, a continuation of which accompanied the vena cava in its passage through the liver, and surrounded it to the thickness of a quarter of an inch. The spleen was united to the diaphragm and descending colon by firm bands of chronic lymph, and its surface was studded over with round semi-transparent gelatinous masses, the size of a pea. Internally the above organs were all healthy, the disease being confined to their peritoneal coverings. The pancreas and kidneys were also healthy.

The pyloric end of the stomach was felt to be hard and greatly enlarged, constituting a dense tumour, and the transverse arch of the colon was closely united to it, and drawn up towards the greater curvature by a mass of colloid cancer, extending between the parts. The coats of the stomach along the lesser curvature, and the pyloric extremity, were contracted and thickened half an inch by the deposition of the same cancerous matter.

Both ovaries were converted into solid tumours, about the size of a small orange, but deeply nodulated and irregular on their surfaces. On section, they seemed composed of a sarcomatous mass. In the left, this enclosed three cavities about the size of a bean, filled with a gelatinous matter, resembling in colour and consistence trembling calves'-feet jelly.

*Microscopic Examination.*—On making a thin section of the morbid growth, it presented the same general appearance of a fibrous stroma, forming loculi, and containing cells, as in Observation L. In some places, however, the loculi were completely crowded with cells, as seen in Fig. 136. The cells also presented exactly the same character as in the last case, but in some places were more numerous. Several are represented isolated—(Fig 137). Granules and

compound granular corpuscles were collected together here and there in groups in the substance of some sections. Firm pressure between glasses, and washing with water, got rid of the cells from a thin section altogether, so that the fibrous stroma appeared as represented Fig. 138. Here and there also, the morbid growth seemed to be wholly composed of colloid tissue, no cells being visible in the amber-coloured fluid. On adding acetic acid, the fibrous texture became more transparent, the cell-walls were partially dissolved, while their nuclei remained unchanged—(Fig. 139). In the ovaries the fibrous stroma was more dense, but presented here and there a cystic structure, as in the last case. The colloid matter also was rendered turbid by acetic acid.

Fig. 136.

Fig. 137.

Fig. 139.

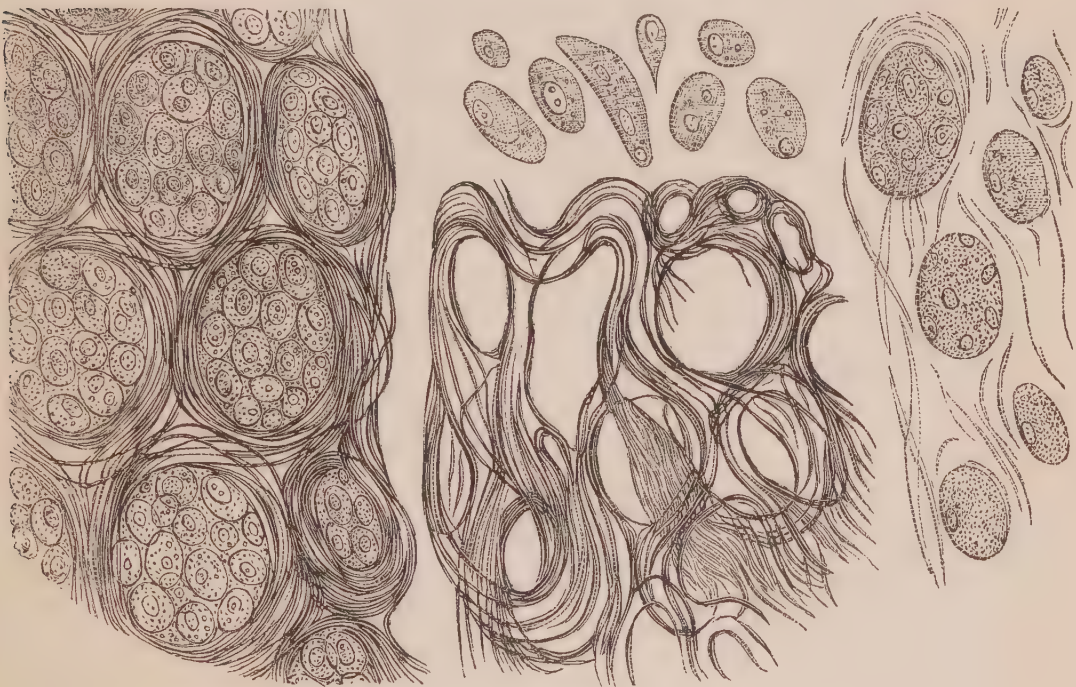

Fig. 138.

*Fig. 136. Section of the colloid cancer, described Obs. LI., showing the loculi in the fibrous structure and the contained cells. Fig. 137. Several cells isolated. Fig. 138. Fibrous stroma deprived of the cells by pressure and washing. Fig. 139. Section of the growth treated with acetic acid.*

*Remarks.*—In this Observation we observe the same disease as in the last, which, however, had not proceeded to the same extent as regards quantity, although the development of the corpuscles in some places was more exuberant. On comparing Fig. 136 with Fig. 1, the resemblance of structure becomes striking. On comparing the two sections when treated with acetic acid, however—Fig. 139 and Fig. 2—a marked difference is exhibited in the fibrous element of the growth. In the former, the one now under consideration, no oval or elongated nuclei were present; in the latter, exhibiting ordinary cancer of the breast, the presence of these nuclei renders it

probable that the fibrous element is developed in a different manner. As far as my observations have carried me, permanent nuclei are never present in colloid tissue.

For an opportunity of examining the excised breast in the following Observation, I am indebted to Professor Miller. An account of the case was kindly given to me by Dr Cornwall of Leith.

### OBSERVATION LII.

#### COLLOID CANCER OF THE MAMMA—EXCISION—CURE.

Miss S——, æt. fifty-one, of firm stout make, robust, and of a ruddy healthy complexion, in March 1847 discovered, on trying on a pair of new stays, a tumour in her right breast. It becoming uneasy and painful, she came to Edinburgh and had medical advice; a prescription was given her for medicine to take inwardly, and for a lotion to be applied to the part. She was advised to return home to the country, and persevere in the use of these medicaments for several months.

The growth continued to increase in size. At the beginning of the present month it seemed to be about the size and shape of a walnut; its position was about an inch to the outer and upper side of the nipple, unconnected, *i. e.* not adherent, to the muscle beneath, or the skin over it; no trace of affection of the lymphatic system. In consistence it was firm to the feel, but not particularly hard; pressure caused pain; the surface was felt to be botryoidal or nodulated, as if peas were imbedded into it; poised in the hand it had not much weight; the breasts full and fat. Two kinds of pain were complained of, described as dull gnawing pains, and sharp shooting pains—the latter sometimes extending to the shoulder and down the arm of the affected side; the former felt only in the swelling, not constantly, but coming on at intervals. The general health of the patient quite good. The catamenia ceased three years ago. She supposes that this breast may have got a blow in the year 1840, when she had a collar-bone broken, and was otherwise injured by the falling of a bridge which she was crossing in a carriage.

The mammary gland and tumour were removed by excision on the 15th of April by Mr Miller. The patient made a rapid recovery, and is now, June 10th, in excellent health.

*Examination of the Tumour.*—Imbedded in the fatty tissue of the gland was a firm growth the size of a hen's egg, which on section presented a bluish-gray surface. It was composed of numerous loculi or cysts, the fibrous partitions of which resembled, in some places, those on the surface of a cut orange. They were filled with a pearly, transparent, gum-like fluid, of the consistence of tolerably firm jelly, trembling on the knife. The individual loculi or cysts varied in size from a pin's head to a large pea. The margins of this growth were tolerably circumscribed, a distinct line of demarcation existing between it



and the yellow fatty substance of the gland. Here and there a small nodule of the same colloid substance, about the size of a pea, was separated two or three lines from the chief mass, and imbedded in fat.

*Microscopic Examination.*—A section of the morbid growth with a double-bladed knife, exhibited exactly the same fibrous structure, arranged so as to form oval and circular loculi as in the last case, and I have not thought it necessary to figure it again. The contained colloid substance was in some places colourless and structureless, in others loaded with very transparent delicate cells. On squeezing out, or scraping from the surface some of the gelatinous matter, it was seen to contain masses of cells grouped together, as in Fig. 140. The nuclei were generally very apparent, and seemed at first to be imbedded in a quantity of granular matter. By careful management of the light, however, the nuclei could be observed to be surrounded with delicate walls compressed together. Some of these groups were loaded with fatty granules, evidently deposited between the nucleus and cell wall. Fig. 140 also represents some of the cells isolated, as in Fig. 137, but more transparent; a few are elongated, approaching the caudate form. Scattered among the transparent colloid matter were masses of fatty granules, often agglutinated together in rows. On the addition of acetic acid, the cells, both isolated and in groups, became more transparent—(Fig. 141); and in some of the most transparent gelatinous matter, delicate fibres were formed by precipitation—(Fig. 142).

Fig. 140.

Fig. 141.

Fig. 142.

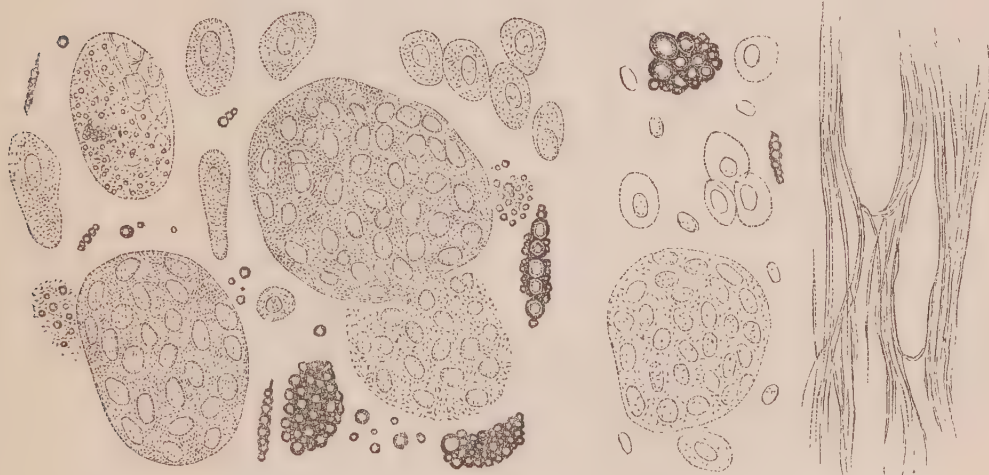


Fig. 140. Cells, isolated and in groups, with granules of fatty matter, squeezed from the colloid cancer, described Obs. LII. Fig. 141. The same after the addition of acetic acid. Fig. 142. Fine filaments precipitated in colloid matter on the addition of acetic acid.

*Remarks.*—The colloid cancer in this Observation seems to me to have been in an earlier stage of development than in the two former ones. The groups of cells exactly resembled masses of young epithelium, which led me to examine whether any were attached to the inner surface of the cysts. After making numerous sections,

however, with the utmost care, with a sharp double-bladed knife, I could not satisfy myself that the cells bore any relation to the inner surface of the fibrous structure, or that there existed any where an appearance of an epithelium layer. On the contrary, the nuclei were every where scattered throughout the substance of the colloid matter, surrounded by faint cells, and, as we have seen, were easily separated or turned out by pressure, and by washing. The formation of filaments in the colloid matter on the addition of acid, is a fact worthy of observation in this instance. It did not take place in the colloid cancer of the two former observations, but only in the colloid matter in the ovary in Obs. L.

### OBSERVATION LIII.

#### COLLOID CANCER OF THE MAMMA—EXCISION—CURE.

In September 1847, I received from Mr Page of Carlisle a portion of a tumour he had excised from the breast. The following is the account he has been so good as to give me of the case :—“ *Carlisle, 7th October 1847.*—My dear Sir,—The patient from whom the last tumour was removed is a female domestic servant, forty-seven years of age, still menstruating regularly, thin, but not of healthy aspect, but has seldom been the subject of indisposition. A year since she first accidentally discovered a hard tumour, the size of a bean, in the upper part of the left breast, which gradually increased in size, but was not attended with pain until about a month before its removal; during that period, however, she suffered much from occasional attacks of severe lancinating pain. The tumour (September 20th) was the size of a pigeon’s egg, hard, and apparently quite distinct from the substance of the breast in which it was imbedded; but when removed it was found to be less circumscribed than had been supposed, as distinct prolongations of the tumour were seen extending chiefly in the direction of the nipple, which was not at all retracted. Of the general structure of the tumour, you can accurately judge from the portion I sent you. The wound healed rapidly; but there is now, less than three weeks from the operation, a very suspicious hardness of one of the axillary glands, at present not larger than half a pea, which is the seat of occasional ‘pricking’ pain.

From the throbbing pain in the former case, together with the rapid enlargement of the breast, it was for a considerable period looked upon as an abscess; at the time I first saw it, however, the woman suffered comparatively little pain, and that was generally more of a burning than of a lancinating character, although she spoke of occasional severe ‘prickings through the breast.’—I am, dear Sir, yours very truly, W. B. PAGE.”

In a letter from Mr Page, dated June 6, 1848, he says the cure has been

complete up to that date, and she follows her usual occupation of a domestic servant without inconvenience.

*Description of the Portions of Tumour received.*—I received two portions of the tumour, each about an inch long and broad, and about half an inch deep. They were of a brownish purple colour, composed of a fibrous basis, containing here and there small cysts, the largest not above a line in diameter, filled with a dark brown, semi-transparent colloid matter. In one or two places there were a few gritty particles of calcareous matter.

*Microscopic Examination.*—A section of the morbid structure presented the same general characters as in the three last cases, namely, a fibrous net-work, forming loculi containing colloid matter. The fibrous element, however, was greater in quantity, and the cysts or open spaces consequently more separated from each other. No isolated cells could any where be discovered; but on squeezing the growth, the contents of the cysts could be removed entire, presenting round or oval masses, as in Observation LII. In masses so separated, no nuclei or cells could be seen, even with the most careful management of the light, nor was the existence of an investing membrane at all evident. The whole resembled a finely granular round or oval mass. One of these is figured alone on the left of Fig. 143. On adding acetic acid to a thin section of the tumour, the filaments became more transparent, and the contents of the cysts, while they retained their finely molecular appearance, permitted the existence of distinct nuclei to be observed—(Fig. 143). These were of an oval or slightly flattened form, about the 100th of a millimetre in their longest diameter, scattered throughout the substance of the colloid matter. No cell wall was any where to be observed. The calcareous points were composed of irregular semi-crystalline masses, soluble in the mineral acids.

Fig. 143.

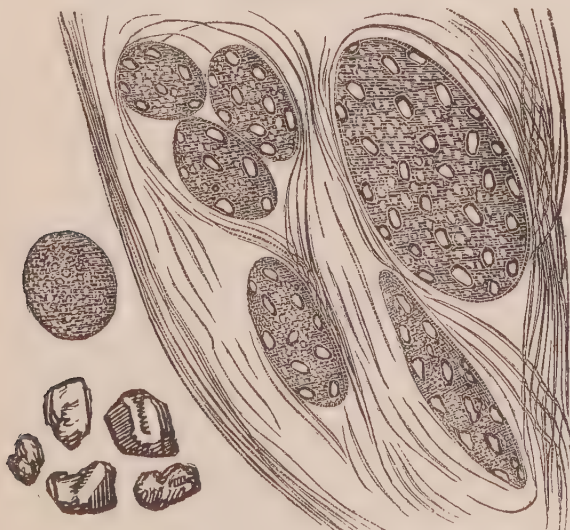

Fig. 143. Appearance of a section of the colloid cancer, described Obs. LIII., after the addition of acetic acid. To the left of the figure is seen a round molecular-looking mass squeezed from a cyst before acetic acid was added. Below, masses of earthy salts.

*Remarks.*—In this specimen of the disease, the cell formation evidently presented even a less advanced condition than in the last Observation, and we may fairly suppose that it furnishes us with an example of its earliest development. Nothing but isolated nuclei scattered through a finely molecular blastema was observable, and here, again, no connexion could be made out between these nuclei and the internal surface of the individual cysts.

The four specimens of colloid cancer we have now examined, point out to us that its fibrous element differs materially from that in other forms of cancer, and never presents any traces of having been formed from cell development, or through the agency of nuclei. It seems more probable that they are formed by precipitation, or the coagulation of the albuminous principle originally dissolved in a fluid blastema. The origin of the colloid matter is still shrouded in obscurity. Even for a knowledge of its chemical principles, we must still look to future research, although it has been supposed to consist of some peculiar form of albumen or fibrin, probably the former. The facts detailed, however, show, that while under some circumstances acetic acid produces little or no effect upon it; at others it causes a copious precipitate, which assumes the form of filaments, which are identical in structure and properties with those forming the basis of the morbid growth. The corpuscles are evidently formed in the colloid matter as in a blastema; first by the formation of nuclei, around which cell walls are formed, which then present all the characters of cancer cells.

#### OBSERVATION LIV.

##### ENCYSTED SANGUINEOUS COLLOID TUMOUR OF THE BACK—EXCISION—CURE.

WILLIAM HARPER, æt. forty, a weaver from Tillycoultry, applied to Dr Duns-mure with a bloody fungoid tumour over the vertebral column in the upper part of the lumbar region. He stated that it was of twenty years' standing, and had ulcerated six weeks ago. Since then it had from time to time discharged large quantities of blood, causing great weakness, and producing a blanched, exsanguine appearance. On examination a tumour was observed in the situation referred to, the size of a small orange, with an ulcer on its surface the size of half-a-crown, from the edges of which projected a bloody fungus of a dark brown or blackish colour. Patches of dilated small veins were also scattered over the back here and there, varying in size, the largest about the circumference of a shilling.

The tumour was excised by Mr Lizars, June 9, 1848, by a double elliptical incision, and the wound completely healed by the first intention.

*Examination of the Tumour.*—The tumour was the size of a billiard ball or small orange, globular in form, and surrounded by a distinct fibrous cyst, nearly one-eighth of an inch in thickness. The skin covering it, as well as the investing cysts, which were strongly adherent together, had ulcerated externally, causing a sore about the size of half-a-crown, with uneven, ragged edges. From this there protruded, three quarters of an inch beyond the margins of the ulcer, a black looking mass, evidently composed of coagulated blood. On dissecting the tumour, the cyst was seen to be occupied by two substances: 1st, Coagulated blood in masses, one of which was connected with the external fungus, and which in the aggregate occupied one-half the tumour; 2d, These masses were imbedded in an amber-coloured, semi-transparent colloid matter of great density, resembling tolerably firm glue in consistence, or vulcanized caoutchouc, which, when torn, exhibited a slightly fibrous arrangement, although it could be readily broken down in any direction. This matter was hollowed out in loculi here and there, containing the coagulated blood.

*Microscopic Examination.*—On squeezing a little of the colloid matter between glasses, and examining it with a magnifying power of 220 diameters, it was seen to consist of a hyaline blastema, of a very slightly striated or fibrous appearance. Here and there imbedded in it were a few fat globules, and numerous fine molecules, of a yellowish brown colour, deposited in the form of rolls, varying in diameter from the 1-100th to the 1-30th of a millimetre in diameter. These in some places inosculated, forming a net-work; in others, they threw out branches, terminating in a round or club-shaped extremity—(Fig 144). The margins of these rolls were quite abrupt; but no continuous wall could be detected. Acetic acid rendered the hyaline substance more transparent, but in no way affected the rolls of granules.

The blood presented the usual appearances of old or recent hemorrhagic extravasations.

The investing fibrous cyst was composed of fine fibres, which were rendered more transparent on the addition of acetic acid. In only a few places externally, near the skin, could elongated nuclei be discovered.

Fig. 144.

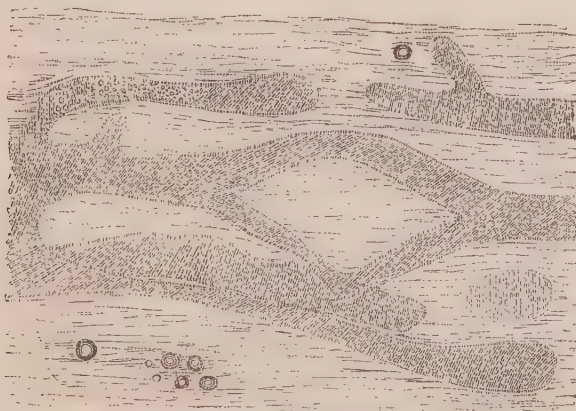


Fig. 144. Structure of the colloid matter, described Obs. LIV.

*Remarks.*—This tumour was considered to be a fungus hæmatodes by those who treated it, of which disease it presented all the external symptoms. On examination it was found to consist partly of recent clots of blood, but the source of the hemorrhage could not be discovered. The basis of the tumour was evidently colloid matter, in which no appearance of cell formation could be discovered. It seemed to me as if the originally transparent colloid matter had gradually become inspissated, while its more external portion had been condensed into a cyst. What the peculiar finely molecular deposits were composed of, or whether this constituted the structural commencement of vessels, I was unable to determine.

#### OBSERVATION LV.

CANCROID ULCER OF THE SCROTUM AND PENIS—(CHIMNEY-SWEEP'S CANCER)—  
EXCISION—CURE.

During a visit which I made to Bartholomew's Hospital, on the 10th August 1848, my attention was directed to a case of so-called chimney-sweep's cancer, in one of Mr Stanley's wards. It was that of JAMES CHARD, æt. twenty-five, a well made man, who had always enjoyed good general health. He had followed the occupation of a chimney-sweeper twelve years, at first never cleaning himself, although continually enveloped in soot, which collected chiefly in the folds of his shirt. Latterly he washed himself once a-week, but very frequently went a month without doing so.

About twelve months before entering the hospital, he observed a warty growth, with a very irregular surface, on the anterior part of the scrotum, close to the penis, which was tender when touched, but was not otherwise painful. During the next seven months it gradually increased in size, until it had enveloped nearly the whole scrotum, and had attacked the integuments at the base of the penis, cracking and splitting into irregular nodules, "like a seedy wart," which he considered it to be. It now began to ulcerate around the margin, discharging a thin dirty-looking matter, which was very offensive. As the ulceration extended, it became more and more painful, so that his night's rest was greatly disturbed, and at length altogether prevented. The quantity and fœtidity of the discharge also increased. On admission, there was a deep ulceration surrounding the body of the penis, occupying the whole scrotum, with the exception of a very small portion on the right side, and just clearing the perineum. The edges were clearly defined, ragged, elevated above the base (in some places nearly half an inch), nodulated, and very hard. The base was composed of irregular nodules, with clefts between them, in which purulent matter and a white friable substance accumulated; but near the scrotum it presented a villous appearance. In consequence of the integuments being so deeply ulcerated, while a considerable portion of the

skin on the penis anteriorly was unaffected, that organ seemed to be almost cut through and detached from the body.

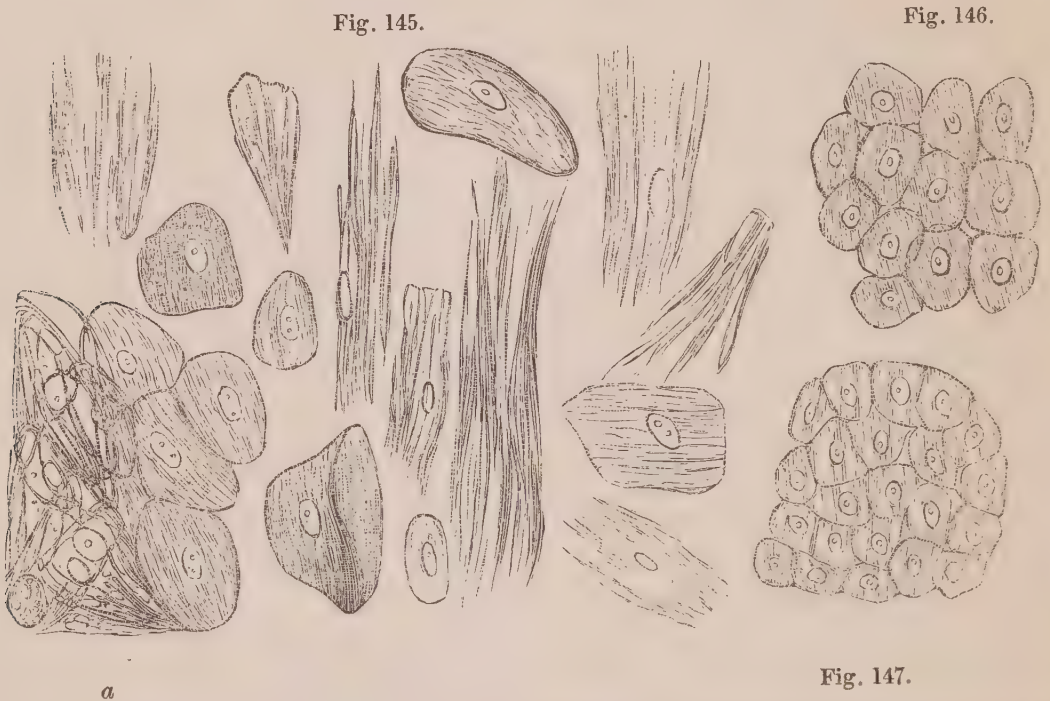
For a fortnight after his admission the ulceration made rapid progress. On the 14th of August Mr Stanley removed the whole of the diseased structures, exposing the testicles and their chords, and leaving only a small portion of healthy integument around the corona glandis. A few of the inguinal glands were also removed. Since the operation the patient has not had a bad symptom. The pain, which before was constant, has not been felt since. *September 12th.*—At present the testicles are almost completely skinned over, and the body of the penis and adjacent parts over the pelvis present a healthy granular surface, discharging a slight and healthy purulent matter.

*Examination of the parts removed.*—This I was enabled to do some days after the operation, and after their immersion in spirit, through the kindness of Mr Paget. The diseased parts consisted of several portions, the largest of which was that which occupied the front of the scrotum. The ulcerated surface here was composed of numerous hypertrophied and elongated papillæ, resembling in appearance the base of a calf's tongue, or the mucous membrane of the duodenum in herbivorous animals. In other places the ulcerated surface was warty, rough, or nodulated with cracks or crypts separating them, filled with a pulpy caseous matter. The edges of the ulcer were greatly indurated and nodulated, and the integuments cut through, were in some places nearly an inch in depth, composed of fat, deposited in a reticulum of hypertrophied areolar tissue. The inguinal glands were enlarged. One was the size of an almond-nut, soft, on section presenting a greyish, uniform appearance.

*Microscopic Examination.*—I was enabled to examine different portions of the structures removed through the kindness of Mr Lowe, the house surgeon, and afterwards of Mr Paget. The portion I received from Mr Lowe was fresh, and evidently consisted of a section of the morbid integument, where it was most softened and diseased. It was about three-fourths of an inch in depth, and had a fibrous septum running through its middle. A minute portion removed from the external portion of this septum, and examined microscopically, exhibited a confused mass of epithelium or epidermic scales, enlarged, split into fibres, and matted together. On adding a little water so as to separate them, the appearance was seen, represented Fig. 125. In some places masses of aggregated scales were still visible (*a*), but those which were isolated varied greatly in size and shape; in size from 1-40th to the 1-6th of a millimetre in length; in shape from the round oval, or ordinary flat many-sided forms, to the cleft, fringed, and elongated shape, indicative of their transition into fibres. These different appearances, splitting up of the scale, and passage into filaments, are well seen in the figure. Many of those scales were furnished with an oval nucleus, containing one or more nucleoli. Acetic acid produced no change in them. A portion removed from the other side of the septum, exhibited groups of well-formed epithelial cells, round, oval, or many-sided from pressure, with the general diameter of about 1-40th of a millimetre, and each furnished with a round nucleus, with a very distinct dark border, 1-100th of a millimetre in diameter, containing one

granular nucleolus—(Fig. 146). Both cell-walls and nuclei were rendered more transparent on the addition of acetic acid—(Fig. 147).

The portions removed from the diseased parts, after their immersion in spirit, exhibited the same structures as have just been described, but not so distinctly. The transparent groups of cells in particular had become more opaque and granular. The adipose cells in the integuments were large, and contained a large brownish granular nucleus. The lymphatic gland removed from the groin contained a multitude of round or oval bodies, about the 1-100th of a millimetre in diameter, containing one or two nucleoli. On the addition of acetic acid, they seemed to be composed of a cell-wall, and a round nucleus about the 150th of a millimetre in diameter. The action of the spirit had probably destroyed their natural appearance.



*Fig. 145. Epidermic scales in mass, and isolated from the chimney-sweep's cancer, described Obs. LV. Fig. 146. Group of deeper seated cells. Fig. 147. The same after the addition of acetic acid.*

*Remarks.*—In this case the disease commenced externally by the production of warty excrescences on the scrotum, extending over the surface, and ulcerating at the margins. It was probably caused by the irritation of the soot and dirt collected about the part during his occupation, while habits of cleanliness were wholly neglected. In structure, it closely resembled the two cases of cancroïd of the lip, Obs. XLI., XLII., but had proceeded to a much greater extent. The epidermic scales had not only become greatly swollen and enlarged, but were splitting up into fusiform corpuscles and filaments, the former resembling those previously figured in a case of cancer of the skin, Obs. VIII., Fig. 22. The group of deep-seated



cells presented one of the most beautiful specimens of epithelial formation I ever saw; and between these, and such as were enlarged and breaking up into filaments, every degree of gradation could be observed. A very important circumstance to be attended to in this case is, that the lymphatic glands in the neighbourhood were affected. I regret that I had no opportunity of examining these glands when fresh. So far as the examination went, however, no cells could be discovered which resembled those either of cancer or of epithelium.

In a note to his translation of Müller, Dr West states that he examined a chimney-sweep's cancer which had been kept some time in spirit. He has figured a number of spindle-shaped bodies, which are doubtless, as he says, epithelial corpuscles compressed together. (See Müller on Cancer, p. 87.)

## OBSERVATION LVI.

## CANCROID ULCER OF THE TONGUE—EXCISION.

DR R.—, æt. thirty-nine, of robust health, and tendency to plethora, observed, in December 1847, a small ulcer on the external edge of his tongue on the right side. It was considered to originate from derangement of the digestive organs, and kept up by pressure of the organ against the teeth; and, in February 1848, a silver shield was made to cover the latter, and to present a smooth surface to the ulcer. The sore continued to extend however, with hard everted edges, but caused little inconvenience or uneasiness; and he took for some time in succession, arsenic, rhubarb and soda, and corrosive sublimate. In May, when I first examined it, it was the size of a shilling, its surface covered with numerous depressions or crypts, in which were collected a whitish friable matter. This, on a microscopic examination, was ascertained to consist partly of epithelial scales, and partly of a molecular and granular matter, probably broken down food, in which numerous *confervæ*, in the form of filaments, were growing luxuriantly. The edges of the sore were hard and everted, the ulceration burrowing under them for a short distance. The medical men consulted pronounced the disease to be malignant, and advised that it should not be interfered with in any way. Towards the end of July the ulcer superficially was the size of a five-shilling piece. Diet, change of air, and attention to the general health, had failed to correct its progress. Its surface and edges were more ragged, pus and superficial sloughs were collected here and there among the depressions. A hard ridge could be felt all round the ulcer, as deep internally as the median line, and posteriorly extending as far back as the isthmus of the fauces. The disease now caused considerable pain, especially at night; but the health, strength, and appetite were good. His surgical advisers still refused to interfere. The disease made progress, and a lym-

phatic gland in the right side of the neck became enlarged, and somewhat tender on pressure. He suffered extreme agony; his nights were sleepless; chloroform and morphia were continually employed with only partial relief; his general health, from the constant pain and want of sleep, had greatly suffered; his appetite failed, emaciation and debility were making rapid progress, when, on the 31st of August, the whole disease was excised by Mr Fergusson of London. The same night he slept well, and had no pain. A week after there was a hemorrhage to about four oz. In ten days all the ligatures had separated. In fourteen days I found him walking in a public garden, and the tongue had nearly healed, presenting a deep stellate puckering on the right side. At present, September 18, his general health is perfectly re-established, and he articulates as well as he did previous to the operation. There are still a few florid granulations on the tongue where it is not fully cicatrized. The gland in the neck, which became increased in size after the operation, is, he says, now somewhat diminished, but remains tender on pressure.

The continuation of this case will be given in the Appendix.

*Description of portion of Tongue removed.*—The portion of tongue removed was of a triangular or wedge-like form, and measured two inches and a half long, an inch and three quarters deep, and an inch and a quarter in thickness at its posterior and thickest part. On the external side was the ulcer formerly described, with its indurated margin; on the other the knife had passed through the soft and healthy tissue of the organ; superiorly the portion was covered with healthy mucous membrane; inferiorly the knife passed closed to, and in one place even went through some of the indurated mucous membrane forming the margin of the ulcer as it dipped down below; and posteriorly the knife had passed through healthy muscular substance. On making a section transversely through the tongue in the middle of the ulcer and induration, the cut surfaces presented a white indurated convoluted structure immediately below the ulcer, and above the muscular substance of the tongue. This white indurated matter was of scirrhus hardness, half an inch in thickness posteriorly, not yielding on

Fig. 148.

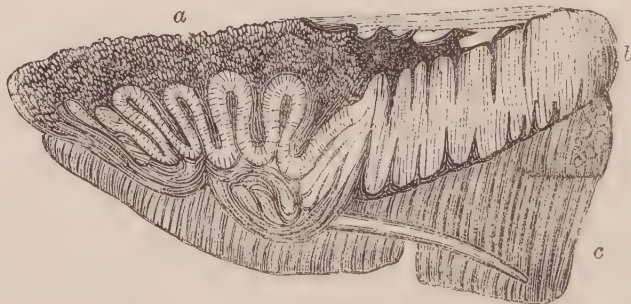


Fig. 148. Transverse section of the portion of tongue, described Obs. LVI.; a, ulcerated surface; b, white condensed epithelial growths; c, healthy muscular texture, in which an enlarged and indurated duct may be seen extending posteriorly.

pressure any fluid. Here and there it was split up both above and below, and anteriorly the separated portions dipped down into the substance of the tongue

in the form of loops, closely wedged together, not unlike the convolutions and anfractuosités of grey matter on the surface of the brain. The surface of the ulcer was covered in the same way with what looked like enlarged papillæ, or irregular pointed or truncated elevations, between which grooves extended down to a greater or less depth. Several hard cord-like prolongations extended back from the ulcer, and spread into the tongue posteriorly, one of which is represented Fig. 148, *c*.

*Microscopic Examination.*—On removing a little of the softened substance from the surface of the ulcer, and examining it with a microscope, the same kind of enlarged, softened, epithelial scales, splitting into fibres, were observed as on the surface of the ulcer in the last Observation—(Fig. 145). One of the small papillated projections presented the appearance represented Fig. 148, consisting of the softened and split epithelium, still attached at one extremity, like a fringe.

Fig. 149.



Fig. 149. *Fringe-like epithelium from the surface of the ulcer, in Obs. LVI.*

On making a thin section of the white indurated texture, it presented various appearances at different depths. Below, where it was near the healthy substance of the tongue, the muscular fasciculi were greatly altered; the transverse striæ had disappeared, and the whole seemed converted into a fibrous tissue, infiltrated with fatty molecules and granules, isolated and in masses—(Fig. 150). The structure greatly resembled the altered muscle, represented Fig. 99, and the altered nerve, Fig. 125. Floating here and there were observed fragments of muscular fasciculi broken across, of different lengths, but preserving more or less their healthy appearance, and numerous oval nuclei, with one or two nucleoli, associated with a few fusiform corpuscles. These bodies were evidently passing into fusiform corpuscles and fibres, having caudate appendages, and here and there existed in rows—(Fig. 150). In another part of this section the indurated structure was arranged in concentric circles, surrounding loculi, and seemed to be composed of epithelial scales, closely condensed, which on section resembled fibres. Epithelial nucleated cells and fragments of fasciculi were here also observable—(Fig. 151).

Fig. 150.

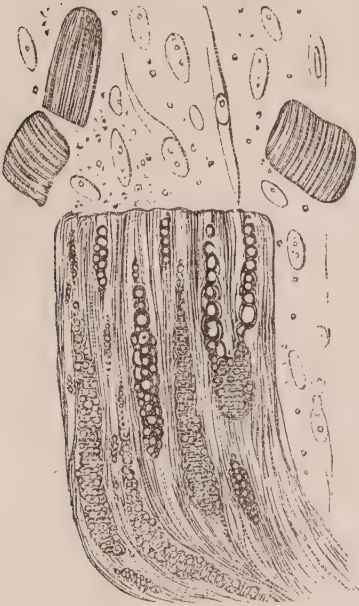


Fig. 151.

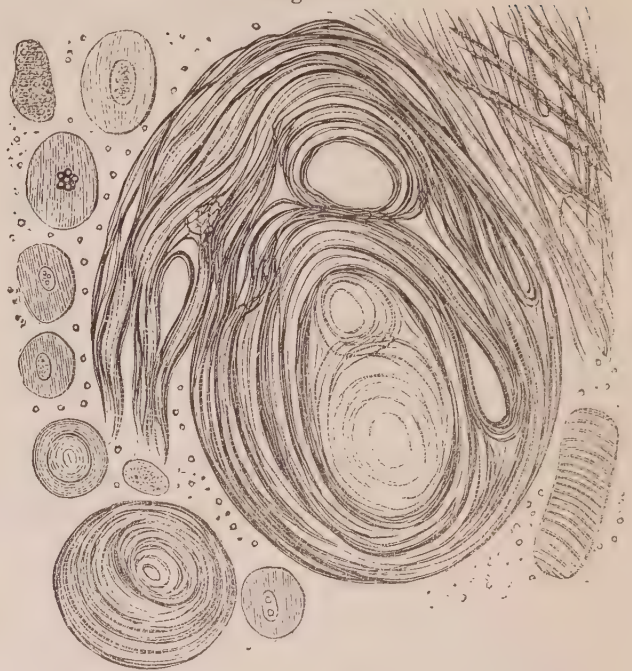


Fig. 150. Altered muscular tissue from the dense portion of tongue described Obs. LVI., with naked nuclei passing into fusiform cells and fibres. Fig. 151. Concentric laminae of condensed epithelial scales from another part of the same section, with epithelial cells and fragments of muscular fasciculi.

Above this, and nearer the surface of the ulcer, the epithelial cells retained more their natural appearance, although compressed together in such a manner that their outlines were no longer visible—(Fig. 152). On examining the white cheesy substance from the interior of the duct, it was seen to be composed of large epithelial scales closely matted together, and associated with numerous fatty

Fig. 152.



Fig. 153.

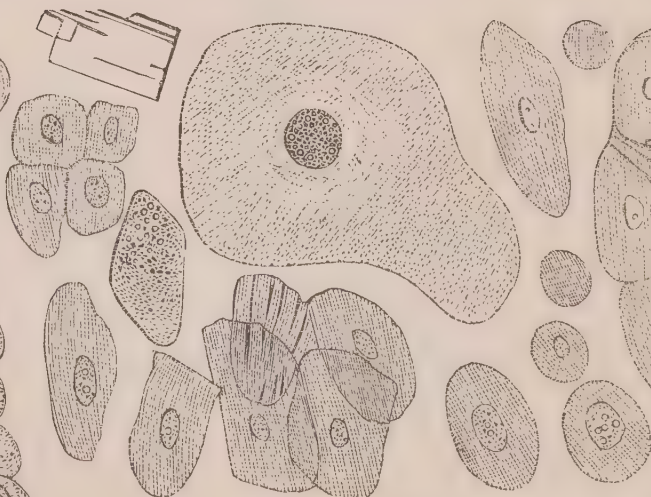


Fig. 154.

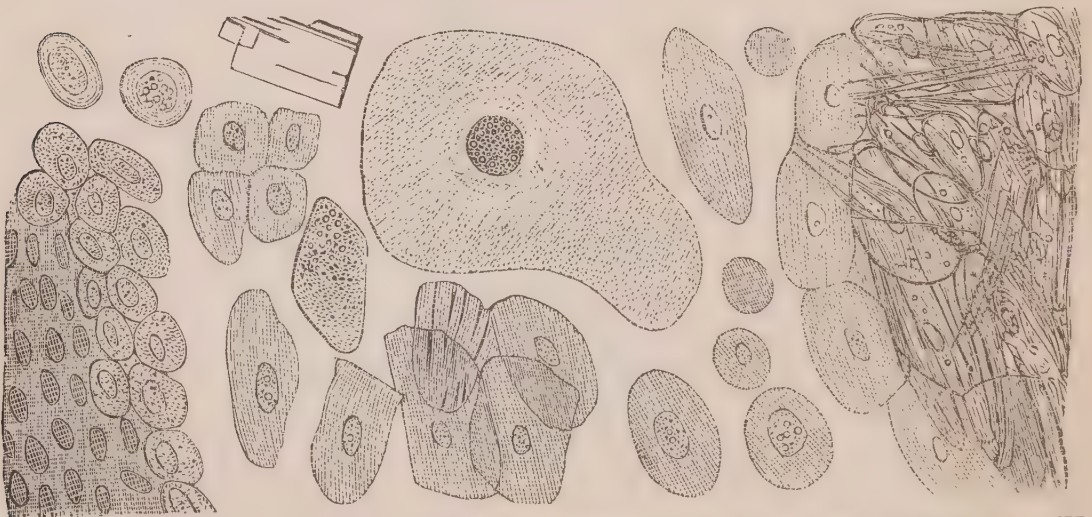


Fig. 152. Epithelial cells compressed together immediately below the surface of ulcer in Obs. LVI. Fig. 153. Epithelial cells from the steatomatous matter in the duct separated by water. Fig. 154. The same in mass.

granules and crystals of cholesterine—(Fig. 154). It closely resembled the structure of some steatomatous encysted tumours of the skin. On separating

them by means of water, they were seen in all stages of development and of disintegration—(Fig. 153). Some were round, with spherical nuclei, containing numerous granules; others were in the form of flat plates, with oval nuclei, containing one or two nucleoli often associated in groups. A few of them had reached an enormous size, measuring the 1-6th of a millimetre in their longest diameter, as represented Fig. 153. Several scales could also be observed splitting into fibres.

*Remarks.*—I took the utmost pains to make out all the facts connected with the structure of this lesion; and it will be seen, on comparing the figures representing it with those illustrating the formation of cancerous growths, that they differ materially. In this, as in most other cases of epithelial ulceration, the disease commenced at the surface, producing increased formation of epithelium cells, and great thickening and induration by their condensation. A true cancer always commences below the epithelium, in the form of a white deposit, which soon appears as a nodule, and by its pressure subsequently causes ulceration through the mucous coat. A thin slice of the hardened scirrhus-looking matter, presented a very different appearance from that observed in similar slices removed from cancerous growths (compare Fig. 151 with Figs. 1, 66, 68, 91), and exhibited nothing but epithelial scales, more or less condensed and pressed together. In several other specimens of ulceration of the lips and gums submitted to me for examination, the same structure was observable. In a case of cancer of the jaw, recorded and figured by Gluge (Atlas Lief. 4, Taf. 3), a similar structure prevailed; he distinguishes such cases by the names of “Primitive Cancerous Ulcer.” Vogel also figures the same concentric lamina of epithelium (Icones, Tab. XXV. Figs. 1, 2) as there given, which he found in a wart—(Fig. 151.)

The four cases recorded, Obs. XLI., XLII., LV., and LVI., are illustrative of a peculiar alteration of mucous and epidermic surfaces, which, though long *called* cancerous by surgeons, evidently presents peculiarities which ought to distinguish it from that kind of growth. The influence of a name, however, has unfortunately been allowed to exert too strong an influence on practice; and because these ulcerations will not heal, because they sometimes return in the place from whence they have been apparently excised, they are denominated “malignant,” and have often been allowed to take

their course. Others, again, have been led to doubt their cancerous nature, from observing that such indurated ulcers return far less frequently than those which are really malignant. But, that the mere circumstance of return or non-return is no indication of the real nature of a growth, is proved by the fact, that true encephaloma of the testicle has been considered by surgeons of great experience, to be capable of being excised with the same good results as so-called cancer of the lip. On these important points I shall dwell more at length in the second part of the work. In the mean time, it must, I think, be evident that growths with very important structural differences have been considered identical by medical practitioners, and we have next to ascertain how far a knowledge of these differences may be useful in our diagnosis and treatment.

## PART II.

I PROPOSE, in the second part of this inquiry, to take a review of the present state of our knowledge of cancerous and cancroïd growths; to contrast prevailing opinions with the facts recorded in the first part; and, lastly, endeavour to ascertain what useful deductions may be drawn from the Observations which have been detailed.

A careful perusal of the preceding pages must, I think, satisfactorily prove, that medical practitioners are continually in the habit of confounding various kinds of structures and growths under the term cancerous, or, as they call it, "malignant." The original meanings of these expressions cannot, in the present state of our knowledge, be considered of any importance. But as the word cancer is universally received in medicine, and will serve as well as any other to distinguish a morbid product, all that is necessary is to give it a definite and positive meaning. I cannot believe that nature has constructed growths containing different minute elements without an object; or that, because the naked sight is unable to distinguish differences, that therefore none should exist. Moreover, when, by means of a good microscope, we can see that among many structures, which to the unaided sight appear identical, some contain so-called cancer cells, others naked nuclei, whilst others are composed of cartilage, epithelium, fibrous tissue, or fat, then it becomes us to inquire into the meaning of these differences, and endeavour to ascertain whether their study can be made available to the relief or cure of disease. I propose, then, to call that structure constituting undoubted and characteristic specimens of cancer, as in Obs. I. and II., **CANCEROUS**, and those which more or less resemble them, are continually mistaken for them, and yet do not correspond with them in structure, as **CANCROÏD**—a term first used in this sense by Lebert.<sup>1</sup> All

<sup>1</sup> *Physiologie Pathologique*, Tome 2me. 1845.

forms of growth coming under these two denominations have been called "malignant" by medical practitioners.

The expression "malignant" has been used in various senses. Some have considered a malignant growth to be one which is the result of a constitutional taint in the system, as distinguished from one which is purely local. Others apply the term to any sore which has a tendency to soften or to spread by ulceration or slough, and so destroy the patient. A third class consider the tendency to return after extirpation as the characteristic of malignancy; whilst a fourth conceive that to be a malignant disease, which spreads to other neighbouring tissues, and converts them into a structure analogous to its own. In fact, the idea of malignancy may be, and has been, attached to any disease which continues to make progress in spite of the efforts of art.

The ideas of "malignant," when used to express a constitutional disease like syphilis—a mere softening, such as often takes place in the brain, or as applied to a sloughing and spreading sore like hospital gangrene—are far too general and vague to require criticism in connexion with the subject of cancer. Its meaning, however, to express a tendency to return after extirpation, demands some notice. No doubt a great practical question is here involved; for nothing is more to be dreaded, after subjecting an individual to a surgical operation, than the return of the disease which renders that operation useless. An observation, however, of what is continually taking place in the animal economy, must make it evident that the return of a growth similar to that which has been removed is one of the most common occurrences, and that such an idea of malignant, *per se*, is opposed even to the notions of those who employ it. It is an undoubted fact, that fatty, fibrous, encysted, and the most innocent tumours, often return in the part from whence they have been apparently removed, and after repeated returns and excisions have at length been finally extirpated. Many such growths appear simultaneously in several parts of the system. In the Dublin Richmond Hospital, I have seen more than one case where hard neuromatous tumours, varying in size from a pea to an adult head, appeared in almost all the nerves of the body. The most limited experience of disease must convince any one, that the constitution, once predisposed to any particular form of malady, is always more prone to its return than to that of any other. The mere idea of return, therefore, ought



not to be considered so characteristic of a truly cancerous disease as it generally is. Hence, in using the term cure, as the result of many operations in the first part of this work, I mean complete absence of all the functional symptoms and local appearances which characterized the disease, without in any way presuming to assert that the disease may never return.

The most accurate meaning of the term malignant I conceive to be, the one which ascribes it to a growth having the power in itself of re-development; that is, once existing, it may spread to other tissues or organs, causing in them a disease or growth similar to itself, by a species of propagation similar to that possessed by animalcules or vegetable fungi. Dr Walshe<sup>1</sup> proposes that this much abused word, "malignant," should be relinquished, and certainly the doing so would be a great gain to science. On the other hand, experience shows, that words once rendered of general use are eradicated with difficulty, and that it is much easier to attach to them a clear and definite meaning. The one now proposed seems to me to be that which is at the same time most in accordance with the state of science, of most general application to the phenomena of disease, and most commonly used by medical practitioners.

Such being the meanings I apply to the terms cancerous, cancroïd, and malignant, I propose treating the subject of cancerous and cancroïd growths under the following heads:—1. Histology; 2. Chemical Composition; 3. General Anatomy; 4. General Pathology; 5. Statistics; 6. Diagnosis; 7. Prognosis; and 8. Rational Treatment.

It is not my intention, under each of these heads, to give a systematic view of all that has been done by others. It will be rather my object to express shortly the views and reflections to which personal observation and the perusal of authors have led myself. These have only convinced me, that so far are we warranted in forming positive conclusions on the subject of cancerous and cancroïd growths, that much greater research than has hitherto been employed is necessary, before we can arrive at even glimmerings of the truth respecting it. At the same time I feel convinced, that modern inquirers, with the means now at their disposal, will not ultimately fail in these researches; and hence, I trust, my observations will be considered as rather sug-

<sup>1</sup> On the Nature and Treatment of Cancer. 1846. P. 187.

gestive, and indicative of the paths which ought to be pursued, than as aiming at any kind of perfection in the present state of our knowledge. We have had abundant experience; but hitherto it has not been properly directed. Diseases, in themselves widely different, have been confounded together, on account of similarity either in the symptoms they produce, or the appearances presented to the naked eye. What the present state of medical science demands is, that experience should be guided by knowledge, and that the observation of symptoms should be conjoined with careful investigations into the nature and ultimate structure of the morbid alterations which accompany them.

## CHAPTER I.

## HISTOLOGY OF CANCEROUS AND CANCROID GROWTHS.

WE have seen in the various Observations which have been detailed, that the different morbid structures have been composed of the following elementary forms :—1. Molecules and Granules ; 2. Naked Nuclei ; 3. Cells of various kinds ; 4. Filaments or Fibres ; 5. Blood-vessels ; 6. Crystals. These are the elementary forms of all morbid products : nor is there any thing characteristic of cancer in either of them, when viewed alone. It is only in relation to each other they become important ; but, in order to judge of this, it is necessary in the first instance to speak of each separately.

## 1. MOLECULES AND GRANULES.

I apply the term *molecule* to that minute body, in which no determinate external edge and internal centre can be discovered. By *granule*, on the other hand, I mean a body which varies greatly in size, and is distinguished by possessing a distinct shadowed ring or margin, the external edge of which is abrupt. When transparent, granules refract light ; so that they present a bright or dark centre, according to the focal point in which they are viewed. The distinction between molecule and granule is only referable to size, and the magnifying power with which they are viewed. The first may become the second, on using higher powers ; and granules may be reduced to molecules, when viewed under a less magnifying lens. Again, a granule may be comparatively so large as to be called a globule, such as the bodies found in milk.

Molecules and granules vary in composition. For the most part, they consist of various kinds of fat, and disappear on the addition of strong potash or ether. They may be purely albuminous, when acetic acid partly dissolves them ; or partly fatty and partly albumi-

nous. They may also consist of pigmentary or mineral matter, when their nature may be ascertained by various re-agents, such as nitric and hydrochloric acids.

Molecules and granules may differ in shape. In general they are spherical, but sometimes they are more or less angular. They may be isolated or grouped together, constituting granular masses. They may exist alone, or be mingled with numerous other elementary forms. Indeed, they may be said to be the most universal element in tissues, and of the greatest importance in enabling us to appreciate the nature of structure.

These bodies may be formed in two ways, by precipitation and by disintegration, that is, primarily and secondarily. The first change to be observed in the germinating seed or ovum, is the gradual appearance in a transparent fluid of numerous molecules and granules, which, by coalescing or enlarging, are gradually changed into more compound structures. Again, when a perfect structure decays, it gradually breaks down into a debris; this is again resolved into granules and molecules, which are ultimately reduced to a fluid state and are absorbed. Thus there may be granules of evolution and granules of disintegration.

Molecules and granules have distinct movements of their own (molecular movements). They may be seen to change their position, and turn round in a liquid with a trembling movement. In the interior of cells these movements are often well marked and of great regularity. When we magnify a salivary globule six or eight hundred diameters linear, we can see the minute granular contents in a state of continual vibration, or revolving in circles of extreme minuteness. In certain vegetable cells these circles are enlarged, so as to constitute a visible circulation. We frequently find molecules and granules encrusting or attached to larger globules, and they, doubtless, occasionally serve to assist the progress of development. Sometimes they are attached together in masses, at others repelled and kept isolated. Similar facts may be observed wherever minute solid particles are seen floating in fluids, which prove that the movements of the minutest molecules are governed by laws as definite and fixed as those which rule the planets revolving in space.

Molecules and granules may be produced mechanically, and are thus capable of being subjected to the same laws as those which are

formed naturally. Thus, the pigmentary and mineral granules precipitated by the chemist, are identical with those precipitated in living fluids. Again, when transparent oil and transparent albumen are brought into contact, a precipitation in a membranous form takes place at the point of union—(Haptogen membrane of Ascherson). Thus, a drop of oil cannot for a moment be surrounded with an albuminous fluid, without its being enclosed in a vesicular membrane or cell. Rubbing the two drops of oil and albumen together, resolves them into granules composed of a minute particle of the one, surrounded by a thin film of the other, which granules are identical with those found in animal fluids. Now, when it is remembered that oil and albumen pervade all organized bodies, that they are continually coming in contact, and that membranes and cells must thereby be necessarily produced; moreover, as the other soluble elements which enter into organized structures must communicate to the fluids various kinds of densities,—it will be clear that all the physical conditions necessary for endosmosis and exosmosis must be present. When, in addition, it is considered that modern anatomy and physiology have demonstrated that all organized structures consist of granules, nuclei, and cells, composed, in like manner, of a membranous envelope, and endowed more or less with the same physical properties, the importance of these facts must be recognised. Indeed, it appears to me in the highest degree probable, that all blastemata containing the necessary nutritive principles in solution, precipitate minute oily particles, which are the elementary granules of histologists. These, either separately or united, constitute nuclei composed of oil, surrounded by an albuminous membrane. In this condition, they become subject to the physical law of endosmosis and exosmosis, and absorb or exude materials, according to the circumstances in which they are placed, and the unknown vital power to which they are subjected. It must always be remembered that the granules produced mechanically by the union of oil and albumen, are not vital structures; but when formed in the animal body, under certain conditions, they become so. The physical relations I have pointed out are only necessary preliminary steps for the addition of that unknown force we call vitality, which directs the ultimate form these structures assume. They are a *sine qua non*, without which vitality cannot be called into existence. The different cells entering into the composition of the tissues are not formed from them directly, as

Ascherson supposed, but are the result of a series of physical and vital changes occurring in the elementary granules and nuclei, which, however, are themselves produced in the manner he pointed out.<sup>1</sup>

These considerations lead to a generalization, which appears to me to be of great importance, namely, that the molecular element is the real basis of all the tissues, and not the cell as maintained by Schwann, or the nucleus as is contended for by Henle. No cells are formed without nuclei, and no nuclei without granules; and it is a knowledge of the laws regulating the deposition of the latter in an exudation, and within nuclei and cells, that must guide us to a rational therapeutics, so far as the diseases of nutrition are concerned.

## 2. NAKED NUCLEI.

Numerous facts tend to show that nuclei may be formed in two ways, primarily and secondarily. In the first case, they are produced from the aggregation and melting together of molecules and granules, and there is formed upon them afterwards a cell-wall, during the transformations of which the nucleus may remain permanently, may undergo a species of development, or completely disappear. In the second case, the original nucleus may expand and form the outer cell-wall, and another nucleus may be produced within it, also by the deposition and melting together of granules, which by division, or the formation of other internal nucleoli, produces new nuclei and cells. In either of these cases occurring in healthy or morbid tissues, we may observe the nuclei of cells in all stages of their growth, and can have little doubt as to the progressive steps of their production.

The nuclei formed in cancerous and cancroid growths are produced in the same manner as similar bodies in other textures. When seen in well-formed cancer cells, they are for the most part secondary—that is, formed subsequent to the cell-wall which encloses them, and will be described as forming part of the cancer cell. In many of the Observations detailed, however, I have found

<sup>1</sup> For more lengthened observations on this subject, see the author's paper "On the Structural Relation of Oil and Albumen in the Animal Economy, and on certain Physical Laws connected with the Origin and Development of Cells."—*Monthly Journal of Medical Science*, September 1847.

in the growth numerous naked nuclei mingled with the fibrous stroma—(Obs. XXI., Fig. 54; Obs. XXII., Fig. 58; Obs. XXIII., Fig. 60; Obs. XXIV., Fig. 62; Obs. XXV., Fig. 63; Obs. XXX., Fig. 77; Obs. XXXIII., Fig. 82; Obs. XXXIV., Figs. 85, 87; Obs. XXXVII., Figs. 95, 97, 99; Obs. XLIII., Fig. 115; Obs. XLVII., Figs. 122, 123; Obs. L., Fig. 134; Obs. LVI., Fig. 150.) In some of these, doubtless, their occurrence is explained by the breaking down and disappearance of the cell-walls which at one time enclosed them. In this manner free nuclei occur secondarily, and are the result of disintegration, as in Obs. XXV., Fig. 63, and Obs. XXX., Fig. 77; but, at other times, they are undoubtedly a primary formation, existing in an advancing and not in a retrogressive growth, and are then often unconnected with cells—(Obs. XXXIV., Figs. 85, 86, 87; Obs. XXXVII., Figs. 95, 97, 99; Obs. XLVII., Fig. 122). Whether these bodies, under such circumstances, are capable of producing similar bodies without the agency of cells, is doubtful, although Bruch<sup>1</sup> says they can. But, having observed them in recent fibrinous deposits around corpora lutea, I am satisfied that they are in no way necessarily connected with cancerous growths. Again, in some instances they are associated with fusiform corpuscles, and may be observed either to be identical in form and appearance with their nuclei, or as elongating to constitute that corpuscle itself—a transformation rendered very probable by their appearance in Obs. XXI., Fig. 54; Obs. XXII., Fig. 58; Obs. XXIII., Fig. 60; Obs. XXIV., Fig. 62; and especially in Obs. XXXIII., Fig. 82; Obs. XXXIV., Figs. 87, 88; and Obs. LVI., Fig. 150.

The true signification of these free nuclei, in some cases, it is very difficult to determine; for, whilst we may occasionally with Lebert consider them as fibro-plastic, in progress of development into fibres, and at other times the remains of broken down cells, the result of disintegration, there are other instances where the growth is advancing, and where there are no evidences to warrant either of these explanations. Thus, in Obs. XXXIV., they existed in an advancing nodule, which sprung from the cicatrix of a former wound; and, in Obs. XXXVII., they were tolerably uniform in size, and were present in great multitudes among the fibrous stroma of an increasing

<sup>1</sup> Die Diagnose der Bösartigen Geschwülste. 1847. P. 287.

growth. If connected with the fibrous element, it is easy to conceive that any of them remaining in a tissue may cause the return of a swelling in the cicatrix, or in the situation of a former tumour. On the other hand, I am unacquainted with any fact which proves that a growth so constituted ever possesses the power of spreading to other tissues, as is the case with cancer, although free nuclei, like cancer cells, may be infiltrated among fibrous tissue.

It is therefore probable, that as granules, which are in many respects identical, may be transformed into the nuclei of different textures; so nuclei, which are alike, may be connected with fibres or with various kinds of cells. Of the laws regulating these transformations we are ignorant; but as there are no granules distinctive of cancer nucleoli, so there are no nuclei distinctive of cancer cells. Moreover, the Observations alluded to show the necessity of considering nuclei as bodies distinct from cells. They may occur alone with fibres, producing a texture which may be called fibro-nucleated—(Figs. 87–97).

Kölliker and Henle<sup>1</sup> have described the occurrence of diaphanous bodies floating among various tissues. I have frequently seen these not only in cancerous and cancroid growths—(Figs. 75 and 130)—but in a variety of morbid products. They are very common in the fluid squeezed from the lungs in catarrh and other œdematous tissues. They may present a certain stage in the development of the nucleus, but are more probably nuclei enlarged by the endosmosis of fluid, a view which is favoured by the fact of their frequency in textures which are softened or infiltrated with serum.

### 3. CELLS.

There is no kind of cell formation which, at all times and under all circumstances, is capable of being distinguished from every other form of cell growth. Whilst this statement may be received as the expression of a fact of great importance, it is no less true that very characteristic differences may exist among cells, the study of which are of the utmost service in distinguishing one tissue from another. These differences principally depend upon the age or state of development, the situation in which the cells are formed, and a variety of concomitant circumstances, all of which are necessary to take into

<sup>1</sup> Zeitschrift für Rationelle Medicin. 1844. P. 190.



account before an accurate opinion as to their nature can be arrived at. It is the more necessary to point out this, because the inexperienced are very apt to suppose that a glance through the microscope, at any particular form of cell, is sufficient at once to determine the existence or absence of cancer.

The different kinds of cell which I have observed in cancerous and cancrioid growths, are the following—1. The cancer cell; 2. Epithelial cell; 3. Cartilage cell; 4. Compound granular cell; 5. Fibro-plastic and fusiform cell; 6. Pus cell. These names are certainly open to objection, but I have none other to substitute for them. One viewed by itself, we repeat, is often not to be distinguished from another. It is only when occurring in groups, or examined in relation to surrounding textures, that these terms become significative. Still an exact appreciation of each is of the utmost importance in the study of morbid growths.

1. *Cancer Cell*.—The so-called cancer cell occurs under numerous forms, presents very different appearances at different times, and is of variable size. The physical characters, so far as I have been able to determine them, are as follows:—In form, it may be round, oval, caudate, spindle-shaped, oblong, square, heart-shaped, or of various indescribable forms, from pressure on its sides. The external edge is generally sharp and well defined on the field of the microscope. In size, it varies in different specimens from the 1-100th to the 1-10th of a millimetre in diameter. The former size only occurs in a very early stage of its development; the latter, only when the cell is old and contains other cells. By far the most common size is when it measures from the 1-50th to the 1-30th of a millimetre in diameter—(Figs. 3 and 7). It is invariably destitute of colour, except in melanic cancer, when the pigment granules it contains tinge it of a light or dark bistre brown, passing into deep black—(Fig. 108). The cell-wall, when young, is smooth and distended—(Fig. 51);—when old, it is more or less corrugated and flaccid—(Fig. 30). Its contents are various. There is always one nucleus, often two, and sometimes they increase in number from three to nine—(Figs. 69–117). Most commonly there is only one, which is round or oval, generally the latter, and contains one or two granules or nucleoli—(Fig. 51). The nucleus, like the cell itself, varies in size, and may occupy from one-sixth (Fig. 51) to four-fifths (Fig. 69) of its volume. Between

the nucleus and cell-wall there is a colourless fluid, which, at first transparent, becomes afterwards opalescent from the presence of molecules and granules. Sometimes these are so few as not to impair the transparency of the cell—(Figs. 39–51); at others so numerous as to render it more or less opaque—(Fig. 34). I have never seen in the cancer cell the concentric circles figured by Lebert (*Planche* 18, Fig. 19), unless they are similar to one represented Fig. 32. On the addition of water, the cell-wall becomes distended by endosmosis, and is enlarged. Syrup and thick mucilage cause it to shrink and contract by exosmosis. When acetic acid is added, the cell-wall becomes more transparent—(Fig. 4), and in young cells is entirely dissolved—(Fig. 52); whilst the nucleus, on the other hand, either remains unaffected (Fig. 18), or its margin becomes thicker, and its substance more or less contracted—(Fig. 26). *Liquor potassæ* reduces the whole to an amorphous mass.

The mode in which the cancer cell is developed, offers one of the best examples of the endogenous growth and multiplication of cell within cell. At first, numerous molecules and granules are formed (apparently by precipitation) in the semi-fluid or solid blastema (Fig. 68), several of which coalesce or meet together to constitute a nucleus, which assumes a round or oval form. On this a cell-wall arises, and gradually enlarges. This cell-wall I believe to be sometimes formed by the melting together of molecules, precipitated upon, or attracted to, the nucleus, but more frequently by the expansion of the nuclear wall. In either case, it commences to enlarge and separate itself from the nucleus, by the endosmosis or assimilation of fluid from the surrounding blastema. Another nucleus may now often be observed arising within the cell wall, first assuming the form of a granule, which gradually enlarges until it presents the same form and size as the former one. Double nucleated cells are very common—(Figs. 3, 7, 11). Within each nucleus may now also be seen either one or two nucleoli, which sometimes form very early, and which hold the same relation to the nucleus as the nucleus does to the cell—(Fig. 3). One or both nuclei now enlarge; the nucleoli also augment in volume, and not unfrequently within these latter other granules may be seen forming, which, in their turn, enlarge—(Figs, 17, 28, 32). As the included nuclei grow and become transformed into cells, the original cell-wall becomes gradually atrophied, and dissolves or breaks down

into granules of disintegration—(Fig. 33); but in cases where the growth is rapid, it expands, and constitutes what has been called a mother cell, within which several cells, nuclei, and nucleoli, may be seen in various stages of development—(Figs. 32, 69, 117). It is by no means common for the cancer cell to reach such excess of development. More commonly they dissolve or break down before arriving at this, and their progress is often checked by the formation between the nucleus and cell-wall of numerous fatty molecules and granules, which at length fill up the cell, press upon the nucleus, and render it abortive—(Figs. 11, 28, 37, 43). This constitutes one of the modes in which the so-called “compound granular cell” is produced, of which I shall afterwards speak.

As the cell-wall becomes older, it seems to thicken and to be less easily affected by re-agents. When young it is readily dissolved in acetic acid; later, it is only rendered more transparent, and occasionally is scarcely affected. Vogel<sup>1</sup> speaks of the thick cell-wall assuming a fibrous character. This I have never seen. Neither have I ever observed any appearances which warrant the idea, that cancer cells are ever developed into fibres. They may become caudate, elongated, and throw out pointed prolongations, but they do not split up into filaments. It is probable that those who have described this occurrence as taking place, have mistaken fusiform or epithelial cells for them.

Küss<sup>2</sup> describes the mother cells as splitting up into smaller segments, and so multiplying by division. This I have never seen. It appears to me probable that he has mistaken cells impacted in masses of coagulated blastema for compound cells, which they greatly resemble. I am led to suppose this from having observed in one case (Obs. XIX., Fig. 50) an appearance very similar to what he has figured, where the addition of water, by separating the molecular matter of the blastema, liberated the imprisoned nuclei and cells. Bruch considers that secondary cells form within the parent one, not only endogenously, but by division of the nucleus. This opinion, which is favoured by numerous known facts in the development of embryonal cells and of plants, he supports by figures, in which the

<sup>1</sup> Pathological Anatomy of the Human Body, translated by Dr Day. 1847. P. 297.

<sup>2</sup> Recherches sur le Cancer, par C. Sédillot. 1846. Planche 7, p. 78.

nucleus is seen dividing in various ways. On the other hand, he denies that the cell-wall itself ever thus divides.<sup>1</sup>

The cause that cancer cells vary so much in appearance, structure, and size, is because the process of development is arrested at different stages. It is with a simple cell the same as with the most highly organized plant or animal. It may perish at birth, infancy, youth, or maturity, while comparatively few arrive at old age. The situation, and the amount of exudation or blastema thrown out, also influences their number, form, and size; while the degree of pressure to which they are subjected, more or less produces a similar result.

A question of great importance next arises, namely, is the cancer cell a new substance, or is it only a modification of cells pre-existing in the body? I have previously stated that, examined by itself, there is no possibility of distinguishing a cancer from many epithelial, cartilage, or embryonal cells. When, therefore, a cancerous growth involves a mucous membrane, the skin, or bone, it may be maintained that the cells contained in it are only excessive multiplications of normal structures. When the universality of mucous membranes is considered, how they line all hollow viscera, and permeate the various glands in which cancer is so common, the difficulty of disproving such a view becomes very great. In the liver also, in which organ the occurrence of cancer is frequent, the hepatic cells may easily be confounded with those of cancer in certain stages of their development; and I have often asked myself whether, in this situation, the morbid cells were not altered normal ones. This question, then, can only be solved by paying attention to a series of observations; and I think that those detailed in the first part of the work are both sufficiently numerous and varied to prove the following facts:—1st, That the cancerous, originates in the same nervous and vascular disturbances as the other forms of exudation: under the head of general pathology, the question of how far its peculiarities are owing to changes in the blood will be discussed. 2d, That cancer cells, in whatever tissue they be found, whether glandular, areolar, osseous, &c., present the same characters. And 3d, That it may be actually seen to arise in tissues altogether separate from epithelium or cartilage. Thus in Fig. 66 it is seen to occur among

<sup>1</sup> Bruch, Op. Cit., p. 282.

the filaments of a densely fibrous organ, the uterus, the mucous membrane of which was perfectly healthy; and in Fig. 68 it is carefully demonstrated to originate between the muscular and mucous coats; in fact, in the areolar tissue, below the epithelial basement membrane. It may therefore be doubted whether the true cancer cell be ever formed by transformation of a previously existing one. On the other hand, as we shall immediately see, the epithelial and cartilage cell may assume all the characters of that found in cancer, but a detection of their normal or anormal origin constitutes one of the distinctions between cancerous and cancroïd growths.

2. *Epithelial Cell*.—The different forms of epithelial cell (and epidermic, for they are identical), and the mode of their formation, is a subject which, relating as it does to a knowledge of the healthy tissues, I need not dilate upon; but it is important to know that a young plastic epithelial cell, when isolated and viewed by itself, presents all the physical characters of a cancer cell. This is especially the case when they have been lying some time in serum or other fluid, as often occurs with the cells lining the air vesicles of the lungs, the ventricles of the brain, the mucous coat of the bladder, &c. When studied, however, in mass, nothing can be more easy than to distinguish them. They have a disposition to run together in groups, to adhere at their edges, and are of tolerably uniform size—(Figs. 22, 111, 146, 147). Cancer cells, on the other hand, never exhibit a tendency to run together in groups, but are for the most part separated by a greater or less quantity of molecular and granular matter, either disintegrated (Fig. 3) or aggregated together (Fig. 50). They never adhere at their edges, and vary greatly in size. As epithelial cells become older, their dissimilarity becomes greater. They are then flatter, and resemble scales—(Figs. 109, 153). They are also more opaque, and more resistant to the action of acetic acid.

When epithelial cells constitute the principal portion of a morbid growth, as in Obs. XLI., XLII., LV., LVI., or as in any form of epidermic growth, such as corns, warts, scaly eruptions, &c., they become greatly compressed together, the external ones presenting a series of superimposed laminae (Figs. 114, 154); whilst the deeper are round, oval, spindle-shaped, or more or less altered in form from pressure (Figs. 111, 152), and are sometimes united into a firm

growth by compression (Fig. 151), or by filaments of areolar tissue (Fig. 112). Occasionally such growths soften, and ulcerate at their summit, especially on mucous membranes, when the superficial cells imbibe moisture, enlarge, and occasionally again present many of the characters of a cancer cell. Under these circumstances, like it, they may degenerate by the deposition of fat granules in their interior (Fig. 114), or they may split up and be converted into fusiform bodies and fibres before breaking down (Figs. 122, 145), which, as previously stated, a cancer cell never does.

3. *Cartilage Cell*.—Many young cartilage cells, when viewed by themselves, also present the physical characters of cancer cells; further, their mode of development is similar—so that at an advanced stage they resemble, with their included cells and nuclei, mother cancer cells. There will never be any difficulty, however, in distinguishing them in healthy adult articular cartilage, even when their size, form, and general appearance are similar; first, on account of the hyaline solid blastema in which they are imbedded; and secondly, on account of the great distinctness of their margins, and high refractive power of their nuclei. The morbid conditions of articular cartilage have not been very extensively studied; but, from the few opportunities I have had of examining them in instances where the joints have been diseased, I think it may be said, that even then its contained cells may easily be separated from those of cancer. Under such circumstances, the hyaline substance often becomes more or less opaque, from the deposition and crowding together of molecular matter, whilst the cells become partly or wholly filled with fatty granules. The general aspect of fibro-cartilage more closely resembles a cancerous growth, but will not readily be mistaken for it by an experienced observer.

The cells in morbid cartilaginous growths are large, and, as stated by Müller, more resemble those of the embryonal than of the adult tissues—(Figs. 106, 126). These, when they become separated by the disintegration of the hyaline substance, as is frequently observed in softened enchondromatous growths, more or less differ from the normal type, and often closely resemble cancer cells. Under such circumstances the solid hyaline blastema breaks down into a molecular fluid, the cells are liberated, become enlarged, and float in it, together with broken up fragments of the fibrous structure, should

any have existed—(Figs. 128, 131). I have observed in this case that water and acetic acid do not produce the same effect on such cells as on cancer ones, the former not causing them to swell out, nor the latter rendering the external wall transparent. In one case (Fig. 131) the cell was even rendered darker and more opaque.

4. *Fibro-plastic and Fusiform Cell*.—Under the term “fibro-plastic,” Lebert described a peculiar round or oval corpuscle, with a small nucleus, which has a tendency to elongate at both extremities, and to become transformed into fibres. These bodies I have frequently met with in all stages of their development, even in cancerous and canceroid growths (Figs. 62, 100, 102, 109, 110); but very often also in tissues, and under circumstances where the presence of cancer could not for a moment be thought of. Thus in a gelatinous polypus of the nose, removed by Mr Syme, in the Royal Infirmary, April 12, 1847, whilst the exterior was covered with pus globules and ciliated epithelium (Figs. 157, 158), the gelatinous interior consisted of delicate filaments, crossing each other at considerable intervals, in the meshes of which were round corpuscles, varying in size from the 1-100th to the 1-50th of a millimetre in diameter. These possessed a round nucleus, about one-third the size of the cell, which, on the addition of acetic acid, presented a series of minute granules—(Figs. 155, 156).

Fig. 155.

Fig. 156.

Fig. 157.

Fig. 158.

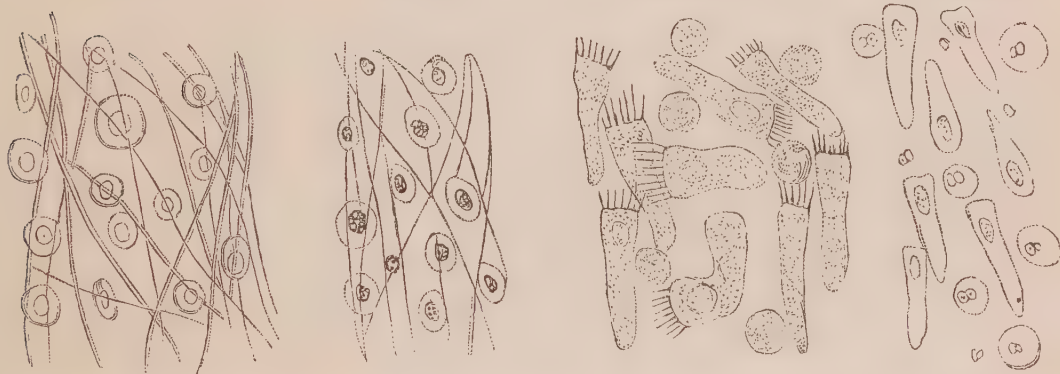


Fig. 155. *Fibro-plastic cells and filaments from the pulpy substance of a polypus of the nose, removed by Mr Syme.* Fig. 156. *The same, after the addition of acetic acid.* Fig. 157. *Ciliated epithelial and pus cells from the exterior of the polypus.* Fig. 158. *The same, after the addition of acetic acid.*

Again, in a case of pericarditis, which died under the care of Dr Robertson, and was examined in the Royal Infirmary, May 7, 1848, nucleated bodies were found in the coagulated exudation, sending

out several prolongations, splitting up, and dividing into fibres—  
(Fig. 159.)

Fig. 159.

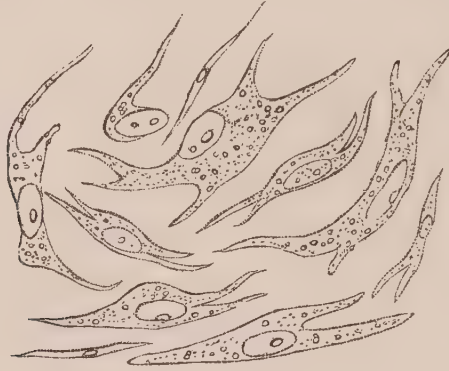

Fig. 159. *Fibro-plastic and fusiform cells from recent exudations on the pericardium.*

In these two instances, as well as in a multitude of others which might be brought forward, it is clear that fibro-plastic corpuscles are formed independent of all cancerous complication, and that cells so produced have the power, as originally stated by Schwann, of developing themselves into fibres. It is of great importance that this should be understood, because these very corpuscles are frequently associated with and mistaken for cancer cells, and tumours in which they abound have on this account been considered cancerous. Müller, however, to whom this error has been commonly attributed, distinctly says, when alluding to these bodies, “The caudate corpuscles are by no means peculiar to fungus medullaris; they may, indeed, often be observed in its substance, but often they do not exist in it, while they are as frequently met with in non-carcinomatous as in medullary growths.”<sup>1</sup> And again, “They probably depend only on the transformation of cells into fibres, and consequently are merely fibres in an early stage of development.”<sup>2</sup> It is Lebert who has paid the greatest attention to this form of cell, and pointed out the importance of distinguishing it from that of cancer.<sup>3</sup>

The round or oval fibro-plastic cell may, by elongation on one or

<sup>1</sup> J. Müller on the Nature and Structural Characteristics of Cancer, &c., translated by West. 1840. P. 19.

<sup>2</sup> Ibid. P. 20.

<sup>3</sup> Lebert, Op. Cit. Vol. II. P. 124.



both sides, become caudate, spindle-shaped, and at length fusiform—(Fig. 160).

Fig. 160.



Fig. 160. *Fusiform cells, with corpuscles from hypertrophy of the stomach.*

After a time, fusiform corpuscles, by being aggregated and compressed together, may produce a fibrous texture of considerable density, and by subsequently splitting up into fibres, occasion a true filamentous or densely fibrous tissue—(Figs. 102, 103).

The fibro-plastic cell may so closely resemble the young cancer and epithelial cell as not to be distinguished from either when viewed alone; but, by observing the form and character of the structures associated with it, and paying attention to the concomitant circumstances, it may in general be recognised. I have already dwelt upon the mode in which nuclei may be developed into fibres without forming the fibro-plastic cell.

5. *Compound Granular Cell.*—This form of cell is common in every kind of morbid growth, and is frequently associated with cancer in all its forms. It is of a round or oval shape, with a nucleus sometimes visible, at other times not. They vary greatly in size, for the most part measuring from the 1-50th to the 1-35th of a millimetre in diameter, although they are occasionally smaller, and sometimes much larger—(Figs. 37, 51, 69, 104). They sometimes contain a few granules only, at other times they are so completely filled with them that they assume a brownish dark appearance. Water and acetic acid cause no change in them, although the latter re-agent on some occasions renders the cell-walls more transparent. They are immediately soluble in ether, and break down into a molecular mass on the addition of potash and ammonia. On gradually pressing the perfect cell by means of a compressor, large drops, like those of oil, may sometimes be made to appear within the cell-wall, or to exude

through it, when it becomes more or less collapsed—(Fig. 161, *a, b, c*). By means of friction, the cell-wall may be ruptured, and its contents dispersed—(Fig. 162, *d, e*).

Fig. 161.

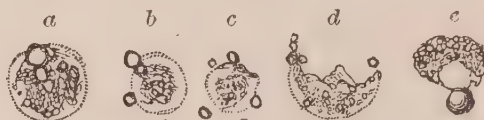

Fig. 161. Compound granular corpuscles acted upon by pressure. *a*, Some of the oily granules made to coalesce. *b*, Oil forced through the cell-wall. *c*, The same with collapse of the cell-wall. *d*, Rupture of the cell-wall. *e*, Dislocation of the nucleus.

The development of these bodies I have attentively watched in all forms of morbid products, but more especially in the softenings which occur in the nervous centres.<sup>1</sup> There it may be observed that the exudation first coagulates in minute molecules and granules; among which larger, colourless, transparent bodies are soon perceived. These are nuclei, upon which a cell-wall arises. Granules, nuclei, and cells may frequently be seen in all their stages of development, coating or encrusting the vessel externally, as seen in Fig. 162.

Fig. 162.

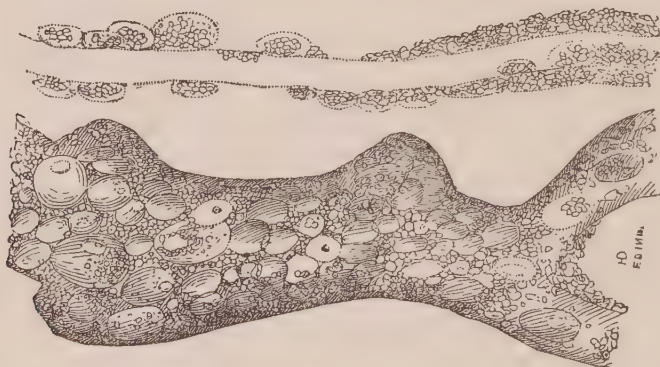


Fig. 162. Two vessels coated with granules, nuclei, and compound granular corpuscles, from a softening of the spinal cord.

Granules are generally formed in the cell, between the nucleus and its wall. These become more and more numerous, until at length the nucleus is obscured, and the whole cell appears full and distended with them. The cell-wall is now dissolved, and its contents escape. These changes are well seen in Fig. 163.

<sup>1</sup> See the author's "Pathological and Histological Researches on Inflammation of the Nervous Centres." 1843.

Fig. 163.

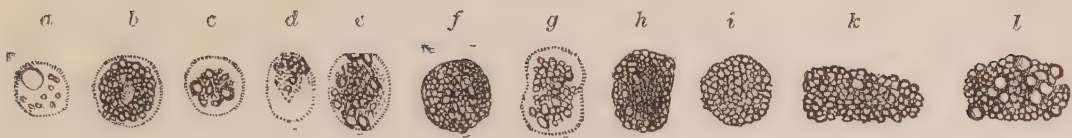


Fig. 163. Compound granular corpuscles and masses from cerebral softening. *a*, Nucleated cell with a few granules. *b*, Granules within the cell, partly obscuring the nucleus. *c*, Granules over the nucleus. *d*, Granules within the cell, no nucleus visible. *e*, Cell nearly filled with granules. *f*, Cell completely filled with granules. *g*, Cell contracted in its middle. *h* and *i*, Compound granular masses, the cell-wall having dissolved. *k* and *l*, Compound granular masses peeled off from the vessels.

Conjoined with the compound granular cell, there are often observed masses of granules cohering together, sometimes round, but frequently square, angular, or varying in shape, not surrounded by any membrane. (Fig. 163, *h*, *i*, *k*, *l*). These masses may sometimes arise from the solution of the cell-wall, but not unfrequently consist of portions of the coagulated exudation, which may frequently be seen under the microscope to break, and peel off from the vessels—(Fig. 164 and Fig. 163, *k*, *l*).

Fig. 164.

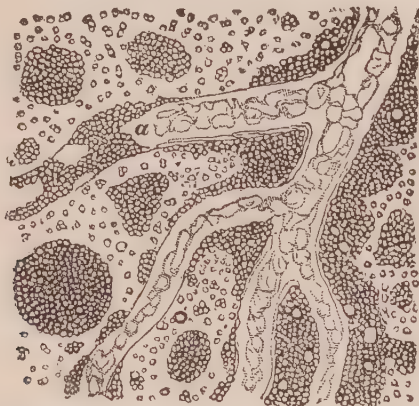

Fig. 164. Granules and granular masses from softening of the brain, filling up the intervascular spaces, and coating the vessel at *a*. The transparent nuclei of cells may be seen here and there among the granules.

The masses and cells just described are found in the exudative softening of parenchymatous organs, on the surface of granulations and pyogenic membranes, in the colostrum, accompanying pus corpuscles, and combined with cancerous, tubercular, encysted, and all other kinds of morbid growth. They were called by Gluge, who first described them, “inflammation globules;” Vogel denominates them “granular cells;” I myself, for a long time, called them “exudation corpuscles.” The term “compound granular cell,” as it involves no theory, seems to me to be the best.

The true nature of this cell has excited great discussion. For a long time it was conceived to indicate the presence of inflammation,

and its frequency in various kinds of exudation confirmed the opinion. The recent researches of Reinhardt<sup>1</sup> and Virchow,<sup>2</sup> however, have shown that there is no form of cell growth which, under certain conditions, may not exhibit numerous fatty granules in its interior, and resemble the different stages of the compound granular cell. In this manner, epithelial, cartilage, hepatic, pus, cancer, and indeed every other cell, may be transformed into the compound granular cell, by exactly the same series of changes that I have described above. These observations explain the frequency of this structure in so many different kinds of growth, and in such various textures and fluids, and prove that they are not so much evidences of exudation as of the fatty degeneration of all cell formations. These observers further point out this fatty transformation as sometimes commencing in the nucleus, or even the nucleolus when it is enlarged—a fact which I have had numerous opportunities of confirming, and which explains many of the appearances observed in cancerous and cancroïd growths—(Figs. 34, 75, 113, 114).

6. *Pus Cell*.—On examining well-formed pus under high magnifying powers, we find it to be composed of numerous corpuscles, floating in a clear fluid. These corpuscles are perfectly globular in form, and vary in size from the 1-100th to the 1-75th of a millimetre in diameter—(Fig. 165 *c*). Their surface is finely granular. They have a regular, well defined edge, and roll freely in the liquor puris upon each other. On the addition of water they become much increased in size, their finely granular surface disappears, and they become more transparent. Weak acetic acid partially, and the strong acid completely, dissolves the cell-wall, and brings into view the nucleus, which generally assumes the appearance of two or three granules close together, each with a central shadowed spot—(Fig. 165 *d*). They are generally about the 1-400th of a millimetre in diameter. Occasionally the nucleus may be thus seen to be composed of four, or even five, granules. Alkalies and ether completely dissolve the corpuscle.

<sup>1</sup> Reinhardt, in Traube's Beiträge zur experimentellen Pathologie und Physiologie. Heft II. p. 226: and in Archiv. für Pathologische Anatomie und Physiologie, &c. Heft I. p. 20.

<sup>2</sup> Virchow, in Archiv. für Pathologische Anatomie und Physiologie, &c. Band I. p. 142.

These corpuscles seem to be produced in the following manner:—The exudation first forms a molecular and granular blastema, the individual granules of which unite together in twos and threes, and constitute a nucleus, from which the cell-wall arises. The early stages of the formation of pus may frequently be observed in the coagulated masses occasionally squeezed out of unripe abscesses, and may also be seen in fluid exudation in the discharge from blisters and early purulent formations, following frictions with tartar-emetic ointment.

In grey hepatization of the lungs, and in minute abscesses scattered through other parenchymatous tissues, I have frequently seen the bodies just described as pus corpuscles to be surrounded by a distinct though very delicate cell-wall—(Fig. 165 *a*). The cell so formed

Fig. 165.

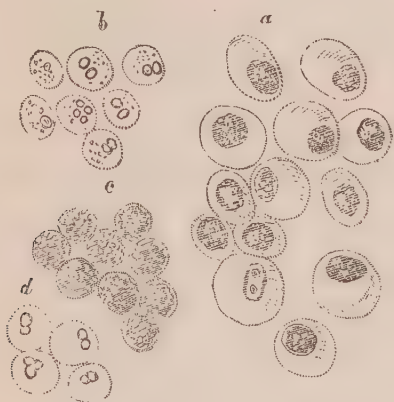

Fig. 165. *Corpuscles in pus.* *a*, *Corpuscles in grey hepatization of the lungs*; *b*, *the same after the addition of acetic acid*; *c*, *corpuscles in pus, from a subcutaneous abscess*; *d*, *the same, after the addition of acetic acid*

is about the 1-50th of a millimetre in diameter, and is highly elastic, assuming different shapes according to the degree and direction of the pressure to which it is subjected. Water and acetic acid cause the cell-wall to be at once dissolved, whilst the nucleus—which, before the addition of re-agents, exactly resembled an ordinary pus corpuscle—exhibits the usual two or three granules; which, under these circumstances, must be considered as nucleoli—(Fig. 165 *b*). Are, then, the bodies which have hitherto been considered as pus cells only the nuclei of corpuscles, the delicate walls of which are dissolved very rapidly, and at an early period? I have no hesitation in stating that this is the case in certain instances, but whether it be invariably so requires further observation to determine.

Pus, when formed on a mucous membrane, is frequently mingled

with epithelial cells in various stages of development. Some have spoken of mucous corpuscles, but there are no bodies peculiar to mucus. What have been described as such are sometimes those of pus, at others those of epithelium.

Pus cells may also be formed on a serous surface; in which case they are associated with filaments and corpuscles, which closely resemble,

Fig. 166.

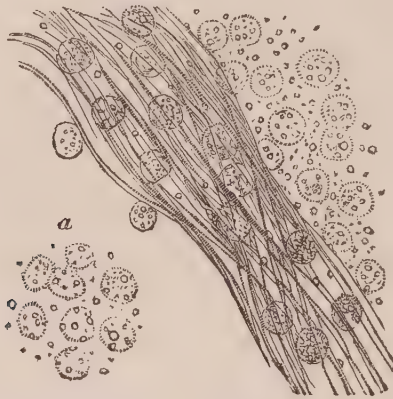


Fig. 166. Plastic corpuscles and filaments in recent lymph exuded on the pleura. *a*, The corpuscles unchanged by acetic acid.

and yet differ from them in structure. These corpuscles I have been in the habit of calling *plastic* corpuscles, from the frequency of their occurrence in plastic lymph. By Valentin and others they have been named *exudation* corpuscles; and by Lebert *pyoid*, from their resemblance to those of pus. They are composed of a distinct cell-wall, inclosing from three to eight granules—(Fig. 166.) They vary in size from the 1-100th to the 1-75th of a millimetre in diameter. On the addition of water and acetic acid, the corpuscles undergo no change—(Fig. 166 *a*); although sometimes the latter re-agent causes the cell-wall to contract and thicken, and at others to be somewhat more transparent.

Fig. 167.

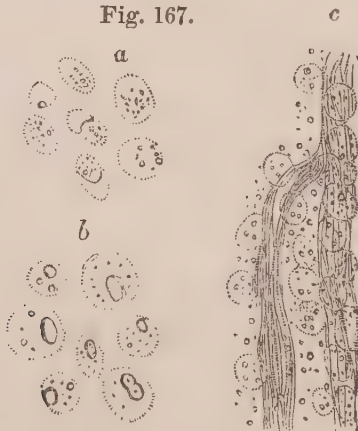


Fig. 167. Exudation from the surface of the peritoneum passing into pus. *a*, Isolated corpuscles; *b*, after the addition of acetic acid; *c*, plastic corpuscles and filaments.

There are some occasions when the exudation has been so abundant on a serous membrane, that it does not perfectly coagulate. The fibrinous and serous portions are not fully separated; and, under such circumstances, the corpuscles assume the character of pus, although some of the fibrous element, with plastic corpuscles adhering to them, may still be observed—(Fig. 167.)

Pus cells are occasionally found in the fluid on the surface of cancerous ulcerations, but I have never met with them in softened cancer of internal organs but in one case (Obs. XVIII., Fig. 44), when they were at once distinguished by the action of acetic acid—(Fig. 45). The same re-agent, by exhibiting the peculiar granular nucleus (or the nucleoli?) of the pus cell, at once distinguishes it from young cancer cells (Figs. 40, 52), young epithelial cells (Figs. 9, *a*, Figs. 92, *a*), and fibro-plastic cells—(Figs. 62, 110, 155, 160).

#### 4. FILAMENTS AND FIBRES.

Both cancerous and cancroïd growths generally have for their basis a fibrous structure more or less firm, which presents all the characters, and seems to be formed in exactly the same manner, as fibrous structure in healthy formations.

Sometimes the fibrous tissue consists of delicate filaments, not more than 1-600th of a millimetre in thickness (Figs. 6, 107, 138, 142, 143); at other times of well-formed areolar tissue, the diameter of each filament varying from the 1-500th to the 1-400th of a millimetre in diameter—(Figs. 1, 91, 97, 98, 103). It very frequently becomes more transparent on the addition of acetic acid, and presents visible permanent elongated nuclei—(Figs. 2, 10, 15, 57, 61, 94). Such fibrous tissue is evidently formed by the juxtaposition and ultimate development of the fusiform cells of which I have spoken. Occasionally the fibrous structure resembles elastic tissue, the filaments varying in size from the 1-300th to the 1-250th of a millimetre in diameter, and presenting the characteristic curled appearance—(Fig. 72). These various kinds of filaments are also arranged differently. Sometimes they are so closely set together, that they can scarcely be separated by the needle (Figs. 54, 60); at other times they are loose, widely separated, and easily torn—(Fig. 97). They may run together, side by side, in wavy bands (Fig. 98); be mingled together in an inextricable mesh-work (Figs. 72, 91); or arranged

in the form of loops or circles, surrounding openings or loculi—(Figs. 132, 138, 143).

Fibrous tissue is now supposed to be formed in three ways: 1st, by the precipitation in a fluid blastema of fibrinous molecules in the form of rows, which afterwards melt together, and become consolidated into filaments. This process may be well observed in the buffy coats of the blood (Addison), and in recent exudation on the surface of serous membranes—(Figs. 166, 167). 2dly, By the accumulation of granules, so as to produce by their meeting together a spindle-shaped nucleus, which by its elongation splits up the coagulated exudation into laminæ and fibres, as is observed in many forms of fibrous tissue (Henle)—(Figs. 19, 21, 35, 57). 3dly, The formation of a cell, which becomes elongated at both ends so as to form a fusiform corpuscle, which ultimately splits up into filaments, as frequently seen in chronic exudation on serous surfaces—(Figs. 100, 102, 159, 160) (Schwann). All these modes of formation are well observed in different cancerous and cancroid growths.

#### 5. BLOODVESSELS.

I have never observed any thing peculiar about the bloodvessels in cancerous and cancroid growths, and believe that they present the same structure, and are formed in the same manner, whatever that is, as in other tissues. In a few specimens of colloid cancer, I have sometimes thought that collections of bloodvessels existed as described by Vogel and Bruch; but I could never satisfy myself that these were surrounded by a membrane, or constituted a preliminary stage to the formation of a vessel. In one case (Obs. LIV. Fig. 144), a precipitation of molecules in the form of vessels, with blind extremities here and there, much resembled them; but there was no way of ascertaining whether these were really connected with the vascular system, or would ever have been so.

#### 6. CRYSTALS.

Crystals are not unfrequently found in cancerous and cancroid growths, especially if they have been kept any time, are partly decomposed, or occur on the surface of mucous membranes. They then assume the prismatic and other shapes of the triple phosphate,



and are the results of putrefaction. Irregularly formed crystalline masses are present in the structures, which undergo a calcareous degeneration—(Figs. 78, 143). Crystals of cholesterine are occasionally found in the reticulum of cancer—(Fig. 46), and sometimes needle-shaped crystals of margarine—(Fig. 48).

## CHAPTER II.

## CHEMISTRY OF CANCEROUS AND CANCROID GROWTHS.

THE chemistry of cancerous and cancroid growths, like that of tubercle and other morbid products, is in a very unsatisfactory condition. Indeed, the present imperfect state of organic chemistry renders any investigation with a view of arriving at results explanatory of pathological phenomena in such cases impossible. It is true that Simon, Scherer, Von Bibra, and other pathological chemists, have made a few analyses of cancerous and supposed cancerous tumours. All that can be determined, however, is, that they partake of the same constituent elements as other forms of exudation from the blood, and that not only are there no means of separating chemically the different forms of cancerous tumour from each other, but that it is also impossible to distinguish these from other morbid products, or even from healthy tissues. It appears to me that it is not by analysing large masses of morbid structure, including, as they do, granules, cells, filaments, and salts, mingled together, that any light will be thrown upon the chemistry of cancer; but rather by first separating, with the aid of the microscope, the minute structural elements entering into the composition of the growth, and then endeavouring, by chemical manipulations under the same instrument, to ascertain the exact nature of each. Chemists have not turned their attention in this direction to any great extent; but histologists are enabled, by the use of very simple reagents, to separate the chemical principles of cancerous and cancroid growths into four groups, viz., 1st, albuminous principles; 2d, fatty principles; 3d, mineral principles; and 4th, pigmentary principles. Further than this they cannot go; but, fortunately, a knowledge of the relative amount of these is easily obtained, and yields very important information.

## 1. ALBUMINOUS PRINCIPLES.

Under this head may be classed albumen, fibrin, and caseine; gelatine may also be considered with this group of principles, although it differs materially from the others. All of them have been said to exist in different kinds of cancerous and cancroïd growths. I have not endeavoured to separate one from the other chemically or structurally, believing it to be impossible in the present state of science. Albumen, it seems to me, constitutes the basis of the fibrous element found in morbid structures. Vogel and Bruch consider the solid parts to be fibrin, and the fluid in which the corpuscles swim to be albumen; and that the one is necessary to form filaments, the other cells. But even this view proves that fibrin must be transformed out of albumen, because, as has been previously seen, cells are developed into filaments.

Vogel put forth the general law that no blastema is organizable that does not contain fibrin; but the egg, notwithstanding the presence of sulphur, has no fibrin, which is the type of all organizable blastemata; and if the views of Zimmerman be correct, which I believe they are, it follows that fibrin results from some change occurring in albumen. This observer has well pointed out that there is no fibrin in chyme, and very little in the chyle; and, what is remarkable, much less in the chyle of carnivorous than in herbivorous animals, as horses and sheep. Fasting does not diminish its quantity in the chyle of horses; but, on the contrary, rather increases it, if we can rely upon the experiments of Tiedemann and Gmelin, who inferred that the fibrin must get into the chyle through the lymphatics. Since, then, there is no fibrin in the chyme of carnivorous animals, whilst it constitutes so large a portion of their food, one object of digestion must be the transformation of fibrin into albumen. Further, the blood of carnivora contains less fibrin than the blood of herbivora. Lastly, the experiments instituted by Magendie, Nasse, and others, who transfused blood deprived of fibrin into an animal, show that, after having circulated awhile, it contained fibrin, and was coagulable.<sup>1</sup>

Independently of the arguments thus cited by Zimmerman, there

<sup>1</sup> Zur Analysis und Synthesis der pseudo-plastischen Prozesse. 1844.

are others in support of his opinion. It seems extraordinary, for instance, that if the muscular and fibrous tissues are formed from fibrin, this principle should exist in normal blood only in the small proportion of from two to three parts in one thousand—a quantity wholly inadequate for the purpose. Again, we find the fibrin of the blood increased under circumstances where absorption from the tissues is very active, as in all diseases attended with exudation or emaciation, such as pneumonia, acute rheumatism, phthisis pulmonalis, &c. Heller has shown, that even in cancerous diseases the same change in the blood takes place. It seems, then, more rational to suppose, that nutrition is dependent on the existence of albumen rather than of fibrin in a blastema, and that this latter chemical constituent is more connected with the decaying than with the formative stage of life. If this opinion be correct, we must regard the increase of fibrin in the blood as an effect, rather than, as some pathologists have supposed, the cause of so-called inflammatory diseases.

Caseine is an albuminous principle, which seems to be of very doubtful existence in cancerous and cancroïd growths. Gelatine was proved to be present by Müller, especially in enchondromatous formations. It may also enter into the composition of colloid matter. I have sometimes found this coagulable on the addition of acetic acid, at others not. Some preparations of colloid in my possession, are still perfectly transparent after long immersion in alcohol; whilst others have been transformed into a white opaque matter, resembling boiled white of egg. Hence the chemical constitution of this viscous fluid in cancer often differs; but on what that difference depends has not yet been determined.

In a fluid state the albuminous principles are, with the exception of caseine, not affected by the addition of acetic acid; but when once coagulated in the form of molecule, fibre, or membrane, they are again rendered more transparent by the same agent. This property of acetic acid is a very valuable one for the histologist, as he is thereby enabled to give transparency to thin sections and filaments, and partly dissolve cell-walls. The filaments and cell-walls, therefore, of cancerous and cancroïd growths, are composed of the albuminous principle; and the more filamentous and dense the structure is, the more does it abound in this chemical constituent.

## 2. FATTY PRINCIPLES.

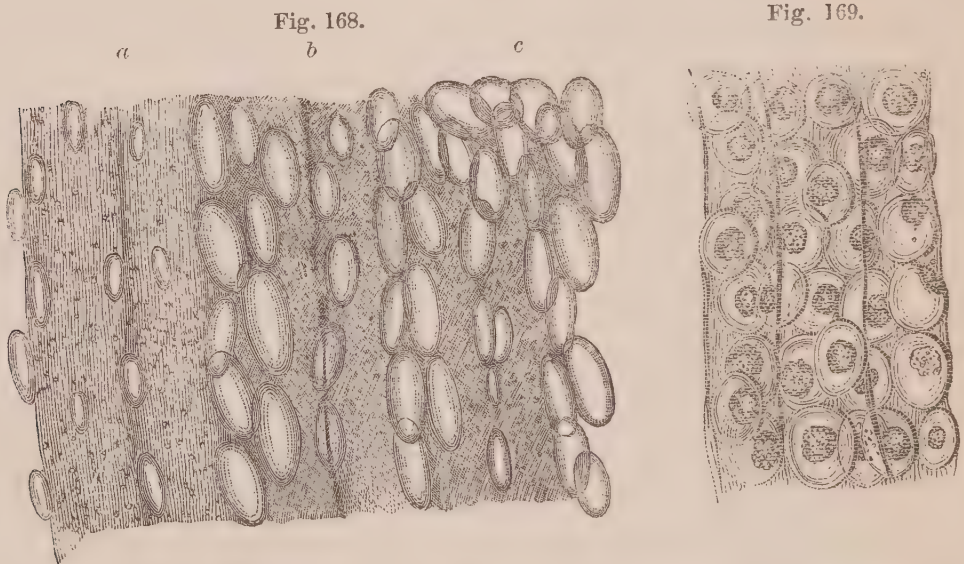
Fatty matter may exist chemically in cancerous and canceroid growths under four conditions, that is, free, saponified, non-saponifiable, and as fatty acid. Structurally it is never free; for, being invariably associated with fluid albumen, no sooner is oil precipitated so as to assume form, than the minutest granule of it becomes enclosed in a thin coagulated film of albumen. Such granules may be recognized by the resistance they offer to the action of weak acetic acid, or by their disappearance on the addition of ether; and their number, in any given point of a structure, is a tolerable index of the amount of fatty matter present. Fat may also exist in the form of crystals of cholesterine (Fig. 46), and of margaric acid (Fig. 48).

The two modes in which fat may be produced in the system—the one from matters introduced into the alimentary canal (primary digestion), the other from the decomposition of the tissues (secondary digestion)—have led to much discussion among chemists. The dispute between Liebig and the French chemists, in particular, has excited great attention,—the latter maintaining that fat enters the body ready made in the food; the former insisting that it is formed in the system. There can, I think, be very little doubt that it is produced in both ways: for, as it cannot be disputed that fat is one of the elements of food, so it cannot be doubted that animals, who grow excessively fat on grain, must possess some power of converting starch, gum, and sugar into adipose tissue. But in what part of the animal frame, in what tissue, and by what agency, this change is accomplished, we are ignorant.

It is probable that, under favourable circumstances, the albuminous principles may also be converted into fat; for pathologists are acquainted with numerous facts, which tend to prove that muscular, areolar, fibrous, and other albuminous tissues, may be so converted. The universal occurrence of compound granular corpuscles in old exudations, is the most common evidence of this; although it would, I think, be erroneous to suppose, that the original transformation is connected with any influence possessed by cells. *Donné*, after carefully removing all the globules from milk, and leaving no visible evidence of fat under high magnifying powers, still succeeded

in extracting it by means of ether. Fat, then, is probably held in solution, and enters the cell-wall by endosmosis; where it is precipitated in the form of granules, which become enveloped with a layer of albumen, and are prevented from passing out. In this manner fat, resulting from the disintegration of exudations, becomes accumulated in previously existing cells. Hence various kinds of these bodies act as mere storehouses for excessive formations of fat in morbid growths, as the adipose cells proper perform the same function in healthy tissues. In one, fat exists in the form of granules, in the other as a fluid oil, because pre-existing cells generally have for their contents albuminous matter in a state of solution, which is not the case with the adipose cells.

In the muscular system, and especially in the heart, I have watched the progress of fatty transformation with great care, and have convinced myself that it often commences in the very centre of the muscular fasciculus, apparently by the fibrillæ breaking up, losing their continuous and characteristic transverse markings, and assuming the form of minute fatty molecules, which afterwards become larger and larger, so as to constitute granules of various sizes. The same change is observed in muscles in the neighbourhood of diseased



*Fig. 168. Fatty degeneration of the psoas magnus muscle of a lad, who died with morbus corarius. a, The muscular fasciculi, in which no traces of transverse striæ are perceivable. The longitudinal striæ are still not quite obliterated, although mingled with numerous fatty granules. b, Muscular fasciculi, wholly composed of minute molecules and granules, with no traces of either transverse or longitudinal striæ. c, Fat cells of various sizes running between the fasciculi, and encroaching upon the fasciculi.*

*Fig. 169. The same after the addition of ether, which has dissolved the granules, causing the muscular fasciculi to appear very transparent. The fat cells are rendered round, and somewhat flaccid; the nucleus appears deprived of fat, and made up of a congeries of granules, of a brown bistre colour.*

parts, which, for a long time, have not been called into action—(Fig. 121). The whole fasciculus becomes thus affected, and at length large drops of oil accumulate in the interstices of the fasciculi, which gradually assume all the appearance of adipose cells, and, by their increase at the expense of the muscular fibre, communicate to it the yellow colour and other physical characters of fat. This conversion of the albuminous principle into the fatty, is brought about entirely independent of the agency of cells or nuclei, and shows that in the retrograde, as in the advancing process of nutrition, the molecular and granular element is the form of structure which is the basis of every other.

### 3. MINERAL PRINCIPLES.

In cancerous and cancroïd growths, as in every other form of exudation from the blood, there is present more or less mineral matter, the amount of which greatly varies in different cases. As previously stated, if decomposition has occurred, crystals of the ammoniaco-magnesian phosphate are not uncommon. More generally, we find here and there small collections of phosphate of lime in masses, consisting either of granules, (Fig. 46)—or of irregular fragments, (Figs. 78–143)—which are soluble in the nitric and hydro-chloric acids. Sometimes the mineral matter is so abundant, that a dried section of the growth is converted into an osseous-looking mass, (Obs. XIX.–XXXI.)—under which circumstances the same change takes place in cancer as in tubercle, and the former is converted into a calcareous concretion.

In some forms of cancroïd growth, the mineral principle, like the fatty, seems to enter pre-existing cells in a state of solution, and become afterwards precipitated, so as to assume somewhat of an organized appearance, as in Obs. XXXIII., (Figs. 81, 82, 83, 84)—and Obs. XLVIII., (Fig. 126.)

### 4. PIGMENTARY PRINCIPLES.

The different tints of colour presented by cancerous and cancroïd growths, seem to be owing to more or less extravasation of blood into their substance, which afterwards undergoes some chemical change, the nature of which is unknown. The pink, red, and brown tints, are evidently dependent on the amount of vascularity, or on hemor-

rhages of greater or less extent, recent or of long standing. Bright yellow matter is not unfrequently seen associated with fatty matter; sometimes in the form of a reticulum; at others, collected together in masses. Walshe<sup>1</sup> considers it may be analogous to the kirronosis of Lobstein; but Lebert<sup>2</sup> says it is a peculiar kind of fat, to which he gives the name of xanthose.

The black matter found in cancer has given rise to the terms melanosis and melanic cancer—(Fig. 108). I have ascertained, by experimenting on specimens in my collection, that the colour is destroyed by nitric acid and chlorine, a character which at once distinguishes it from the black matter which so commonly accumulates in the bronchial glands and lungs of old people, and in the black phthisis of colliers. In the latter case the black substance is undoubtedly carbon; in the former its nature is unknown. There can be little doubt that it originates in some change which the blood undergoes; for I have traced it frequently, in the same specimen, undergoing all the intermediate tints from blood red and rusty brown to the deepest black. It has been imagined to consist of sulphuret of iron, and the frequency with which old exudations in the neighbourhood of the intestines are tinged black, would at first seem to favour the supposition. But in a large specimen of melanosis removed from the anus of a horse, which, at my request, was tested for sulphuret of iron by Dr George Wilson as well as by Dr Douglas Maclagan, they both concurred in saying that no trace of it could be found. The true nature of this black pigment, therefore, is unknown.

<sup>1</sup> Walshe. *Op. cit.*, p. 82.

<sup>2</sup> Lebert. *Op. cit.*, p. 262.



## CHAPTER III.

GENERAL ANATOMY OF CANCEROUS AND CANCROID  
GROWTHS.

SEVERAL of the different elements described in the preceding chapters, unite to produce what have been called the forms of cancerous and cancroïd growths. These forms constitute mere arbitrary arrangements of morbid anatomists; and the names which have been introduced to distinguish them, derived from hardness, form, or resemblance to well-known objects, have thrown great confusion on the whole subject, and made discussions regarding them rather disputes about words than differences about things.

Previous to the work of Müller, the most general division of cancerous growths was into—1. Scirrhus; 2. Encephaloma; 3. Colloid; 4. Fungus hæmatodes; and 5. Melanosis. He, from the results of microscopic examinations into their structure, proposed the following forms:—namely, 1. Carcinoma fibrosum, sive simplex; 2. Carcinoma reticulare; 3. Carcinoma alveolare; 4. Carcinoma melanodes; 5. Carcinoma medullare; 6. Carcinoma hyalinum, seu fasciculatum. Vogel divides them into—1. Cellular cancer; 2. Fibrous cancer; 3. Melanotic cancer; and 4. Colloid cancer. Gluge speaks of three forms—1. Fungus medullaris; 2. Scirrhus; and 3. Cancerous ulcer. I fully agree with Dr Walshe in thinking, that there are only three forms of cancer properly so called,—namely, Scirrhus, or hard; Encephaloma, or soft; and Colloid, or jelly-like cancer. All the forms spoken of by other morbid anatomists may readily be comprised under one or other of these heads.

Cancroïd growths have hitherto not been recognized as a distinct class of morbid products. It is true, that numerous writers have endeavoured to draw distinctions between what has been termed fibrous and sarcomatous (simple cystic or pancreatic) growths, and

carcinoma. But daily experience evinces, that the most dexterous and experienced surgeons are unable, following the descriptions given, to distinguish these from cancer; nay more, that they give the name of cancer, or malignant, not only to those forms of growth, but to others which, however they may resemble them by their general symptoms and appearances to the naked eye, may easily be demonstrated to possess a widely different structure. Müller was the first to separate enchondroma as a distinct form of growth. Ecker and Lebert have distinguished epithelial growths; and the observations detailed in the first part of the work will, I think, demonstrate a new structure, which I venture to call fibro-nucleated, and which, to the naked eye, closely resembles sometimes scirrhus, and at others encephaloma. Fibrous, cartilaginous, fatty, and tubercular formations, may also be mistaken for cancer by good morbid anatomists, and are therefore sometimes cancroid.

#### CANCEROUS GROWTHS.

When we endeavour to define what a cancerous growth really is, according to the description of morbid anatomists, or the symptoms of medical practitioners, we are at once thrown into a crowd of inconsistencies, from which the sooner we emancipate ourselves the better. This can only be done by attaching the term cancer to some characteristic structure. Lebert has endeavoured to do this, and to establish that the existence of the cancer cell is pathognomonic; that it may be distinguished from every other kind of cell formation, and at once indicates the nature of a cancerous growth. The numerous observations I have made oblige me to differ from this excellent observer, and rather to agree with Müller in thinking that no single element is diagnostic. When, on the other hand, corpuscles, such as I have previously described under the name of cancer cells, are infiltrated among the meshes of a fibrous structure, in the same manner that pus cells are so infiltrated in a pneumonic lung; when such infiltration is not directly connected with a mucous or epidermic surface, and nowhere surrounded by a hyaline or fibro-hyaline substance,—then we may conclude, with tolerable certainty, that the structure is cancerous. Walshe<sup>1</sup> has called cancer an infil-

<sup>1</sup> Walshe. *Op. cit.*, p. 4.

trating growth, and his idea appears to me to have approached nearer the truth than that expressed by any previous writer.

It was the circumstance that no individual element was characteristic of cancer, that led Müller to maintain that there was no histological difference between it and healthy textures. The same facts have also induced Virchow to declare with him, that "carcinoma is no heterologous tissue, and its finer parts are not essentially different from the tissues of benignant textures and the primitive tissues of the embryo."<sup>1</sup> This dispute, as to whether a cancerous growth be heterologous or homologous (Laennec), heteromorphous or homomorphous (Lebert), arises from two modes of viewing the question. If any one individual element be chosen as the test of comparison, then it does not essentially differ from others existing in the healthy tissues, and the structure is *not* heterologous; but if several be chosen, and their relation to each other studied, then they differ from those in normal textures, and they *are* heterologous. Walshe well illustrates this when he says,—“The production of heterologousness may be understood, by considering that calomel and corrosive sublimate are certainly heterologous to each other; (for) though both are formed of atoms of mercury and chlorine, these atoms are differently arranged and combined.”<sup>2</sup> It is of the more importance that this point should be understood; because I find in an admirable work, extensively read by students and practitioners, that “microscopic observers say that, in their minute and original structure, there is no perceptible distinction between the most innocent and the most malignant growths; nay, that both agree in their primary corpuscular elements with the healthy tissues of animals, and even of plants. This very agreement, if it really be so complete, shows that, in *classifying* morbid growths, we must reject the aid of the microscope, and attend to their grosser and more palpable features.”<sup>3</sup> How different this from the statement of Vogel, who says,—“Our diagnosis must be based, not so much on the coarser physical characters—which, in cancer, are liable to extreme variations—as on the histological relations as viewed through the microscope.”<sup>4</sup>

Nucleated cells, then, presenting the characters previously attri-

<sup>1</sup> Virchow. Op. cit., p. 108.

<sup>2</sup> Walshe. Op. cit., p. 63.

<sup>3</sup> Watson's Principles and Practice of Physic. 3d edit., 1848. Vol. I. p. 217.

<sup>4</sup> Vogel. Op. cit., p. 314.

buted to cancer cells, infiltrated among the meshes of a fibrous stroma, constitute a tissue to which I give the name of cancerous. Conjoined with the fibres and cells there is invariably associated a viscous fluid; in which the latter, when demonstrated under the microscope, swim. The fibres, the cells, and the viscous fluid, constitute the three essential elements of a cancerous growth; and it is the relative amount of each of these which determines its peculiar form. If the fibrous element be in excess, it constitutes scirrhus, or hard cancer; if the cells be numerous, encephaloma, or soft cancer; and if the fluid abound, and be collected into loculi or little cysts, it is called colloid cancer. All these forms of cancer may frequently be observed in the same tumour,—in one place hard, or scirrhus; in another soft, or encephaloid; and in a third jelly-like collections, or colloid. Yet, although they may pass into or succeed one another, they are not unfrequently distinct from their origin to their termination. Hence each requires to be attended to separately.

### 1. *Scirrhus.*

This word, derived from the stony feel (*σκιρος*, a piece of marble) which characterises the structure, is applied to a morbid growth of great density and hardness, generally whitish, or of slightly yellow tinge, offering considerable resistance to, and often crunching under the knife. On examining a fresh cut section it most frequently presents a fibrous arrangement, but sometimes is tolerably smooth and friable. Greyish or pinkish pulpy masses may often be seen in the meshes of the fibrous texture, on careful inspection. On pressure it yields, when very hard, scarcely any fluid; but if in any degree soft, a milky juice may be expressed, more copious and more opaque according to the amount of softening. At all times a pulpy substance may be removed from a fresh cut surface by scraping, which, on a microscopic examination, will be seen to contain numerous cancer cells, mingled with molecules, granules, and fragments of fibrous tissue. This is the only method of distinguishing scirrhus from certain forms of fibrous tumour, which to the naked eye exactly resemble it. On making a thin section of the growth with a double-bladed knife, it is seen to be principally composed of filaments, which vary in size, and run in different directions, sometimes forming waved bands, at others an inextricable plexus, among which, however, the cells may be seen infiltrated, and at others forming

loculi or cysts, enclosing masses of these cells—(Figs. 1, 66, 72, 91).

Scirrhus is that form of cancer which gradually approaches and may even pass into a purely fibrous growth. It frequently softens, and in one or more points loses its density, and yields a copious milky fluid on pressure. At such times the softened portion is identical with the next form to be described.

## 2. *Encephaloma.*

This term, derived from the resemblance of the structure to brain (*ἐγκέφαλος*), is applied to a soft pulpy growth, of whitish, bluish, or yellowish tint, which breaks down under the fingers, and yields on pressure a copious milky or creamy juice. On examining a fresh cut section, it presents a fibrous texture, but very loose when compared with that in scirrhus. In the denser parts of the growth it approaches in character what is observable in the soft portions of scirrhus; but where it is pulpy and broken down, often no trace of fibres are visible, or at best mere fragments of them. The whitish cut surface is often more or less mottled with a greyish, pinkish, reddish, yellowish, or black colour. The two first are owing to different degrees of vascularity. The reddish spots are owing to extravasations of blood, of greater or less extent; and these, when very large, constitute what has been called by some surgeons *fungus hæmatodes*. The yellowish colour, when it surrounds bloody extravasations, is owing to imbibition of their colouring matter; but when reticulated over the surface, or collected in masses, it is generally dependent on fatty degeneration of the cancerous tissue, and forms the cancer reticulare of Müller. The yellow matter is usually of cheese-like consistence, friable, and often resembles tubercle, for which it has been mistaken. The blackish tinge is owing to the black pigment formerly spoken of, which may be infiltrated among the cancerous elements, and exist within the cells, constituting the malignant melanosis, or melanic cancer of authors.

A small portion of the cream-like fluid, examined with a microscope, always presents a large number of the cancer cells formerly described, which in some specimens of encephaloma reach a higher degree of development than in other forms of cancerous growth. These are mingled with a large number of molecules and granules, compound granular cells, blood corpuscles, and more or less of the

fibrous element. The fibrous structure is the same as that in scirrhous, but the filaments are often finer, and always more widely separated; while the pulpy matter and cells contained in the interstices are correspondingly increased. The yellow reticulum is sometimes composed of loose granules and compound granular cells (Fig. 11), at others of granules alone (Fig. 16), and not unfrequently, together with these, of nuclei disintegrated and altered in shape (Fig. 27). In melanosis the black pigment always exists in the form of exceedingly minute molecules, sometimes collected together within the nucleus, at others occupying the whole cancer cell, and always more or less infiltrated among the other elements of the growth—(Fig. 108). In some instances the encephaloma is more or less impregnated with irregular masses of mineral matter, and occasionally almost entirely converted into a calcareous substance.

### 3. *Colloid or Gum Cancer.*

The term colloid, derived from κόλλη (*glue*), is given to collections of gelatinous matter which resemble glue, calves'-feet jelly, gum arabic, and similar glutinous compounds of greater or less consistence, and are found in masses varying in size from a minute point to the size of the human fist, or even larger. In colour, colloid matter may be greyish, of a light or dark yellow, brownish, reddish, and rarely green or black. It may be clear and transparent like amber, or semi-transparent and opaque, resembling honey. It may be found disseminated in a fibrous texture, giving it a pearly aspect, or it may constitute the contents of distinct cysts. It is one of the most common constituents of compound encysted growths of the ovary, and is not unfrequently seen in cysts of the kidney and follicular swellings of the skin.

Colloid matter, distributed throughout a fibrous structure, presents numerous loculi, filled with a grey or amber-coloured glutinous matter, sometimes transparent, at others opalescent or semi-opaque. On examination with a microscope, the matter is occasionally found quite structureless, or exhibits only a finely molecular appearance. Under these circumstances the term *colloid tissue* has been applied to it. At other times numerous nucleated cells, presenting all the characters of cancer cells, in various stages of development, are found in it as a blastema; and we observe that the growth has a tendency to spread. This is colloid cancer.

When colloid cancer is formed on a free surface, as on the peritoneum, it often presents small grains, of a grey colour, resembling coagulated gum arabic. When collected in masses, these have an irregular nodulated aspect. A fresh section presents a surface with numerous loculi or cysts, which vary from the size of a pin's head to that of a walnut, filled with a clear glistening gelatinous matter, as above described, surrounded by fibrous substance or mesh-work.

Cancer cells originate in the colloid matter, as in other kinds of blastema, by the formation of granules, nuclei, and cells, the development of which are represented in Figs. 132 to 143 inclusive. The fibrous structure of colloid, so far as my observations have carried me, never contains permanent nuclei, or affords any evidence of being developed from nuclei or cells; it seems rather to be formed by precipitation alone. It has always appeared to me that the total absence of nuclei in the fibrous stroma, whilst the loculi are crowded with cells (Figs. 132—136), offers one of the weightiest objections to the theory of "germinal centres."

All the three forms of cancer now described are vascular, but in different degrees. Scirrhus is least so, but is still rich in blood-vessels. Encephaloma is always very vascular, and often to such a degree that it readily bleeds during life—(*fungus hæmatodes*). Colloid cancer is also well supplied with vessels, which ramify among the fibrous tissue. I have already stated that these forms pass into each other, and need only remark here, that this is often so imperceptible in several specimens as to render their classification with either very difficult. This is especially the case with scirrhus and encephaloma.

#### CANCROID GROWTHS.

By a cancrioid growth I understand a structure, which to the naked eye, the feel, and often in the progress of the case, so closely resembles a cancerous one, that it is commonly mistaken for it, and yet which presents on examination structural differences of a very marked character. Hitherto this distinction has not been very accurately attended to; for although practitioners have recognised the existence of fibrous, sarcomatous, warty, fatty, and other so-called non-malignant growths, experience every day proves that there are

no symptoms which enable them to detect these with certainty. It has consequently happened that various kinds of growths have been regarded as cancerous, and several have been operated on under the conviction that such was their nature, although very different from them in structure. In the first part of this work several such cases have been detailed at length.

There can, I think, be little doubt that one, if not the chief source of the contrariety of opinion which prevails on the subject of cancer, is owing to this mingling of various structures together under one name; and I consider that their accurate distinction in future will be the chief means of clearing up much of the difficulty hitherto experienced in practice. This can, of course, only be done by collecting together a body of cases in which the symptoms, morbid appearances, and minute structure, have been carefully examined and compared with each other. Facts at present are far too limited in number to allow me to do this with exactitude. In the mean time the following observations on the principal cancroid growths, although imperfect, may not be destitute of interest.

#### 1. *Fibro-Nucleated Cancroid Growth.*

I venture to give this name to a peculiar structure, consisting of filaments infiltrated with oval nuclei, as figured Obs. XXXIV., Figs. 85, 88; Obs. XXXVII, Figs. 95, 99; Obs. XLVII., Figs. 122, 124. I know of no means of distinguishing it except by a microscopic examination, as sometimes the growth exactly resembles scirrhus (Obs. XXXIV.), at others encephaloma (Obs. XLVII.). Yet, if difference in structure is to be considered of any weight at all, this peculiar growth ought to be separated from true cancer on the one hand, and fibrous growths on the other. It is deficient in what is essential to the first, namely, cancer cells, and possesses what is not found in the second, namely, numerous naked nuclei in no way connected with cell formation.

Free nuclei are frequently found associated with cancer, epithelial, and fusiform cells; and one might suppose that, were all fibro-nucleated growths soft and pulpy, they resulted from a retrograde process, and breaking down of the cell-walls which previously inclosed them. This is what doubtless frequently happens in true cancerous growths—(Figs. 63, 77). But we have seen this structure in hard advancing tumours *before* softening has taken place,



where no trace of cell-wall could be found, and where consequently such explanation does not apply—(Obs. XXXIV). Besides, in a true cancerous growth, the soft or encephaloid form always presents the most perfect specimens of cells; but in a fibro-nucleated growth the softening seems principally to affect the fibrous stroma, and to break it up. In the hard tumour of the mouth, however (Obs. XXXIV.), the nuclei were as numerous and perfect as in the soft tumour of the arm (Obs. XLVII.), and the semi-soft tumour of the parotid (Obs. XXXVII.)

Lebert has figured the nuclei described as belonging to fibro-plastic cells (Planche III., Figs. 14 and 15), but they seem to me to be very different from those he has represented in the same bodies at another place (Planche XIII., Fig. 1). If the reader will compare the nucleus of the fibro-plastic cell (Fig. 154, 157) with those represented in the fibro-nucleated growth (Fig. 85), he will observe that the latter are distinguished by their oval form, and the presence of single or double nucleoli. It is granted that they may be seen in some fibro-plastic cells at an early period of development, and in fusiform cells passing into fibres (Fig. 150), as well as in cancer and epithelial cells (Figs. 3, 145); but this only proves that there is nothing distinctive in the nuclei themselves. In short, in the same manner that we may have nucleated cells infiltrated among fibres to constitute a cancerous growth, so we may have nucleolated nuclei infiltrated among filaments to constitute a fibro-nucleated growth. This is undoubtedly the structure of many sarcomatous and osteo-medullary tumours, and ought to form a distinct variety of cancroïd growth.

A detailed history of these growths cannot be drawn up from the materials in our possession. It would seem, however, that they grow more or less rapidly, and if excised may return in the place originally affected. I am not aware that they ever occur secondarily in the glands or other organs. In Obs. XXXIV. the tumour examined was of seven years' growth, although stationary during the first six years. It originated in the cicatrix left by the removal of a former tumour from the thigh. It was hard and dense to the feel, grating under the knife on section; the cut surface smooth, of slightly yellowish tinge, and yielding no juice on pressure. Its texture was densely fibrous. In Obs. XXXVII. the growth was of twenty-one months standing, situated in the parotid gland, was pro-

nounced malignant, and allowed to run its natural course. Death was produced by paralysis of the nerves of deglutition. The tumour on section was of a yellowish-white colour, of tolerably firm consistence, yielding no cancerous juice on pressure, but containing a glutinous substance, which could be scraped from the cut surface by the knife. In Obs. XLVII., the tumour originated in the arm where the patient had been bitten by a horse seventeen years previously, and had reached a large size six months after it was first perceived. The growth was generally of pulpy consistence like brain, but firm in some parts. This was of yellowish-white colour, and did not yield a milky juice on pressure.

These three cases I believe to be in their nature similar, and to exhibit the progress of such fibro-nucleated growths, from the hard nodule at their commencement to the period of softening and disintegration. Obs. XXII., XXIII., XXIV., and XLIII., are probably instances of the same structure, although in these the nuclei seemed to have passed here and there into fibro-plastic bodies, exhibiting a transition stage between the fibro-nucleated and the purely fibrous cancroid growths.

## 2. *Epithelial Cancroid Growths.*

Surgeons, under the names of cancer of the lip, chimney-sweep's cancer, *noli me tangere*, malignant ulcer of the face, cauliflower excrescence of the uterus, and other appellations, have described growths, which although by them considered to be cancerous or malignant, in point of fact present a very different structure, and are therefore cancroid. Paget in 1838 pointed out the identity of several of these, considered them as warty in their nature, and ascribed them to hypertrophy of the papillæ of the skin.<sup>1</sup> Professor Simpson, in 1841, classes cauliflower excrescence of the cervix uteri with soft warts and condylomata, and states that the disease has often been confounded with carcinoma or medullary fungus. Examined by J. Reid and Goodsir, it was demonstrated and figured by the latter to consist of groups of large nucleated cells.<sup>2</sup> These, and similar alterations of the epidermic and mucous surface, are epithelial cancroid growths.

Epithelial growths essentially consist of an hypertrophy of the

<sup>1</sup> Medical Gazette, Vol. XXIII. p. 287. 1838.

<sup>2</sup> Edinburgh Medical and Surgical Journal, Vol. LV. 1841.

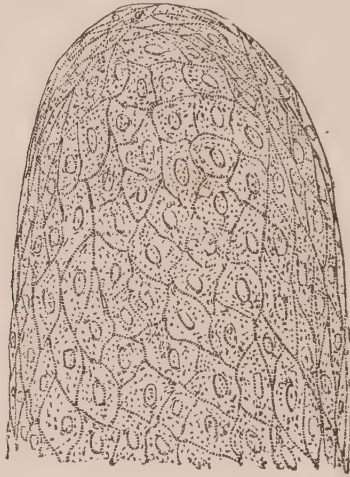
mucous or epidermic layer, which are composed of numerous epithelial cells more or less impacted together, presenting the characters I have previously described as characteristic of these bodies. They may occur on large free surfaces, such as the skin or mucous membranes of the alimentary canal, bladder, &c., or within follicles and the minute ramifications of secreting glands, such as the mammæ, kidney, &c. In the former case, corns, callosities, condylomata, warts, and scaly eruptions of the skin, or polypi and fungus excrescences of the mucous membrane, are occasioned. In the latter case they induce various kinds of encysted swellings, hairy and horny productions, and dilation of the minute ducts in secreting glands by the desquamation and retention of their contained epithelial cells.

The forms of epithelial growth which more especially resemble cancer, and which are therefore cancroïd, are, 1st, certain warty and fungus excrescences of the skin and mucous membranes; 2dly, some ulcerations of mucous membranes, especially those of the lip, tongue, and cervix uteri; and, 3dly, the changes occurring in follicles and excretory ducts, the latter, when associated with hypertrophy of the surrounding fibrous tissue, constituting some forms of so-called sarcomatous tumours.

1. The warty excrescences so frequently observed on the hands of young persons may also occur on other parts of the external surface, especially from irritation of the external parts of generation in both sexes. They are common also about the face and neck. Wherever they are found, they consist of a congeries of elongated papillæ, sometimes flattened at the top, so that they cannot be separated; at others presenting fissures or sulci which lead down to a common stalk. They may be small and rounded, or elongated and enlarged at their extremities. The tumours thus formed may vary in size from the bulk of a millet-seed, or even smaller, to that of an adult's head. Their surface is sometimes smooth, resembling thickened epidermis; at others is lobulated, composed of rounded groups of papillæ resembling externally a cauliflower. These tumours when small are almost wholly composed of epithelial scales, which assume a square or elongated form, their nuclei being for the most part very distinct. In the larger growths the surface is similarly compressed, but internally consists of a fibrous structure, into which loops of vessels from the capillary net-work of the dermis is prolonged. On

snipping off a small isolated papilla from such a tumour, and examining it entire, it presents a conical or round projection covered with epidermic scales, as in Fig. 170.

Fig. 170.



*Fig. 170. The summit of a papilla from an epidermic growth, the result of a burn, removed by Dr Duncan. Each papilla consisted externally of numerous epidermic scales distinctly nucleated, compressed together. Internally it was composed of fibrous vascular tissue.*

These tumours frequently soften and ulcerate at their surface, or round their base, when some of the epithelial cells enlarge from endosmosis, and often closely resemble cancer cells. Others become elongated, and split up into fibres. These changes are well observed in the case of chimney-sweep's cancer—(Obs. LV., Fig. 145). Mingled with the altered cells are numerous molecules and granules, and frequently pus corpuscles, giving to the fluid matter which covers and flows from the sore an ichorous character. In this manner a cancrioid ulceration may be produced of greater or less size, according to the number of warts and extent of the surface covered with them. The base of such ulcers is generally covered with papillated fungoid projections, between which the purulent matter and broken down cells collect, whilst the edge is elevated, indurated, and more or less ragged.

The epithelial growths on the surface of mucous membranes, called *polypi*, are covered externally with thickened epithelium cells, and are internally composed of fibrous tissue more or less dense, supplied with bloodvessels. In structure they resemble the warts and excrescences just described, and like them may ulcerate, which ulceration, however, is more apt to be attended with hemorrhage. Such polypi and growths are common in the os and cervix uteri. In

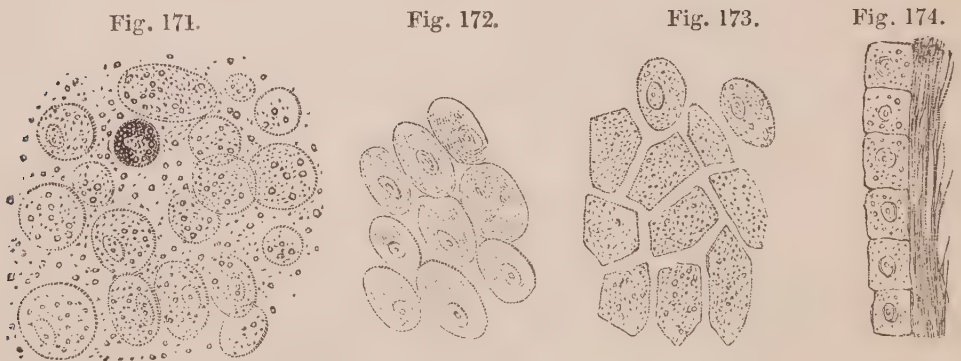
Obs. IX. a polypus was attached to the mucous coat of the bladder, which had become softened, and closely resembled a cancerous growth. I am, however, satisfied that it was cancroid—(Figs. 23, 24).

2. Another form of epithelial cancroid is one which frequently commences almost at the first as an ulcer, although sometimes it is preceded by slight induration of, or a small wart on, the part affected. It is common in the under lip, in the tongue, and in the cervix uteri. In the lip there may often be early observed a furrow or groove in the indurated spot or wart in which the ulceration commences. This slowly extends, with indurated, thickened, and raised margins, is circular and cup-shaped, its surface sometimes covered with a white cheesy matter, at others with a thick crust or scab—(Obs. XLI., XLII.) It slowly extends, until it involves a greater or less portion of the lip and neighbouring parts, pouring forth a foul ichorous discharge. In the tongue the disease follows a similar course; the base of the sore, however, is generally more fungoid or papillated on the surface, and exceedingly dense, owing to the close impaction and compression together of laminae of epithelium. These on section present a mass having a white surface, with a tendency to split up and separate, dense to the feel, and not yielding on pressure a milky juice—(Fig. 148). On the cervix uteri similar ulcers are very common, with hard irregular edges, yielding a copious ichorous discharge, and causing more or less thickening of the neighbouring textures. Such growths have frequently been excised as cancerous with a favourable result.

These forms of cancroid ulcers, when examined microscopically, present on the surface masses of epithelial cells in all stages of their development. Some spherical, nucleated, about the 1-50th of a millimetre in diameter, others much larger; both often resembling cancer-cells when viewed alone (Fig. 22, *a*), but associated with flattened scales, varying in shape and size, sometimes occurring in groups adhering at their edges (Figs. 22 *b*, 146), at others mingled together in a confused mass (Fig. 154). Many of the cells and scales often reach an enormous size (Figs. 22, 23, 151, 153), and as they become old split up into fibres. These elements are commonly associated with numerous molecules and granules, naked nuclei, fibro-plastic, fusiform, and pus cells. Immediately below the sur-

face the epithelial cells may be seen, more or less compressed and condensed together (Figs. 111, 152); and when the disease is very old and dense, these present concentric laminæ, surrounding a hollow space or a cell, evidently owing to the compression together of numerous epithelial scales. This peculiar appearance, when present, is characteristic of these growths—(Fig. 151).

3. Accumulations of epithelial cells and scales frequently occur among minute follicles and crypts, giving rise to cystic growths, as well as within the excretory ducts of glands, causing them to enlarge, to become obstructed, and also form cysts. Lebert has well described the former under the name of “encysted tumours of cryptous origin.” Their principal contents are epithelial cells in all their stages of development, young and spherical, or old and in the form of plates isolated or united together, associated with fatty cells and granules, and crystals of cholesterine. The accumulation of these matters within the follicle, blocks up the duct which leads from it, and it then commences to enlarge and assume a distinctly cystic character. Such cysts vary in size from a pea to that of a large orange, and present different appearances according to the amount of epithelium, fat, or cholesterine they may contain. Large quantities of epithelium are frequently thrown off from the lining membrane of the lateral ventricles of the brain in cases of cerebral meningitis, which, floating loose in the serum, present all the characters of cancer cells. I have made similar observations in cases of œdema of the lungs, and especially of ovarian dropsy, the fluid of which is often loaded with desquamated epithelium.



*Fig. 171. Well-developed cells in colloid matter of the ovary. Fig. 172. The same after the addition of acetic acid. Fig. 173. Similar cells, many-sided from compression. Fig. 174. The same cells attached to the internal surface of the fibrous cyst.*

In many fibrous, or so-called sarcomatous growths in glands, we

frequently find the hypertrophied filamentous tissue forming loculi, which vary in shape according to the amount of lateral pressure they receive. This may occur both in cancerous (Fig. 1), and cancroïd growths (Fig. 9), and the spaces so produced may be occupied by either cancer or epithelial cells. Hence, even on a microscopic examination, the latter may readily be mistaken by an inexperienced histologist for cancer. The fibrous tissue in both cases is the same, but the cells present the differences formerly pointed out between cancer and epithelial cells, the latter being frequently about the same size, and exhibiting a great disposition to run together in groups. The cystic formations in sarcoma are caused by the same circumstances which produce simple cysts in the liver, kidney, and other glandular organs. The minute excretory ducts are obstructed sometimes by extravasations of blood, or by granular exudation (Fig. 8), and fluids accumulating behind them produce dilatations of greater or less magnitude. Hence the frequency of encysted growths in tissues furnished with follicles or ducts. Occasionally the epithelium is so closely impacted in the dilated ducts, that on making a section through them with a double-bladed knife, they may be turned out in the form of moulds of the tubes. This is well seen Fig. 92. If the sections be not dexterously made, many of the cells escape, and look as if they were infiltrated among the fibrous tissue. This was done in Obs. VIII. Fig. 22, which I am now inclined to regard as an epithelial rather than as a cancerous growth.

This form of epithelial accumulation in the ducts of glands which are the seat of fibrous or sarcomatous growths, merits great attention, as to this circumstance must be attributed their great resemblance to cancer.

### 3. *Fibrous Cancroïd Growths.*

Fibrous growths are constituted wholly of fibrous or filamentous tissue, and so closely resemble cancer, especially the scirrhus form, as to be continually mistaken for it. The manner in which fibrous tissue forms I have previously described under the head of Histology. It may occur in various tissues and organs, and may be considered as the most common and universal texture to be found in the body, not only in healthy, but in diseased conditions. It forms the stroma, or framework as it were, of nearly all the tissues. We have seen it in almost every kind of cancerous and cancroïd growth; so that we

may regard a fibrous tumour as one of these, minus the nuclei and cells, which give to each its peculiarities.

Fibrous growths present themselves in numerous forms. One of the most common of these is that of *cicatrix*; another is that of the white glistening patch, so common on serous surfaces; a third is the chronic band or ligamentous tissue uniting serous membranes, the result of simple exudations of some standing; and a fourth is the peculiar induration of the skin, constituting sclerosis in young children, and the disease called elephantiasis in adults. Pressure of various kinds may convert muscular and nervous into fibrous textures, under which circumstances they gradually lose their own peculiar characters, and, associated with more or less fatty granules, split up, become condensed, and assume a filamentous appearance. This has been previously seen to occur in muscle (Obs. XXXVII., Fig. 99), and in nerve (Obs. XLVII., Fig. 125). None of these forms of fibrous growth, however, can be considered as cancroïd, and need not be dwelt upon at any length.

Cancroïd fibrous growths assume two principal forms,—1st, thickening or hypertrophy of the sub-areolar tissue of mucous membranes; 2d, tumours of different varieties.

I. Thickenings and indurations of the areolar tissue below mucous membranes, cause stricture and diminution in the calibres of hollow viscera, as in the urethra and alimentary canal. They may result from any kind of long-continued irritation producing exudation, and are thus common sequelæ of gonorrhœa in the first situation, and of dysentery in the second. Many cases of chronic gastritis induce the same lesion in the stomach, which may occasion great thickening of the areolar tissue between the mucous and muscular coats, generally accompanied also by hypertrophy of the latter. Of this lesion I have related four remarkable examples (Obs. XXI., XXII., XXIII., XXIV.), in all of which the disease was considered to be scirrhus, although it was, on careful examination, found to contain nothing but the elements of fibrous tissue. Many cases of stricture of the intestines, supposed to depend upon cancer, are in point of fact simply fibrous.

This form of cancroïd growth consists of dense bands of filaments, of a glistening or dull white colour, yielding no fluid on pressure, and frequently so hard and close as not to be separated by the needle,



and only to be examined by means of a thin section. This, on the addition of acetic acid, usually presents elongated permanent nuclei, of a spindle shape, scattered throughout the stroma—(Figs. 55, 57, 61). Here and there may frequently be detected among the fibres, naked nuclei varying greatly in size (Figs. 54, 58, 60)—or fibroplastic corpuscles (Fig. 62)—mingled with fusiform bodies. These elements may often be observed in the pulp removed by scraping a section, but become less numerous as the structure is more dense. In all cases of this kind the most careful examination is necessary, and repeated sections should be made. It must be remembered that the difficulty does not consist in showing the presence of fibrous tissue, but in proving the absence of cancer cells.

II. The second form of fibrous cancroïd growth is that of tumour, under which head must be classed a number of structures, hitherto denominated sarcoma and neuroma, as well as those usually called fibrous. They all consist of a fibrous structure in different stages of its development, the softer and more vascular forms being such, even when its elements have not yet completely passed into the perfect development of fibres. For this reason they have been made to constitute a distinct group by Lebert, under the name of fibro-plastic tumours. Such growths, however, may always be seen passing into true fibrous tissue. In some, whilst one part of a tumour may be called sarcomatous, or fleshy, another is truly fibrous. The difference is only one of development, and cannot therefore constitute a good ground of distinction. Other kinds of fibrous tumour resemble tough ligament and fibro-cartilage, presenting all kinds of intermediate degrees of conversion between the areolar and elastic tissues. Fibrous tumours, therefore, may be divided into, 1st, sarcomatous; 2d, desmoid; 3d, chondroid; and 4th, neuromatous fibrous tumours.

1. *Sarcomatous Tumours*.—These tumours are either spherical, or more or less lobulated (pancreatic sarcoma of Abernethy). The first are of the consistence of muscular tissue, or very soft cartilage. On section, they present a smooth or finely granular surface. Their colour differs from a yellowish white to a rose pink or deep red, dependent on their amount of vascularity. Occasionally a section presents different colours, the external portion being more vascular than the internal, or it is more or less mottled, the red tint alternating

with the yellow. At other times the section presents several ecchymotic spots, varying in size, caused by extravasation of blood from the capillaries. Owing to the vascularity of these tumours, there is a disposition to ulceration, and breaking down of their substance, with formation of a purulent fluid.

These tumours are generally surrounded by a distinct cyst. They frequently originate in the cellular tissue, and are commonly found in fibrous and osseous structures. In the latter case they have received the names of osteo-sarcoma, although many tumours so called are, in point of fact, of a cancerous nature. According to Lebert, the fungus of the dura mater belongs to this class of tumours. For the most part they increase in size slowly, only causing inconvenience from their size, or by pressing on neighbouring nerves and tissues. Owing to this pressure, they may induce absorption or ulceration of neighbouring parts.

Not unfrequently these tumours are more soft and lobulated, and have frequently been mistaken for encephaloma. The lobules vary greatly in size, and present externally a papillary or cauliflower character, frequently resembling the pancreas, and hence the name given to them by Abernethy. Occasionally the lobules are surrounded by a layer of areolar tissue, more or less dense. They are for the most part of a greyish, yellowish, or rosy colour, their tint varying with their amount of vascularity.

These tumours are also found in many places richly furnished with cellular and fibrous tissue, as below the skin. They are not unfrequent in the mamma, where their diagnosis from scirrhous constitutes one of the nicest points of diagnosis in surgery. They constitute small mushroom-like growths on the conjunctiva (*Lebert*), and may destroy the eye from the pressure caused by their enlarged size. I have found many granulations on the valves of the heart to consist of sarcomatous or fibrous structure. Many granulations on the surface of wounds approach them in nature.

The minute structure of these tumours is essentially fibrous, but many of the fibres are seen to be made up of congeries of fusiform cells closely applied together. These cells are of a spindle shape, varying in length and breadth, for the most part distinctly nucleated. Many of them may be seen branched at their extremities and passing into fibres, according to the mode of development of fibrous tissue described by Schwann. In some, the nucleus will be found

to have disappeared. Other of the cells will be found round or oval, or only slightly elongated. These are younger growths. In the same tumour all these different stages may be observed. In the softer parts, isolated cells and nuclei abound; whereas in the harder and denser parts, the development into fibrous tissue will be found more perfect—(Figs. 100, 102, 103).

Fig. 175.

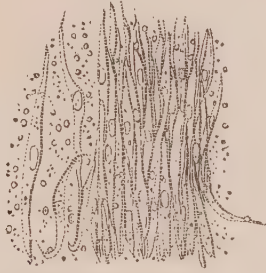

Fig. 175. Fibrous tissue composed of fusiform cells from a sarcomatous tumour of the kidney.

In many of the softer forms of sarcomatous tumour, especially when they contain cysts (cystic sarcoma), groups of very transparent cells may be observed, which, on the addition of acetic acid, present a distinct round nucleus, about one-third the size of the cell. These, when viewed isolated, appear like fibro-plastic cells in an early stage of their growth, but when viewed in mass closely resemble epithelium. The fibrous structure is often arranged so as to form loculi (Fig. 10)—which may be seen crowded with these cells (Fig. 9). Sometimes they assume the form of round rolls, and have evidently been squeezed out of some duct; at other times a section of the growth exhibits these ducts enlarged, and gorged with them—(Figs. 93, 94). In such cases epithelial and fibrous growths are conjoined.

2. *Desmoid Fibrous Tumours*.—These tumours are generally of a white colour, more or less tough and elastic, resembling the well-known structure of the dermis. This, indeed, is not so apparent in examining the comparatively thin human dermis; but on looking at that of some of the larger animals, and more especially that of the whale, the analogy in structure at once becomes evident. These tumours are of a rounded or oval form, frequently imbedded in a cyst, composed of the indurated structures in which they lie. They are of considerable density, varying from that of tendon to that of ligament or fibro-cartilage, and on section present numerous white glistening fibres, intimately interwoven together, or arranged in bundles constituting circles, or loops intercrossing with each other.

Occasionally they have a bony centre or nucleus. Their colour is generally white, but occasionally they present a yellowish tinge. They are for the most part not very vascular, although there is great difference in this respect; some approaching the pinkish colour of sarcomatous growths, and others being of dead white and of extreme density, containing scarcely any vessels. They vary greatly in size, from that of a pin's head to a circumference measuring several feet. I have, in my collection, the half of a fibrous tumour which measured four feet in circumference; and in the museum of the College of Surgeons is a model of one from a case described by Dr Mackintosh, which was much larger.

These tumours may be situated in various tissues and organs, as in the subcutaneous cellular tissue, in the mamma and uterus, where they are common, and in the submucous tissue. When developed in the latter position, they push the mucous membrane forwards, which yields with them. In this way they grow outwards, and frequently form one kind of the so-called polypi. At other times they grow towards the serous or internal cavity, pushing the membrane before them in the same way, so that it ultimately constitutes a neck or pedicle, by which they are attached. Such pediculated fibrous tumours are frequently found in the peritoneum, growing from the uterus. Occasionally the pedicle breaks across, and the tumour becomes free in the serous cavity. I possess a fibrous tumour with a bony-looking nucleus, found loose in the cavity of the peritoneum. It was found in an anatomical subject by Dr John Reid, and, at one point, has the indentation well marked where the pedicle had been attached. To the same cause are owing the small fibrous oval or round bodies, called loose cartilages, found in the joints, more especially that of the knee, and those found in the veins, denominated *phlebolites*.

The minute structure of these tumours is found to consist of fibrous tissue, composed of filaments varying in diameter from 1-700th to 1-800th of a millimetre. In the softer portions of the tumour they can easily be separated by needles, but in the indurated portions they are so dense that this is impossible. Sometimes the filaments are more or less waved, as in ordinary fibrous tissue; at others, they are curled and brittle, as in elastic tissue.

Occasionally we find fusiform nucleated cells, showing that many of those fibres were probably formed by development from cells.

Sometimes isolated nuclei and corpuscles may also be found, as in the sarcomatous tumours; but the proportion of them to the fibrous element is always small.

Fig. 176.




Fig. 176. Section of a desmoid fibrous tumour from the uterus after the addition of acetic acid.

The bony nuclei of such tumours are composed of amorphous mineral matter, a very beautiful example of which was given to me by Professor Syme, thin sections of which are preserved in my museum. Lebert, however, says, that on two occasions he has seen true bone produced. One of these is in the possession of M. Miescher of Basle. A thin section made of the nucleus of the tumour found by Dr John Reid, above alluded to, made for me by the late Mr Sanderson of this city, exhibited under the microscope large cells, closely resembling the pith in certain plants, and which were evidently cartilaginous. Those of the circumference were loaded with granular mineral matter, so as to form a firm external case. Thus the hard nucleus of these growths may sometimes be cartilaginous.

3. *Chondroid Fibrous Tumours*.—These tumours were first accurately described by Müller, and determined by him not only to resemble cartilage in appearance, but to possess a considerable amount of gelatine, whence their name. They vary in shape; on section, present a smooth milkwhite glistening colour, like fibro-cartilage, which texture they exactly resemble in their physical properties. The substance is very dense, separated with great difficulty by needles, but easily cut into thin layers. It crunches under the knife, and is very little vascular.

Its minute structure is found to consist of dense fibrous tissue, resembling the fibro-cartilage of the ear, or intervertebral substance.

The various kinds of fibrous growth now spoken of may frequently be found associated together in one tumour. Some are composed of several rounded or oval masses, varying in size, and surrounded and separated from each other by a cyst, or layer of areolar tissue. The external surface, under such circumstances, is more or less nodulated. It may frequently be observed that some of these nodules are soft and pulpy,—semi-gelatinous, with a very sparing layer of fibrous tissue; whilst others may be seen more or less tough, gradually passing into a fibro-cartilaginous density, grating under the knife. Nay, even in one nodule we have frequently observed some parts of it soft and others hard, and shown that the softer parts are mostly cellular, and the harder fibrous, and that between the two there is every degree of variation—(Obs. XXXVIII).

4. *Neuromatous Fibrous Tumours*.—This form of fibrous tumour is developed in the nerves, sometimes spontaneously, at others is the result of injuries, and more especially of amputation.

In the museum of the Richmond Hospital, Dublin, is a most remarkable series of preparations, taken from an individual in whom almost every nerve of the body presented knotty swellings. In some places these were developed into tumours, which varied in size from a nut to that of the human head. On examining them microscopically, which the kindness of Dr Smith enabled me to do, I determined them to consist of fibrous bands, running in various directions, mingled here and there with compound granular masses. As the specimen had been long kept in spirit, nothing more than its fibrous elements could be determined.

In some fresh neuromatous tumours, however, which I had an opportunity of examining through the kindness of Dr Duncan, it was clearly demonstrated, that in addition to bands of fibres running in waved lines, and sometimes forming loops, there were occasionally transparent cells, with a nucleus composed of two or more small granules, not affected by the addition of acetic acid. These cells, I am inclined to believe, were those of cartilage.

#### 4. *Cartilaginous Cancroid Growths*.

Cartilaginous growths were first described and separated from

cancerous and osteo-sarcomatous tumours by Müller, under the name of *enchondroma*. When found in the soft parts, or merely attached to bones, they are surrounded by an envelope of condensed areolar tissue, when in the bones by a bony capsule. In the first case they occur, although very rarely, in the glands, as in the parotid or mamma. In the second case they are most common in the bones of the extremities. When formed in the substance of long bones, they present rounded, smooth tumours; when in the periosteum or flat bones, their surface is rough and nodulated.

Müller, in addition to gelatine in enchondroma, discovered a peculiar matter which he denominated *chondrine*. He afterwards found the same substance to exist in the permanent cartilages. It is extracted by boiling, when a gelatinous substance is obtained, which forms a jelly on cooling that yields a precipitate on the addition of alum, sulphate of alumina, acetic acid, acetate of lead, and sulphate of iron, which ordinary gelatine does not.

In structure enchondroma presents all the characters of cartilage, that is, transparent nucleated cells, varying in size, isolated or in groups, situated in a hyaline substance. A network of filamentous tissue runs through the substance of the tumour, forming areolæ, in which bloodvessels ramify. Within the areolæ so formed, the cartilage is found. This structure is beautifully seen in an enchondromatous tumour of the arm in the University Museum of this city, which was amputated by Mr Miller, and successfully injected by Mr Goodsir. The cartilaginous and areolar tissues vary as regards amount in different tumours. Sometimes the cartilage is in excess, when it resembles that in young animals or in the foetus, the cells being unusually large. At others the fibrous element abounds, when the whole is similar in structure to fibro-cartilage. This is what happens in many neuromatous tumours formerly alluded to. Between these two extremes there are infinite varieties, and not unfrequently they may all be seen in one tumour.

Occasionally a bony nucleus may be observed in a nodule of enchondroma, and sometimes these nodules may be observed in all stages of transformation into perfect bone. Many so-called exostoses are owing originally to an excess of cartilaginous growth.

Notwithstanding the marked characters presented by these tumours, the peculiarities of structure which distinguish them, and the time that has elapsed since the attention of the profession was

directed to them by Müller, they are even now continually mistaken for cancerous or osteo-sarcomatous growths by surgeons. They frequently soften, and under such circumstances present all the external characters of encephaloma. This softened portion, even when examined with a microscope, may, without great care, lead to error, as the cartilage cells which then float loose, mixed with granules and the debris of the tumour, closely resemble those in cancerous growths—(Figs. 128-130). In one case (Obs. XLVIII.) I determined that acetic acid rendered the whole cell more faint, instead of exhibiting a marked difference between the nucleus and cell-wall, as in the case of cancer. In another case (Obs. XLIX.) the whole cell was rendered darker on the addition both of water and acetic acid.

In Obs. XXXIX. a peculiar form of enchondroma is described, removed from the neck, over the parotid. The cartilaginous substance existed in small white nodules, scattered through the substance of the tumour, presenting the usual characters of enchondroma—(Fig. 106). These were surrounded by a moist, pulpy, yellowish matter, exactly, as stated in the report, like the fresh cut surface of a potato, which consisted of isolated nucleated cells, and numerous compound granular corpuscles—(Fig. 104). This form of cartilaginous growth is very different from those I have ever had an opportunity of examining in the museums of this country or on the continent, nor can I find any description published which appears to me similar to it.

##### 5. *Fatty Cancroid Growths.*

A fatty growth may be thought at first sight very difficult to mistake for cancer; but in the form of tumour, when mingled with fibres and other elements, experience has proved the occurrence to be far from uncommon.

Fatty tumours vary in size, but may reach a growth weighing upwards of 30 lbs. Sometimes their surface is smooth, at others lobulated. They are of a yellow colour, resembling adipose tissue; sometimes divided into bands by white fibrous tissue. The relative amount of these two elements varies greatly in different specimens; some being soft, oily, containing few fibres; others being harder, dense, the areolar tissue preponderating. For the most part they are very sparingly supplied with bloodvessels, but these abound



more in the fibrous varieties. In the latter case they are liable to ulcerate, and, under such circumstances, have frequently been mistaken for cancer. Some of these growths, indeed, may be considered as fibrous or sarcomatous tumours, combined with an unusual quantity of fat. Occasionally they are connected with the ordinary adipose tissue of the body. We see this in the fatty tumours so common in the subcutaneous tissue. They are often surrounded by a delicate cyst or envelope; at others this is not perceptible. When the collection of fat resembles the ordinary adipose tissue, the tumour has received the name of *Lipoma*. When it is more lardaceous, some have applied to it the term *Steatoma*, in the same manner as when the substance is encysted.

The minute structure of these tumours varies according to the amount of adipose or fibrous tissue in their composition. The adipose matter is composed of vesicles of a round or oval form, more or less liable to undergo alterations in shape from pressure. They generally vary from the 1-20th to 1-50th of a millimetre in diameter; but I have frequently seen them measure 1-10th, or even 1-7th of a millimetre in their longest diameter. They are composed of a diaphanous cell-wall, frequently including a nucleus. The nucleus is frequently round or oval, about the 1-100th or 1-200th of a millimetre in diameter. Occasionally it appears stellate, of a crystalline aspect, from the formation of crystals of margarine or margaric acid around it—(Fig. 177, *a*). On rupture of the cell-wall the oil may be made to flow out loose, and the cell-wall puckers or shrinks up. Such collapsed cells may frequently be seen among the more perfect formations, mixed with globules of oil and fat granules.

Fig. 177.

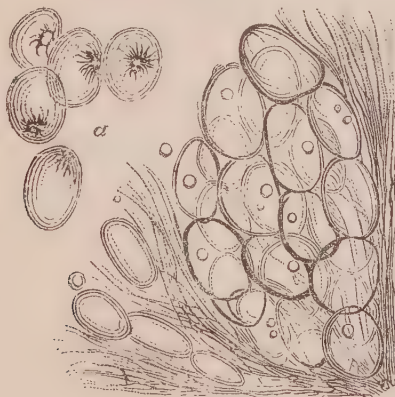


Fig. 177. Structure of a fatty tumour removed from the back by Mr Syme. *a*, Isolated cells, showing crystalline nucleus of margaric acid.

The fibrous element presents the usual appearance of filamentous tissue running between groups of adipose cells, but is denser, and occupies greater space, according to the proportion with which it enters into the tumour.

Steatomatous and melicerous fatty matter may sometimes consist principally of the cells just described, or these may be mingled in various proportions with granular matter. In some melicerous encysted matter, we have found the whole to be composed of granules, among which faint traces of delicate cell-walls might be observed more or less compressed together. In all such productions the relative amount of the vesicular and granular element varies greatly.

Fig. 178.

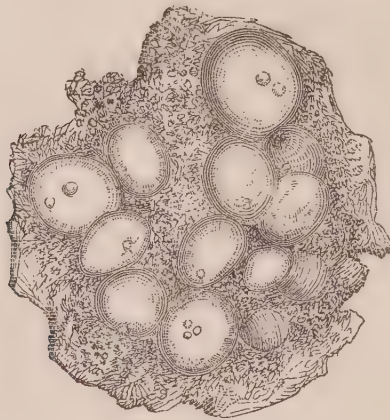


Fig. 178. *Fat cells and granular matter, from a steatomatous tumour of the ovary.*

Another form in which fat may occur is that of atheroma, consisting, for the most part, of numerous fatty granules, varying in size. It may constitute the contents of cysts, or the entire degeneration of certain glands, especially the mesenteric and lumbar. We have frequently seen these glands entirely converted into a dark, ochry, cheesy substance, which, on examination, was found to consist of numerous granules, varying in size from 1-600th to 1-400th of a millimetre in diameter—(Fig. 179.) They almost entirely disappear on adding ether, leaving behind only a molecular albuminous matter. Such an appearance is common in the contents of cystic tumours, in the Fallopian tubes, and many other situations. Similar fatty granules are also found associated with most morbid formations, sometimes free, at others existing within cells. This kind of atheroma is identical in structure and chemical composition with certain forms of the reticulum in cancer—(Fig. 16, 41.)

Fig. 179.




Fig. 179. Granular fatty matter, from an atheromatous degeneration of a lumbar gland.

The granular fatty matter is often combined with crystals of cholesterine, more or less numerous—(*Cholesteotoma* of Müller). I have found the contents of some cystic tumours almost wholly composed of the laminar plates so formed. At other times they accompany various kinds of chronic exudation, and formation of epithelium, as formerly noticed.

Fig. 180.

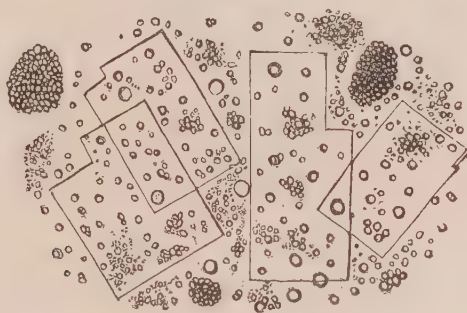


Fig. 180. Fatty granules, with crystals of cholesterine, from atheromatous deposits in the aorta.

### 6. Cancroid Tubercular Growths.

We have seen that in one case a mass of tubercle was considered by all who saw it to be cancerous—(Obs. XXXII). I also possess in my collection a mass of enlarged tubercular lumbar glands, which, to the naked eye, presents all the external characters of cancerous growths. I have no doubt that many cases of so-called cancer of the brain and other structures in youth, are, in point of fact, tubercular; for however easily this morbid structure may be distinguished in its miliary or infiltrated forms, it may closely resemble cancer when it exists only in one or two large rounded masses in an organ, and is more or less softened. In such cases it can only be distinguished by a microscopic examination.

It is not my intention to enter at any length into a description of tubercle in connexion with my present subject.<sup>1</sup> All that is neces-

<sup>1</sup> See the author's papers "On the Spontaneous Cure of Pulmonary Consumption."—Ed. Med. and Surg. Journal, Vol. lxiii. p. 406. And "On the Minute Structure and Chemical Composition of Tubercle."—Northern Journal of Medicine, Vol. iv. p. 211.

sary is to point out such of its characters as will readily distinguish it from cancer.

A tubercular mass generally presents a yellowish or dirty white colour, and varies in consistence from a substance resembling tough cheese to that of cream. Sometimes it is soft in one place, and indurated at another. On section, when tough it presents a smooth or waxy, and when soft, a slightly granular surface. On pressure it is friable, and may break down into a pulpy matter, but never yields a milky juice.

Fig. 181.

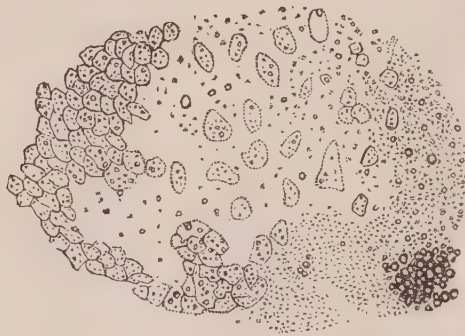


Fig. 181. *Tubercle corpuscles, &c., from a soft tubercular mass in the lungs.*

A small portion squeezed between glasses, and examined under the microscope, presents a number of irregular shaped bodies approaching a round, oval, or triangular form, varying in their longest diameters from the 1-120th to 1-75th of a millimetre—(Fig. 181). These bodies contain from one to seven granules, are unaffected by water, but rendered very transparent by acetic acid. They are what have been called tubercle corpuscles. They are always mingled with a multitude of molecules and granules, which are more numerous as the tubercle is more soft. Occasionally, when softened tubercle resembles pus, constituting scrofulous purulent matter, we find the corpuscles more rounded, and approaching the character of pus cells. They do not, however, on the addition of acetic acid, exhibit the peculiar granular nuclei of these bodies. The following figures

Fig. 182.

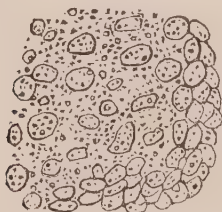

Fig. 183.



Fig. 184.

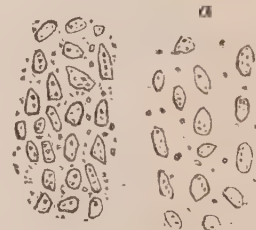
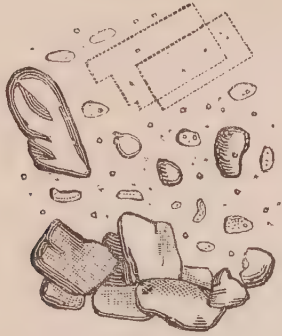


Fig. 182. *Tubercle corpuscles from a mesenteric gland.* Fig. 183. *Scrofulous pus from a lymphatic gland.* Fig. 184. *Tubercle corpuscles from the peritoneum. a. The same after the addition of acetic acid.*

represent different forms of tubercle corpuscles, and show how easily they are distinguished under the microscope from cancer cells. Compound granular masses and cells, mineral matter, crystals of cholesterine, and the debris of the texture in which the morbid product is found, are also frequently found in tubercular masses of some

Fig. 185.



*Fig. 185. Fragments of phosphate of lime, crystals of cholesterine, and tubercle corpuscles, from a cretaceous mass in the lungs.*

standing—(Fig. 185). It is now well established that they may be transformed into cretaceous and calcareous substances, and remain latent in the economy.

In addition to the various kinds of growths which have been described, several others are occasionally met with, which, under particular circumstances, may be mistaken for cancer. Thus, M. Velpeau<sup>1</sup> has pointed out a peculiar kind of tumour, which he denominates fibrinous. It is caused by an extravasation of blood, which coagulates, becomes more or less discoloured, and ultimately yellow, like a clot of blood confined in the sac of an aneurism. He says that these tumours vary in size, may occur in various tissues, and are very common in the female breast, especially of young persons, where they are often mistaken for cancerous tumours. I have frequently seen this kind of tumour in different textures, but especially in the placenta and in the spleen. In the latter position, the structure of one was found to consist of numerous molecules and granules, fusi-form corpuscles, compound granular masses, and irregularly formed bodies, probably altered blood corpuscles, such as are commonly found in all old extravasations.

<sup>1</sup> De la Contusion dans tous les Organes. Thèse de Concours, 1832.

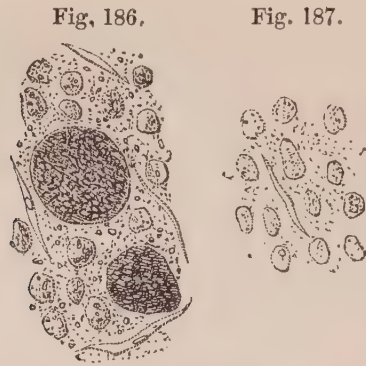


Fig. 186. Structure of a fibrinous mass found in the spleen. Fig. 187. The same after the addition of acetic acid.

Although I have thought it proper, in this place, to notice the occurrence of these tumours as cancroid, in deference to the opinion of M. Velpeau, a case has never come under my notice where one of them has been mistaken for cancer, and this although numerous excised breasts have been sent to me for examination. Instances of the kind, however, are recorded by Lebert<sup>1</sup> and Berard,<sup>2</sup> and the extreme probability of the occurrence cannot be denied.

Henle<sup>3</sup> has described a peculiar form of tumour under the name of *syphonoma*, the preparation of which, in the anatomical museum of Heidelberg, I myself carefully examined in the autumn of 1846. It consisted of a large mass attached to the mesentery, which was in one place hard, fibrous, and nodulated, in another soft and cheesy, or even purulent, and in a third, fibrous, but soft, and of a dark red, resembling coagulated blood. To the naked eye it seemed to consist of filaments running parallel to each other, as in muscular substance, which under the microscope were seen to consist of tubes of variable size. Henle considers that these tubes could be distinguished from vessels by the unfrequency of any branches and anastomoses, the simple structure of their walls, and the granular nature of their contents. Considering that the preparation had been steeped in spirit for some time before it was examined, much reliance cannot be placed upon the latter distinction. I must further confess (although in so doing I may incur the charge of presumption in venturing to differ from so distinguished an authority), that the ap-

<sup>1</sup> Lebert. Op. cit., Vol. ii.

<sup>2</sup> A. Bérard. Diagnostic Différentiel des Tumeurs du Sein, 1842.

<sup>3</sup> Zeitschrift für Rationelle Medicin. 3 Band, 1 Heft; and Monthly Journal of Medical Science, November 1846.

pearance of the demonstration I saw under the microscope, in the presence of Drs Bruch and H. Müller, closely resembled a vascular plexus, and that anastomoses here and there were distinctly visible. Further observations require to be made on this singular form of growth.

Another curious form of cancroïd growth is that recorded Obs. XXIII., which all who saw pronounced to be cancerous, yet which consisted of structures never previously found associated. For a description of it I need only refer to pp. 75, 76.

I have not separated encysted growths as a distinct form of cancroïd, because they are either epithelial, fatty, or colloid. A singular instance of colloid encysted tumour, presenting all the appearance of *fungus hæmatodes*, is recorded Obs. LIV.

Lastly, the enlarged glands which accompany typhoid ulcerations in the intestines, although by an observant pathologist they will rarely be confounded with cancer, still occasionally present a strong similitude to it. Such glands are often greatly distended, varying in size from a hazel-nut to that of a hen's egg. They are externally vascular, of a bright red or purple colour, are soft and pulpy to the feel, and on section present a slightly granular surface, of greyish or fawn yellow colour, frequently exhibiting commencing softening. They are friable, and yield a greyish, or dirty purulent-looking fluid on pressure. The matter infiltrated into the texture of the gland is the typhous deposit of Rokitanski, Engel, and other Viennese and Prague pathologists.

On examining the fluid squeezed from glands so affected, which my assistants and myself carefully did during the winter and spring of 1846-7,<sup>1</sup> it will be found crowded with cells, naked nucleoli, blood corpuscles, granules, and molecules. The cells are generally spherical, varying in diameter from the 1-50th to the 1-35th of a millimetre. In some cases the nucleus occupies three-fourths of the cell, and is composed of an aggregation of numerous nucleoli, of about the 1-200th

<sup>1</sup> See abstract of the author's paper "On the Morbid Anatomy and Pathology of the Typhus Fever prevalent in Edinburgh during the Session 1846-7."—*Monthly Journal of Medical Science*, October 1847.

of a millimetre in diameter (Fig. 188). At other times from one to four of these nucleoli may be seen scattered within the cell, either with or without a round or oval transparent nucleolated nucleus (Fig. 189). On the addition of acetic acid the cell-wall is rendered

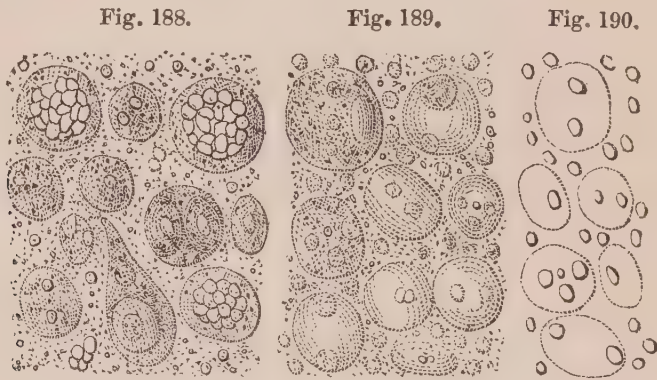


Fig. 188. Cells from a mesenteric gland loaded with typhoid deposit. Fig. 189. Cells from a gland similarly affected in another case. Fig. 190. The same after the addition of acetic acid.

very transparent, whilst the nucleoli are unaffected. Many of them are free, and at first looked like altered blood globules, from which they are at once separated by the action of acetic acid (Fig. 190). I have called these bodies nucleoli, from their holding that relation to the nucleus in well-developed cells, although at other times they may be considered as nuclei, no other bodies being present within the cells.



## CHAPTER IV.

## GENERAL PATHOLOGY OF CANCEROUS AND CANCROID GROWTHS.

THE pathology of cancerous and cancroid growths comprehends the present state of our knowledge regarding the origin, progress, and decline of these structures, and their relation to other morbid products. The subject is necessarily theoretical, and consists of deductions which can only be considered as approaching correctness so far as they harmonize with well-ascertained facts. There is every reason to hope that many important facts connected with the structure and chemical composition of cancerous and cancroid growths are yet to be discovered; and consequently the account now to be given can only be considered as a sketch, any part of which may be erased, filled up, or corrected according to the information obtained by future investigations.

## I.—GENERAL PATHOLOGY OF CANCEROUS GROWTHS.

It is of great importance to understand what may be called the natural progress of a cancerous growth, in order that, by our knowledge of the modes of its production, decline, and spontaneous disappearance, we may, if possible, be led to its prevention or cure by art. An acquaintance with the changes the constituent parts of cancer undergo, also, enables us to explain the different appearances which it presents at various times, and trace them to one origin. This study divides itself into an inquiry concerning the origin, growth, and degeneration of cancer, and includes a discussion of the important question as to its natural cure.

*Origin.*

The great majority of facts with which we are acquainted, lead to

the conclusion that the filaments, cells, and fluid, which together make up the tissue I have called cancerous, originate in a coagulated exudation. This is poured out exactly in the same manner as all other forms of exudation, namely, by enlargement of the capillaries, their repletion with blood, and the transudation through their coats of the transparent liquor sanguinis, which, coagulating outside the vessel, constitutes an exudation more or less solid. The exudation, when first perceptible (Fig. 68), consists of a finely molecular and granular matter, in which the cancer cell arises as in a blastema, in the manner already described.

It was supposed by Velpeau,<sup>1</sup> from an observation of two cases in which encephaloid-looking matter was found in venous coagula, without disease of the veins themselves, that cancer might form primitively in the blood. There is no proof that the matter was really cancerous in these cases; indeed, it is said they might probably be pus. If so, the lesion may be similar to that described by Dr Craigie and myself,<sup>2</sup> and of which Virchow has also given examples under the name of white blood. This last observer, however (whose authority on this subject is unquestionable), says, that he has seen cancer in the large venous trunks in six cases, and is convinced that it may thus arise locally in coagula of blood.<sup>3</sup> It is much to be regretted that these cases have not been minutely detailed. Gluge<sup>4</sup> also refers to an instance of encephaloma of the stomach, mesenteric glands, and liver, in which, with M. Nonat, he discovered cancer cells in the clot of the right iliac vein, similar to those which existed in other diseased parts. The walls of the vein were smooth, and not red.

These cases are very rare, and are insufficient to prove that cancer may exist in the blood primarily; that is, independent of any direct connexion with, or juxtaposition to, other similar growths in the economy. But should further observations confirm this opinion, we must conclude that the liquor sanguinis of the blood, may, under peculiar circumstances, act as a blastema within the vessels, as well as when exuded.

The exudation, when originally poured out, is generally infil-

<sup>1</sup> *Révue Médicale*, T. I. p. 357. 1825.

<sup>2</sup> *Edinb. Med. and Surg. Journal*, Vol. lxiv. p. 413.

<sup>3</sup> *Archiv. für Pathologische Anatomie und Physiologie*, Band. I. p. 112.

<sup>4</sup> *Atlas*, Lief. I. p. 8.

trated between the filaments of areolar tissue. Pre-existing textures undoubtedly have a considerable influence on the formation of new growths, and the areolar tissue seems to exert great power in all forms of cancerous exudation. Whether it be owing to this influence or not, while part of the exudation passes into cells, another portion passes into fibres, exactly in the same manner as takes place in a simple exudation during the healing of an ulcer or wound. I have already described the different modes in which these transformations occur, although we are as yet entirely ignorant of the circumstances which produce one or the other kind of development. All we know is, that filaments and fibres are formed, which are interlaced among the granules and cells of the blastema, to constitute the stroma of the growth, the form and density of which is dependent on its arrangement and amount.

At first the cancerous exudation is fluid, and some of the albuminous principle held in solution, by coagulating, allows a certain quantity of serum or uncoagulable fluid to be set at liberty. In most instances this is in a great measure absorbed, but in a few, owing perhaps to some peculiarity in its formation or amount, it is retained in the meshes of either the pre-existing or new areolar tissue. Such I presume to be the origin of colloid cancer. The colloid matter so collected, becomes in turn a blastema for the production of cancer cells, and there are gradually precipitated in it granules, which form nuclei, and afterwards cells, in the manner that has been previously described.

The exudation thus poured out, which I have called cancerous exudation, must differ from the exuded matter in what is called inflammation or tubercle; but in what that difference consists we are ignorant. The characters given to the blood by Rokitanski and Engel, to distinguish what they have called the cancerous dyscrasia, are so vague and uncertain as to have no real value. Neither is there any proof that such dyscrasia consists in an excess of albumen (Engel), or of fibrin (Heller) in the blood. The latter takes place after all exudations. But although the present state of pathology does not warrant our stating positively wherein exudations differ, we cannot avoid seeing that their occurrence in various individuals produces very different results. Thus, if an exudation be poured out in a healthy individual, it produces a series of phenomena which we call inflammatory; if in a scrofulous individual, another series of

changes called scrofulous or tubercular ; whilst in a third person the result may be a cancerous growth. Every kind of reasoning must lead us to the conclusion, that these different changes and effects depend, not upon the vascular system, which is the mere apparatus for the production of exudation ; not upon the nervous system, which leads to the necessary arrangement of that apparatus for the purpose ; and not on the texture, which is the seat of the exudation, as that varies, whilst the cancerous formation is the same—but in the inherent composition or constitution of the exudation itself. On this point most pathologists are agreed, and hence the supposed existence of various kinds of dyscrasiæ, originating in the blood, which it is imagined explain the different results produced. But here pathologists pause—once traced back to the blood they are content ; and they have not sufficiently taken into consideration, that the blood itself is dependent for its constitution on the results of the primary digestion in the alimentary canal on the one hand, and the secondary digestion in the tissues on the other. Yet it must be evident to every physiologist, that if it be the constitution of the blood which determines the constitution of the exudation, the causes which produce this must be sought in those circumstances which operate on the composition of the former fluid. These can only be the two digestions (primary and secondary), and the function of respiration.

The constitutional changes which precede or lead to the formation of cancer have not received great attention. The disease is often so obscure and insidious, that great difficulty attends the inquiry ; and yet this I believe to be a point which, once fairly investigated, would tend to the most beneficial practical results. Here, perhaps, a comparison between the characteristics of the cancerous and what may be called the simple or inflammatory, and the tubercular exudations, may lead us to some useful hints in connexion with that subject.

We observe in a simple or inflammatory exudation, that it may occur at all epochs in life ; that it may attack all tissues, and most commonly those which are very vascular ; that it may be poured out in large or small quantities ; and that it may occur with greater or less rapidity—hence the terms acute and chronic. We further observe, that the acute exudations are generally attended with symptoms of a peculiar character (inflammatory), and have a great tendency to cell or temporary formations, which rapidly break down, are absorbed and excreted by the emunctories : that the chronic exuda-

tions, on the other hand, have a tendency to fibrous or permanent formations, producing adhesions, strictures, hypertrophies, &c.

We observe, in a tubercular exudation, that it occurs for the most part in young subjects, between the periods of dentition and adult age; that it may also occur in all tissues, but is by far most common *primarily* in the lymphatic glands, and afterwards in fibrous or albuminous textures, as the lungs and serous surfaces; that its progress is generally exceedingly slow; that there is no tendency to perfect cell formation, but rather to abortive corpuscles, which form slowly, and slowly break down; that there is little tendency to absorption, but great liability to disintegration and ulceration; and finally, that the local changes are almost always preceded by derangement of the *primæ viæ*, and a group of symptoms known under the name of dyspepsia.

We observe, in a cancerous exudation, that it occurs for the most part in persons of adult or advanced life; that it may also occur in all tissues, but is by far most common in glandular or fatty organs, such as the liver or female mamma, and is very apt to attack the lymphatic glands *secondarily*; that its progress, although sometimes slow when very fibrous, becomes rapid when corpuscles abound in it; that there is a great tendency to the most perfect forms of cell life, which have the power of self-development, and thereby spreading to neighbouring tissues; and lastly, that when, by pressure, ulceration is produced on free surfaces, it bursts through these in exuberant fungoid excrescences.

Taking, then, the products of simple inflammation (say pus) as a standard, we cannot fail to remark, that whilst the cell development of tubercle is below, that of cancer is above, this standard. Of the three kinds of exudation, tubercle is the lowest, and cancer the highest, in the scale. One is deficient in power of development, the other possesses this power in excess. On what this difference in the exudation depends, as previously stated, we are ignorant; but, taking the circumstances of age and other peculiarities into consideration, it seems to me probable that tubercle is connected with some derangement in the function of the primary, and cancer with some derangement in the function of the secondary, digestion. Certainly it is most common at that epoch of life when the excretory functions commence to lose their activity; and the exceptional cases, where cancer occurs at a younger age, will often, on inquiry, be found to

accompany circumstances which impair the exercise and bodily vigour, so necessary for the full completion of the nutritive process.

Whether paying any attention to these facts may ultimately throw any light upon the origin of cancer, or be useful in preventing its occurrence, further researches only can determine. I may observe, in addition, as pointing out the wide difference between a tubercular and a cancerous exudation, that whilst either of them may be found accompanied, or alternate with, a simple exudation, they are never met with together. Instances are common, where individuals may have tubercle in youth, and cancer in adult age (Obs. XIV., XIX., XXIV., XXVIII., XXX.); but I have not seen or heard of a well authenticated case, where recent tubercle and recent cancer were associated. Lebert, indeed, has recorded a few,<sup>1</sup> but he was evidently unacquainted with the nature of the reticulum, which was probably mistaken for tubercle.

#### *Growth.*

Cancer cells and nuclei, with fibrous tissue, being produced in the manner described, the former propagate themselves. The old cell-walls dissolve or break down, and the included cells or nuclei are liberated, and give rise to others in turn. For this purpose, however, there must be a sufficient amount of blastema present. This is obtained at first from the original exudation poured out; but after a time, as the fibrous tissue increases, new vessels are formed in it, which continue to furnish materials to the new growth, in the same manner as the old vessels furnish materials of growth to the old tissues.

Here, it may be asked,—since some altered quality exists in the blood, whereby the matters transuded pass into a growth foreign to the organism, why does it happen that healthy tissues continue to be nourished in different parts of the frame? Nay, if a wound or injury be inflicted in some other portion of the body, why should a simple exudation be poured out, pus formed, and the healing process accomplished, exactly in the same manner as in persons of the most perfect health?

Undoubtedly these are questions which prove the modern humoral doctrine of disease to be any thing but perfect. Indeed they forcibly point out, that, besides any alteration which may take place in the

<sup>1</sup> Lebert, *Op. Cit.*, Vol. I. p. 492.

blood, a certain influence is still maintained over the products of organization by the solids. Accordingly pathologists are obliged to acknowledge, that a tissue once formed, exercises considerable power over cell development in its immediate neighbourhood; and hence why, when a bone is fractured, the exuded matter poured out around it is transformed into bone, and that other tissues are restored when lost, if not by a texture identical, at least analogous to the one destroyed. Very compound tissues, such as skin, lung, muscle, &c., are never completely restored, but a cicatrix is formed, composed of fibrous tissue. On the other hand, epithelial and epidermic structures are easily restored and re-formed, and so are all tissues which wholly consist of cells. Hence the more a cancerous growth abounds in cells, the more rapidly it grows, and the greater is its power of re-development. Whether this power depends wholly on the existence of pre-existing and permanent nuclei (germinal centres), as some suppose, I shall not now inquire. It is sufficient for our present purpose to know, that a tissue once formed, and furnished with bloodvessels, possesses the property of growth; that is, of exerting a species of selective vital attraction on the blood, whereby such matters are transuded through the capillaries as are readily transformed into a substance like itself.

This I believe to be an explanation of the fact, that a cancerous tumour increases by growth, which tubercle cannot be said to do; the former is vascular, the latter is not: in the one, cells are formed which have the power of re-development, in the other, no re-productive cells are produced. In cancer the morbid matter circulating in the blood (whatever that is), is concentrated or attracted to the cancerous part, and should none afterwards be present, the healthy blood is made subservient to the purpose of nourishing a foreign growth. In tubercle, successive fresh exudations only are made, which, by their accumulation, augment the volume or amount of the morbid product.

It is very probable, whatever the original cancerous material in the blood may be, that it does not exist there permanently after having once manifested itself. Considering that the blood is continually undergoing changes, is receiving and giving off new matters, it can scarcely happen that it remains the same for many hours together. An exudation at one time may be very different from that at another. At one period it may abound in elements which do

not exist in it at the next. Hence it may often happen that a concurrence of circumstances is necessary to occasion a certain result. A cancer once formed may remain local until such a concurrence of events arises, comprising first, a peculiar constitution of the blood, secondly, the phenomena leading to and producing an exudation, and thirdly, the occurrence of this exudation in some other tissue or organ sufficiently predisposed for the purpose. Thus cancer may be primary or secondary; may be the first morbid product formed, or superimposed on some other; may be single or multiple; may occur at one time, or many; in one tissue, or several.

A cancerous growth once formed may increase slowly or rapidly. In general, the greater the amount of cells in the growth, the more rapidly it proceeds. We frequently observe hard and indolent tumours existing for years, then increasing quickly in size; that is, passing from a condition almost wholly fibrous, to one having an excess of the cell element. The extent to which such tumours may increase before ulcerating, is only limited by the expansive power of the tissues which cover them. But sooner or later the pressure from within causes these tissues to ulcerate, and then the cell element, restrained until that moment by the pressure to which it was previously subjected, rapidly throws out crowds of cells, forming fungoid masses on the free surface. These externally at length break down to form an ichorous fluid, or they may slough off, leaving depressions and cavities on the surface; and the ulceration of the integuments extending, constitutes a sore with callous edges, yielding an offensive discharge, in which broken down cancer cells, mingled with imperfect pus corpuscles, the debris of the tissues involved, crystals of cholesterine and triple phosphate, and a multitude of molecules and granules, may be detected with a microscope. The disease may also extend internally. The cells may push their way into, and infiltrate themselves among, the neighbouring tissues, which then also become cancerous, and thus the disease extends from one texture to another. Occasionally the same action is set up in more than one place at a time; and then, of course, the extension is more rapid and universal, the destruction of healthy tissue, and the formation of the cancerous growths, being proportionably greater.

Whenever an exudation is poured out in a part, the neighbouring lymphatic glands, through which much of the effete matter must



pass, are very liable to be irritated, enlarged, and to be ultimately diseased. This is especially the case with cancerous exudation; so that in protracted cases, chains of lymphatic glands are affected, and often form separately or united large tumours, which in their turn serve to convey the disease to other textures. In this manner the amount of cancerous growth in an individual may reach an enormous height, and exist in numerous tissues and organs before it proves fatal.

When the growth of cancer has proceeded to any extent, we observe that the patient becomes emaciated, and assumes a so-called cachectic aspect, which has been supposed characteristic of the disease. Such change of appearance is in no way peculiar to cancer, but may be observed in various disorders which produce interference with the functions of important organs, interrupt the progress of nutrition, or cause much suffering and want of sleep. It is worthy of observation, that in all kinds of exudation, there exists, after a certain period, an increase of fibrin in the blood. Andral has shown this to be the case not only in inflammations and in phthisis, but in cancer during the stage of softening,<sup>1</sup> or, according to his views, when inflammation occurs in the growth. The latter observation has been confirmed by Heller.<sup>2</sup> But the true explanation of the fact is, that during the retrograde progress of these forms of exudation, the effete matter is absorbed, and constitutes according to the opinion of Zimmerman, formely alluded to, the fibrin discovered by chemists in the blood. The long continuance of this in the circulating fluid, may be connected with the so-called cachectic aspect of tubercular and cancerous diseases.

The spread of cancer by inoculation or contagion is a question which has been debated. There is only one fact on record which favours the supposed possibility of communicating the disease by inoculation, and that is an experiment of Langenbeck, who injected into the bloodvessels of a dog fresh cancer cells from a tumour while still warm, which had been removed two hours and a half previously from the humerus of a man, and it is said with the effects of inducing secondary cancerous tumours in the lungs of the animal.<sup>3</sup> The

<sup>1</sup> Andral. *Hématologie Pathologique*, p. 165, 1843.

<sup>2</sup> *Archiv. für Physiolog. und Patholog. Chemie und Mikroskopie*, Heft. 1, 1486.

<sup>3</sup> I have been unable to gain access to the 25th volume of Schmidt's *Jahr-*

experiment was carefully repeated by Vogel,<sup>1</sup> who says he was convinced that at least thousands, very probably millions, of cancer cells were thrown into the circulation, and yet the dog exhibited no morbid symptoms, and when killed, eight months afterwards, not the slightest morbid change could be detected in any organ. Gluge has also been unsuccessful in his attempt to inoculate. The evidence with respect to the influence of contact is also contradictory. Dr Watson<sup>2</sup> says, that he has known two cases of cancer of the penis in men, whose wives laboured under cancer of the uterus. Was it proved to be cancer by a microscopic examination? Dr Walshe, on the other hand, says,<sup>3</sup> "I have known women afflicted with advanced cancer of the uterus, take refuge in hospitals from the importunities of their husbands—these men were perfectly free, according to the assurance of their wives, from ulceration of any kind." I may add, that more than once my hands, with several recent scratches upon them, have, during the removal of large cancerous tumours from the abdomen, been covered for a considerable time with the creamy fluid of encephaloma, without the slightest irritation being caused in them. That cancer can be communicated by contact or inoculation is certainly opposed to experience, and the experiment of Langenbeck is not sufficient to establish its possibility.

#### *Degeneration.*

It is with the life of a cell as with that of the most highly organized individual; it has its origin and birth, it gradually increases until it reaches maturity, then declines or degenerates until it has ceased to exist. The individual elements of a cancerous growth, like those in the healthy tissues of the body, are continually undergoing this process; like them, it leaves germs which continue to regulate its growth so long as they receive nourishment, and thus the structure, as a whole, is perpetuated. Sometimes this process receives a check, from the cells, which are the entire agents of growth, being rendered abortive, and the result may be, 1. a fibrous cicatrix, 2. a fatty mass, or 3. a calcareous concretion.

bücher, in which this experiment is recorded, and am therefore ignorant whether the matter injected and the tumour in the lungs were examined with a microscope, and the structure of both carefully ascertained.

<sup>1</sup> Vogel, Op. Cit., p. 310.

<sup>2</sup> Watson, Op. Cit., p. 211.

<sup>3</sup> Walshe, Op. Cit., p. 144-5.

1. I have already described, when speaking of the cancer cell, the mode in which the external cell-wall dissolves and breaks down, liberating the included young cells. This is the natural completion of individual cell life. I have also endeavoured to point out, under the head of growth, how the increase of cells is dependent on a proper supply of blastema, which is necessary to furnish the materials of assimilation. Several cases are known where a cancerous has undergone the same changes as a simple ulcer; the cancer cells in the one, and the pus cells in the other, becoming gradually less in number, whilst the fibrous element has increased in amount, and terminated in the production of a cicatrix. Dr Walshe has collected several instances of this.<sup>1</sup> However seldom this may be known to have happened, the fact cannot be doubted, and the probability is, that it is of more frequent occurrence than is generally supposed. We are continually meeting in old persons with cicatrices and puckerings in the breast, liver, and various organs, evidently the remains of former exudations, which have in this manner dried up, disappeared, and left cicatrices. True, we have no positive evidence that such exudations were cancerous, any more than they were tubercular or simply inflammatory. But facts are not wanting to give probability to the idea that they are not unfrequently the result of the first.

Professor Bochdalek of Prague published a memoir in 1845, "On the Healing Process of Cancer in the Liver." He describes the cancer in this organ as breaking down into a cream-like matter, the fluid parts being absorbed, and the whole shrinking together, forming a puckering on the surface, often corresponding to a fibrous mass, or a fatty material, in which collapsed cancer cells may yet be detected. In some livers he has seen these cicatrices in all stages of formation,—cancer in some places, and perfect cicatrices in others. In Prague, he tells us, there are between 400 and 500 bodies examined annually. Among these cancer of the liver occurs about sixteen or seventeen times, and among these proofs of healing may be observed in between six and seven. When in Prague, during the autumn of 1846, I carefully examined the preparations of the lesion described by Dr Bochdalek, in the pathological museum of that city. I recognised them to be the same in appearance as those described

<sup>1</sup> Walshe, Op. Cit., p. 77, 136.

Obs. XIX. Professor Dlauy, the present pathologist, was so polite as to take the preparations out of the bottles, make fresh incisions into them, and permit me to examine them microscopically. I found that the cicatrices, though altered by spirit, were principally composed of fibrous tissue; the nature of the softer matters could not be ascertained. I was then shown a similar preparation of a liver, together with a stomach taken from the same case, the former having similar puckeringings, and the latter a cancerous ulcer, of which the individual died. It seemed to be a case almost identical with that recorded Obs. XIX.

It is very probable, therefore, that cancer may undergo transformations, sometimes, as we shall immediately see, fatty, and at other times calcareous; that its power of growth and re-development may be checked, and as a consequence it shrivels up, some of the softer parts are absorbed, and the remainder continues inert in the system, while the contraction of the surrounding parts, and the filamentous stroma of the cancer together, constitute the puckeringings and cicatrices occasionally found as evidences of a spontaneous cure.

2. When speaking of the compound granular cell, I pointed out how the cancer cell was frequently rendered abortive by the deposition of fat granules between the nucleus and cell-wall, their pressure upon the former, and the ultimate disintegration of the whole body into numerous fatty molecules and granules. This is a very common termination of the life of individual cancer cells; and, when the process is carried on to any great extent, the fat granules often collect in masses, and mingled with old cells, which exhibit various stages of their retrograde progress, and old nuclei, which have more or less resisted disintegration, are at length observable to the naked eye. In this manner the yellow masses, and yellow reticulated appearance in certain cancerous growths of some standing, are produced,—an occurrence so common that Müller described it as a particular form of the disease, under the name of *cancer reticulare*.

My observations fully agree with the opinions of H. Meckel,<sup>1</sup> and of Virchow,<sup>2</sup> who describe the reticulum of Müller as disintegrated cancer. It is composed of broken down cancer cells, the nuclei sometimes remaining, (Figs. 27, 30, 46)—at others the whole has

<sup>1</sup> Müller's Archiv. 1846.

<sup>2</sup> Op. Cit.

undergone the fatty transformation, and been converted into compound granular cells (Figs. 11, 38)—and not unfrequently, in the last stage of the process, nothing but molecules and granules can be discovered—(Figs. 16, 41, 48). This change is not a proof of so-called secondary inflammation of the growth, as is supposed by Rokitanski, Lebert, and Walshe; it is the same transformation that may be observed in all old exudations, and in various organs where pre-existing cells undergo the fatty transformation, as in the liver, to constitute fatty liver, the kidney, to form Bright's disease, &c. &c.

The reticulum, or rather the matter forming the reticulum, may occur in two forms. In one it is seen on a fresh cut surface scattered throughout the growth to a greater or less extent, in the form of a network, more thick and abundant, however, in some places than in others. In the second form it exists in masses, of a bright yellow or orange colour, sometimes closely resembling tubercle, more or less friable, and of cheesy consistence. In the first form, compound granular corpuscles are most common, (Fig. 11)—in the last, irregular bodies, resembling tubercle corpuscles, resulting from alteration in the form of the nucleus, after the cell-wall has been broken down—(Fig. 25). These are called bodies of the reticulum by Bruch. The occurrence of compound granular cells is very common in cancer, and this may frequently be considered as evidences of degeneration of the cancer cell. The greater their numbers and agglomeration together, the greater the extent of the degeneration.

It is rare that we find that this form of degeneration takes place uniformly throughout a cancerous growth; much more commonly, while one part is being converted into a fatty reticulum, another portion is being actively developed. This is why cancer has such a tendency to spread to other tissues, and why the destruction of one part rarely exerts any influence on the growth as a whole. Sometimes, however, the degeneration invades the whole structure, when it may be associated with the form of degeneration into fibres, as previously noticed, or conjoined with the first period of that into calcareous matter, now to be described.

3. Another mode in which a cancerous growth sometimes degenerates, is by the accumulation of earthy salts, originally contained in the exudation. When this occurs, the same thing takes place that so frequently happens in abortive tubercle; the cells break

down, the soft parts are ultimately absorbed, while the mineral portions become aggregated together, and constitute a solid calcareous concretion. It has been considered doubtful whether this transformation of cancer ever occurs in the human body; but I must confirm the observations of those who have witnessed it.<sup>1</sup> In Obs. XVIII. mineral granules were scattered through a reticulum in the mesenteric glands, (Fig. 46)—which on section grated under the knife. In Obs. XIX. larger mineral masses were mingled with broken down cancer cells in the mesenteric and epigastric glands, (Fig. 49)—some of which felt hard from calcareous depositions, others were infiltrated with a putty-like substance, and a few were composed of an external shell of hard calcareous matter; whilst their interior consisted of a semi-fluid, gritty, diffuent material, which flowed out on breaking them. One of these calcareous concretions is still preserved in my collection. In Obs. XXXI. a large cancerous tumour was so loaded with mineral matter, (Fig. 78)—that on drying a slice of it, it was converted into a calcareous mass, of little less bulk than when moist. Specimens of this tumour are also preserved in my museum. These facts, with similar ones I have met with during post-mortem examinations, but the histories of which are unknown, have convinced me that the transformation of cancerous growths into calcareous concretions, though by no means so frequent as the same result in tubercular masses, is on the whole not uncommon.

<sup>1</sup> The following passages on this subject may be found in the work of Dr Walshe. Speaking of alteration of structure, 1st, into ossiform matter, and, 2dly, into encysted masses, he says, "Whether these changes may be really witnessed or not in the lower animals, the latter mode of conversion has not ever been alleged to occur in man; and I have already (p. 84) assigned apparently valid reasons for doubting that the human subject is ever the subject of the former."—(P. 135). On turning to p. 84, the only reasoning I find is the following:—"But I feel myself justified in affirming, after careful investigation of the point, that if the bony lamellæ, actually continuous with some part of the skeleton, and which form a marked characteristic of certain cancers connected with osseous structure, be excluded from consideration, the phenomenon in question will be found to have been much more written of than observed." If Dr Walshe here alludes to a conversion of cancer into true bone, he is undoubtedly correct. It must be remembered, however, that the term "osseous," so frequently used by pathologists, has, in point of fact, been most frequently applied to a calcareous concretion, resembling bone to the naked sight. Such I believe to be the sense in which it was used by Trousseau, Hodgkin, and Cruveilhier.

The three kinds of degeneration of cancerous growth I have now described may be more or less associated together, and we may have fibro-fatty and mineral matter conjoined or separate in retrograde cancer. In either case, the loss of substance generally occasions a sinking in or puckering of the surrounding tissues. These puckeringings are often produced in cancerous growths of some standing, without external ulceration, or the formation of a cicatrix, and produce the well-known symptom in the mamma of retraction of the nipple. They may often be perceived on the surface of the tumour itself, without affecting the integuments which cover it. Virchow is of opinion that the central depression in the white encephaloid masses of the liver is owing to this cause. Certainly stellate puckeringings on the surface of cancerous growths are far from uncommon, and exhibit proofs of loss of substance, with contraction of surrounding textures, a result which must have followed partial degeneration, and may fairly be considered as evidences of a tendency to spontaneous cure.

I have thus endeavoured to show, that a cancerous growth does not necessarily proceed to a fatal termination, but that, like all other forms of exudation, after passing through its natural stage of growth, it may occasionally be transformed into a substance which will remain latent in the economy. This substance may be fibrous, fatty, or mineral; and may sometimes be composed of the whole, and at other times of any two of these, combined in various proportions. It must be confessed, however, that hitherto these transformations have been seen to occur in comparatively few instances; and it would consequently be in the highest degree imprudent to expect such a result in any individual case. In the present state of our knowledge, also, the clearest proofs will necessarily be demanded, in order that the spontaneous curability of cancer may be fairly established. Such proof must always be difficult; for how is it possible to ascertain, when all the phenomena of cancer have disappeared, that they ever existed? Patient observation, however, will do much. The facts recorded in the first part of the work (Obs. XVIII., XIX., XXXI.)—I think afford unequivocal proof that a cancerous growth may undergo spontaneous cure; and I feel persuaded that, when evidences of this result are more diligently sought after than they have hitherto been, it will be found to have occurred much more frequently than is generally supposed.

## II.—GENERAL PATHOLOGY OF CANCROID GROWTHS.

It is not my intention to enter into the pathology of cancroid as I have done into that of cancerous growths, because for the most part a description of their origin, course, and degeneration, would be a mere physiological account of all that is known with regard to the different textures of which they consist. Of fibro-nucleated growths I have sufficiently spoken, under the head of General Anatomy. With respect to epithelial, fibrous, cartilaginous, and fatty growths, they originate, grow, and decline, exactly in the same manner as similar structures in the healthy body. Why this or that particular growth should occur in preference to another, we are ignorant. It may frequently be observed that they, like all kinds of hypertrophies, originate in an increased exudation into a part, following a blow or injury; but at other times no apparent cause can be assigned. On the subject of whether the ultimate form of growth be connected with a particular predisposition of the frame, or with some local influence exerted by the neighbouring textures, we also know nothing. The pathology of tubercular cancroid growths, so far as its discussion is necessary to our subject, is spoken of, p. 196.

There is one question, however, in reference to these growths that requires notice in this place, namely, once formed can they be afterwards transformed into cancer? On this point great differences of opinion prevail; but an interrogation of facts must, I think, demonstrate that, whilst this is very probable in some growths, it never takes place in others. For example, no instance is known where cancer has supervened on an enchondromatous or on a tubercular tumour: on all other growths which are furnished with blood-vessels, such as fibro-nuclear, epithelial, and fatty growths, it is possible, although this would be difficult to establish. But with respect to fibrous growths, the result of a simple exudation, or hypertrophy, at first of purely local origin, its occurrence seems to me to be absolutely proved. According to Lebert, inflammation (simple exudation), tubercle, and cancer, are separated by distinct characters, originate from separate blastemata from the first, and never pass into each other. In this opinion I think he proceeds too far; for why may not a cancerous exudation be formed into the filaments of a vascular, fibrous, or fatty tumour, as well as among the filaments of



the normal areolar tissue of the body? We are continually meeting with cases where a blow or injury in a part producing a swelling, with the ordinary symptoms of inflammation, is, after a time, followed by cancer. An indolent tumour may exist for years, and then suddenly assume the characters of cancer. Are we to suppose that such a tumour was composed of fibres and cancer cells from the first, and that the growth of the latter had remained stationary all that time, or that nothing but a fibrous tumour existed at first, in which cancer cells were afterwards formed? The latter appears to me the most reasonable proposition.

## CHAPTER V.

## STATISTICS OF CANCEROUS AND CANCROID GROWTHS.

ACCURATE and trustworthy statistics can only be derived from well-authenticated and positive facts. If this proposition be true, it necessarily follows that those which have been drawn up with so much pains regarding cancer must be fallacious in the extreme, as hitherto cancerous and cancroid growths have been confounded together by practitioners. Knowing what pains and investigations are often necessary to separate epithelial, cartilaginous, and fibrous tumours from cancer, it appears in the highest degree frivolous to draw up tables, like Tanchou, from 9118 cases recorded as cancer in mortuary registers, or to suppose that any disease whatever *really* exists, because it is the *opinion* of medical practitioners that it does so. The more our knowledge of pathology advances, the more it becomes evident that those who undertake statistical inquiries should be enabled to prove that the lesion of which they speak is truly present, and not suppose that an alteration which resembles it to the naked eye, or that harmonizes with preconceived views, will satisfy the demands of medical science as it now exists. Hence the statistics of Hill and others which favour operations, and of Leroy d'Etiolles and others, hostile to them, are alike unworthy of confidence.<sup>1</sup>

As exact observations, however, accumulate, I anticipate that the most important results will be obtained by applying the principle of statistics to cancer. Indeed, it is only in this way that we shall ever arrive at positive facts as to the permanent success of operations and the frequency of cure, whether spontaneous or artificial.

<sup>1</sup> See some observations by the author on fallacious statistics. Monthly Journal of Medical Science. 1847.

At present, it appears to me, that, notwithstanding the multitude of cases of so-called cancer on record, we are not possessed of exact observations in sufficient number to serve as the basis for such an inquiry. Lebert has done more towards advancing the statistics of cancerous and cancroïd growths than any other pathologist; but, notwithstanding the observations he has brought forward, the accuracy of the above opinion will appear from the following statement. Thus, there have been recorded by,—

Lebert <sup>1</sup>	. . . . .	392 cases
The Author	. . . . .	56 „
Sédillot <sup>2</sup>	. . . . .	30 „
Bruch <sup>3</sup>	. . . . .	28 „
Cases by Gluge, <sup>4</sup> Vogel, <sup>5</sup> Inosemtzeff, <sup>6</sup> Zimmerman, <sup>7</sup> Ormerod, <sup>8</sup> and some others, say	. . . . .	20 „
		—
		526 <sup>9</sup> „

Of these 526 cases, in which the morbid growth was carefully examined, about two-thirds are cancroïd, including all kinds of tumours not cancerous. If we divide the cancerous cases into scirrhus, encephaloma, and colloid, subdivide these into the numerous organs

<sup>1</sup> Lebert. *Op. Cit.*, vol. ii.; and *Abhandlungen aus dem Gebiete der praktischen Chirurgie*, 1848—a work which I received from the author while revising these pages.

<sup>2</sup> Sédillot. *Op. Cit.*

<sup>3</sup> Bruch. *Op. Cit.* Twenty-seven cases recorded in the first part, and one in the body of the work.

<sup>4</sup> Gluge. *Op. Cit.*

<sup>5</sup> Vogel. *Icones Histologiæ Pathologicæ*. 1843.

<sup>6</sup> Inosemtzeff. *Von Walther und Ammons Journal*. Band 5. Heft. 1. 1846.

<sup>7</sup> Zimmerman. *Schmidt's Jahrbucher*, p. 307. 1848.

<sup>8</sup> Ormerod. *Lancet*, 1847.

<sup>9</sup> I have cited these cases as all that I am acquainted with, which, being recorded with microscopical examinations, are at present available for statistical purposes. I am aware that an immense mass of facts might be accumulated from individual researches made within the last few years, which is not yet published.—I have myself notes of about 200 specimens of cancer, which I have examined, the histories of which might possibly be arrived at; but, as they are only repetitions of observations recorded in Part I., I have thought it would be attended with no good purpose to detail them at length. At some future period, when authentic observations have accumulated, they may be rendered serviceable to a trustworthy statistical inquiry.

and tissues in which the disease is found, and then reflect on the different ages, sex, constitution, and other circumstances to be particularised, it must be evident that our data are by no means sufficient to render an analysis of them even desirable. With regard to the cancroid growths, as they are more various and fundamentally different from each other, the number of each in a particular tissue or organ is much less.

For the same reasons that no statistics can be drawn up with useful results, so no account of the special anatomy and pathology of cancerous and cancroid growths can be given. The differences of cancer in different localities are very peculiar and striking, producing, of course, various symptoms and effects. Our present accounts, it must be confessed, are full of inconsistencies and contradictions; and a history of the disease in each organ of the body, founded upon a clear knowledge of its structure, course, and termination, is greatly to be desired. It must be evident, however, from what has preceded, that we must wait for materials, and that the whole is a labour yet to be accomplished in the different relations of symptoms, morbid anatomy, pathology, diagnosis, &c. Rokitanski and Gunsburg have done something, and Lebert more, towards this end; but, conceiving that any present attempt to arrive at it would be premature, I dismiss the subject with the remark, that it can scarcely be accomplished by one individual, however extensive his opportunities may be. During the last five years, mine, as pathologist to the Royal Infirmary, where I have examined annually between three and four hundred bodies, have not been inconsiderable, and yet I have still to meet with a case of cancer in the brain, eye, jaws, kidney, and indeed several other localities.

## CHAPTER VI.

## DIAGNOSIS OF CANCEROUS AND CANCROID GROWTHS.

THE chief point to be attended to with a view to the further improvement of our knowledge of cancer, is the correct distinction between growths truly cancerous and those which, however they may generally resemble them, possess a different structure. For this purpose the local symptoms and general signs observed in individual cases have been frequently found insufficient, such as the lancinating pains, unequal surface, hardness, elastic feel, softening, ulceration, the surrounding tissue being affected, a general alteration of the constitution, and return after excision. All these symptoms have, at various times, been absent in cases undoubtedly cancerous, have existed in growths the nature of which is doubtful, and often been connected with epidermic, fibrous, fatty, or cystic tumours of the most innocent nature. It is very possible, however, that the nature of morbid growths once accurately ascertained, and the symptoms produced by each carefully studied, that much more trustworthy powers of diagnosis will be arrived at by those who so prosecute the subject. In this manner experience and careful observation might, by a kind of retrospective information, communicate much more useful information than is at present the case, when all kinds of tumours are confounded together.

Symptoms alone, however, from their very nature, are apt to mislead, caused as they are by a variety of disorders which may affect an organ; whilst physical signs, once established and ascertained, are in conjunction with these of universal value. The only physical proof we can arrive at of the existence of cancer, is by means of the microscope; not that this instrument is in itself capable, even in the most expert hands, of doing any thing, but, conjoined with a knowledge of the symptoms, progress of the case, form and appear-

ance of the morbid growth, it offers us an additional and most valuable means of prosecuting our inquiries. It is from a union of all these circumstances, combined with a minute examination of the growth, under such magnifying powers as will clearly display its cells and other primary elements, that we ought to found a diagnosis, and not from one or the other separately.<sup>1</sup>

Hitherto the diagnostic value of a microscopic examination of cancerous and cancroid tumours has not been very extensively tried in practice. It was evidently necessary, before arriving at this, to investigate their structure, and obtain an amount of information that might serve as a basis, not only for further scientific research, but for useful purposes in the investigation of disease. The labours of those who have studied the subject may, I think, now claim some consideration from such of the profession as are desirous of founding their practice on an accurate diagnosis. To the surgeon and accoucheur especially, whose cases present them with morbid growths within their reach, such labours will prove valuable; and they are the persons who ought now to prosecute the inquiry, and render the results which have already, or may ultimately be arrived at, practically beneficial in the detection and treatment of disease. It should not be forgotten, that the whole subject is as yet in its infancy, although we can see clear indications of the great value which I feel satisfied it is destined one day to acquire. Hence all generalizations require at present to be received with the utmost caution; and all statements, in a field so comparatively unknown, ought to be advanced with the utmost diffidence. It is completely under the influence of these sentiments that I venture to lay before the profession a short account of the diagnostic differences existing between cancerous and cancroid growths.

### I. *Diagnostic Value of determining the Anatomical Structure of a*

<sup>1</sup> In the work of Müller, there are two sentences, almost close together, which seem to me directly opposed in their meaning to each other. He says, (West's Translation, p. 5)—“Microscopical and chemical analysis can never become a means of surgical diagnosis; it were ridiculous to desire it, or to suppose it practicable.” And again, (p. 6)—“Nevertheless, it is not possible to determine the fundamental points of difference between various morbid structures, except by means of chemical and microscopical examination.” If the latter statement be true, the former one must be false, inasmuch as surgical diagnosis ought to be founded on a knowledge of *all* the differences between tumours.

*Growth.*—In the living subject, the anatomical arrangement of the fibrous and cellular elements—the infiltration of the latter among the former, to which I have alluded as characteristic of a cancerous structure, can rarely be seen. We have few opportunities of obtaining a section; still there are certain places where the detection of such cells as have been ascribed as cancer cells, will enable us to diagnose a malignant growth with certainty. Over most of the surface generally, for instance, where the diagnosis especially concerns the surgeon, a group of such cells, once seen, cannot leave us in doubt, because the epidermic scales in such cases seldom resemble them; whereas, in internal organs, as the bladder, stomach, or brain, the similitude is more close. Hence, to the surgeon and accoucheur, a minute examination is a more precious means of diagnosis than to the physician; for various ulcerated and fungoid tumours of the surface or cervix uteri may be diagnosed with certainty, from an examination of the cells alone; whilst in fluids discharged from the stomach, bowels, or bladder, this means of diagnosis is not so certain. Again, whenever we see in a morbid growth cells including other cells, as those represented Figs. 69, 117, there can be no doubt of the cancerous nature of the tumour.

The group of cells represented in the following figures, to which I refer the reader anxious to improve his powers of diagnosis, are all very characteristic of cancer, namely, Figs. 3, 7, 11, 13, 17, 25, 28, 32, 33, 34, 36, 37, 42, 56, 65, 69, 70, 117, 118, 137. It is not by fixing attention on any one particular cell that we can discover a marked difference between it and a variety of others; but when grouped together we observe in different cells a variety in size and shape, some containing one nucleus, others two or three, and occasionally, though rarely, more, and the nucleus containing one or two nucleoli. Such a group of cells is easily recognised by an experienced eye, and readily distinguished, 1. from groups of epithelial cells—(Figs. 22, *a*, *b*, 23, 109, 113, 114, 145, 146, 151, 152, 153, 154); 2. from fibro-plastic cells—(Figs. 62, 100, 102, 155, 159, 160); 3. from pus and plastic cells—(Figs. 164, 165, 166); 4. from compound granular cells—(Figs. 162, 163); and 5. from fat cells (Fig. 177). Their separation from cartilage cells before softening is also easy—(Figs. 106, 126, 129); but after softening it is more difficult—(Figs. 104, 128, 130). In the latter case the action of water and acetic acid on the cells, and a careful examination by means of

numerous sections, until the structure of cartilage is made apparent, will be necessary.

Groups of cancer cells, when young (Fig. 39, 51), are easily confounded with groups of epithelial cells which have been long steeped in fluid, as is occasionally found in the bladder, lungs, and lateral ventricles of the brain, or in the ducts or cysts of sarcomatous tumours. Here a careful consideration of the concomitant circumstances, and the situation and characters of the tumour, must assist the diagnosis. When these groups, on the other hand, are old, and contain young cells within them (Figs. 69, 70, 117), they cannot be mistaken for any other kind of growth, and their detection is most valuable, and at once establishes the diagnosis.

The power of distinguishing between groups of cells can only be valuable during the progress of a case, where portions of the morbid growth can be obtained for examination. If the tumour be still covered with integuments, M. Küss<sup>1</sup> of Strasbourg has proposed extracting a portion of it with an exploring needle, having at its extremity a small depression with cutting edges. In this manner a sufficient quantity of the texture may be removed for examination, and its nature ascertained. This proposition seems to me well deserving the attention of surgeons in all cases where the nature of the tumour is doubtful, and where certainty or uncertainty is likely to influence the practice. I have only had an opportunity of testing the value of this plan in one case, in which Mr Miller made the necessary puncture in a tumour over the parotid gland.

In open sores, on the other hand, a microscopic examination will always be of great importance, and the distinction of cancerous ulcers from those dependent on softened or ulcerated epithelial, cartilaginous, or fibrous growths, is destined to be of incalculable value. In a small nodule removed by Professor Simpson with his finger from the upper part of the vagina, I had an opportunity of clearly establishing the cancerous nature of the ulcer, as it contained cells closely resembling those represented Figs. 36, 37. That, in this situation, many epithelial and fibrous growths and simple ulcers have been mistaken for cancer there is no doubt, and there can be as little that the persevering use of the microscope is likely to be of the utmost service in the diagnosis of these cases. Many of the indu-

<sup>1</sup> L'Union Médicale, 1 Avril 1847, and Monthly Journal, May 1847, p. 853.



rated ulcers occurring on the under lip, hitherto called cancerous, may easily be proved to be in their nature epithelial (Obs. XLI. XLII.), and the same may be said with respect to so-called malignant ulcers of the scrotum and tongue (Obs. LV. LVI.) In one case, Obs. LVI., I carefully examined small nodules cut off from the surface of the ulcer with a microscope, and pronounced it to be an epithelial and not a cancerous growth, a diagnosis which was fully confirmed by a subsequent minute examination of the excised part, (Fig. 149 to 154). Professor Sédillot of Strasbourg states, that he has repeatedly found a microscopic examination of parts from the surface of an ulcer of the greatest service in his practice, and that he has been led to modify operations, which have succeeded on account of the information so obtained. To this point I shall again allude under the head of treatment.

No doubt many inquiries and many records of cases will be required before cancerous and cancroïd tumours may be diagnosed with the aid of the microscope, so perfectly as diseases of the heart and lungs may be ascertained by means of percussion and auscultation. Accurate conclusions, as previously stated, can only be arrived at by investigating *all* the circumstances of the individual case. I have just alluded to the points to be attended to when examining the structure of cancerous and cancroïd growths, it may now be serviceable to contrast the ordinary appearance and progress of the latter with the account previously given of the former (Chapters 3d and 4th).

II. *Diagnostic Value of the Symptoms and Ordinary Appearances of a Growth, conjoined with a Knowledge of its Structure.*—It may be useful, besides calling attention to the points just noticed, to state generally what other facts may assist the diagnosis of cancroïd from cancerous growths.

1. *Fibro-nucleated Growths.*—In giving this name to a particular kind of growth, distinguished by the presence of fibres, among which are infiltrated naked nuclei, I have pointed out an histological fact. Hitherto it has been confounded with sarcomatous, osteo-medullary, or encephalomatous tumours, and the number of cases in which it has been observed, do not enable me to draw up any distinctive diagnostic characters peculiar to it. There are three undoubted

instances of it recorded in Part I. In the first (Obs. XXXIV.) is presented the form of a hard tumour, the size of an almond, which sprung from the cicatrix, occasioned by the removal of a similar tumour seven years previously. It resembled to the eye a fibrous or sarcomatous tumour. In the second case (Obs. XXXVII.) the disease was situated in the parotid gland, was upwards of two years and a half before it produced a fatal result, which was brought about by paralysis of the nerves of deglutition. The tumour externally was nodulated, the size of the fist, hard, non-resistant, and caused no pain. On section it was of firm consistence, of yellowish white colour, and contained an infiltrated gelatinous substance. It was supposed to be cancerous by all who saw it. In the third case (Obs. XLVII.) the disease presented all the characters of the osteo-medullary sarcoma of surgeons, and though apparently originating in a local injury, seventeen years before it was observed, it reached a large size in six months.

Whether these cases will, on future inquiry, be found to be a peculiar form of fibrous growth (fibro-plastic), as Lebert seems to think, it is difficult to say. To me they present marked peculiarities in structure which entitle them to consideration. It is very possible that Obs. XLIII. also belongs to this class of cancroïd growths.

2. *Epithelial Growths.*—These growths generally commence in an induration or wart upon the skin or mucous surfaces. In the former position they are generally harder than in the second. Sometimes they constitute cauliflower excrescences or condylomata, made up of elongated papillæ, aggregated together, with their summits more or less flattened. In this condition their diagnosis is generally easy. At other times, sooner or later after their formation, they soften externally, and become covered with crusts of inspissated pus and epithelium. This, on separation, leaves an ulcerated surface, presenting irregular clefts or depressions between the hypertrophied papillæ, the edge is everted, and the base and margins greatly indurated. The ulcer may slowly spread over a considerable portion of the surface, and cause great swelling of the lymphatic glands from the irritation produced. In this condition such ulcers are usually considered to be cancerous.

The progress of an ulcer, commencing externally in warty excrescences, spreading laterally, slowly, and proceeding from without

inwards, is distinctly opposed to the progress of cancer, which almost invariably commences deep-seated, produces ulceration secondarily by thinning of the integument, and throws out subsequently and rapidly fungoid masses. Hence the progress of the case is often diagnostic. This, conjoined with the microscopic examination of the projecting papillæ, and the absence of cancer cells, will in most cases sufficiently establish the nature of the disease.

3. *Fibrous Growths*—It is utterly impossible in an early stage to distinguish these growths from scirrhus; indeed there is every probability, as formerly stated, that at their commencement they are identical. Of the truth of this statement experience is every day confirming the truth, and evincing that the distinctions which are to be found in surgical works are altogether insufficient for the purpose. When a hard knot or induration follows a blow or injury, it may result from a simple exudation; but that is no proof that it may not ultimately become cancerous. Again, if it be in a young individual, the probability is that it will be more innocent than if it occur in adult or advanced life. The only positive method of diagnosis, however, is in the use of the exploring needle, and a microscopic examination. In such a case the absence of cancer cells, and the presence of fibres, either alone or mingled with naked nuclei, or fibro-plastic corpuscles, seem to establish the diagnosis, although great care in the examination is necessary.

When more advanced, fibrous tumours, from their partial elasticity, smoothness, and regularity of surface, present characters which distinguish them from the irregular nodosities and stony hardness of scirrhus, and the pulpy feeling of encephaloma. These symptoms, however, are very deceptive. But here a microscopic examination cannot fail to yield clear results; groups of cancer cells in advanced scirrhus and encephaloma being very evident, and their absence in consequence proportionally diagnostic.

4. *Cartilaginous Growths*.—When enchondroma occurs in the extremities, and especially in the fingers and arms; is connected with the bones, and surrounded by an osseous capsule,—its diagnosis from cancer is exceedingly easy. But when it is deep-seated, covered with soft parts, and has no distinct bony capsule, its detection is very difficult. It may thus be readily confounded with cancer of the

bones, of which disease it presents all the general symptoms and signs; and as we have seen, if it be softened it is not easily separated from cancer with the aid of the microscope, even after excision. It is most common in young subjects; but cancer itself, when present in the bones, exhibits a greater disposition to attack persons earlier in life than when it occurs in other tissues. Its slow progress is more distinctive, cancer of bones being generally rapid in its course; but this sign alone cannot be depended on. In doubtful cases a microscopic examination of the tumour by means of the exploring needle may be attempted, and, if a *solid* portion of enchondroma were removed, the diagnosis could be at once determined. But if a *softened* portion be extracted, great difficulties would attend the formation of an exact opinion. The effects of water and acetic acid ought of course to be tried, and the angular form of the corpuscles observed; but, in the present state of our knowledge, no great confidence could be placed in this method of inquiry.

5. *Fatty Growths*.—Simple lipoma, and most encysted fatty tumours, are readily distinguished from cancer, the first by their lobulated, and the second by their rounded form, together with the doughy feel and non-attachment to surrounding parts. Experience has shown, however, that a fatty growth may assume all the symptoms and signs of encephaloma, of which Sédillot cites a remarkable example in a man forty-seven years of age. The growth returned twice after excision, and was removed by him, from the thigh, for the third time. This man not only presented the cachectic aspect, but all the local lancinating pains, the form, feel and appearance of an encephaloid growth. After its removal, a professor pointed it out to his pupils as an excellent example of encephaloma, and yet on a microscopic examination it was shown to consist of nothing but adipose and filamentous tissue, and a chemical analysis proved it to be almost entirely composed of fat.<sup>1</sup> Adipose tissue is fortunately easily distinguished under the microscope.

<sup>1</sup> Sédillot, *Op. Cit.*, Obs. XXIX. p. 95.—In connexion with the case, the following observations of this distinguished surgeon, the first clinical professor in France who availed himself of the advantages of the microscope, are not unworthy of consideration:—"Here, the microscope not only threw light on, but rectified the diagnosis, and, without its aid, we should have indubitably believed that we had operated on and cured a cancer. How many observations have been,

6. *Tubercular Growths* are rarely confounded with cancer. They only simulate it when the glands are enlarged in youth, and at an age when cancer scarcely ever attacks the frame. Undoubtedly many of the so-called cases of cancer in the young are softened tubercle. The nature of the growth may be suspected from its cheesy consistence and absence of cancerous juice ; while the differences between tubercle and cancer corpuscles under the microscope are so great as to be unmistakeable. The only danger is confounding tubercle with the reticulum of cancer, which it closely resembles, and a mistake that a critical examination of all the concomitant circumstances will alone enable us to avoid.

A more minute detail of diagnostic differences between cancerous and canceroid growths, is connected with their special study in particular organs, and doubtless yields most valuable results. This, for reasons which have been formerly adduced, I cannot enter into. I feel satisfied, however, that it is not upon the peculiarities incident to each organ *alone* that a perfect diagnosis can ever be formed ; but that there should be conjoined with these a knowledge of the structure and natural progress of these diseases, together with the necessary practical skill for determining their physical characters by means of the microscope.

The preceding observations refer entirely to the formation of a diagnosis in the living subject, and before removal of the morbid part. After death, or when the excised growth is capable of being made the subject of an anatomical examination, there are few instances in which a microscopic examination is not capable of positively determining its nature. When we observe the uncertainty with which surgeons and morbid anatomists often regard a tumour, and the doubts they entertain, after the most careful inspection (by sections, washings, and squeezings), whether it be cancerous or not, we are obliged to confess that any additional means which may remove the uncertainty, and solve the doubt, would be of extreme value. This the microscope furnishes us with, and a careful examination, and are still daily published, which are valueless from not being completed by a microscopic examination ! The time is arrived to enter upon a more advanced path, and surgery ought to surround itself with all the advantages which the physical and chemical sciences can bestow." —P. 99.

conducted with its assistance in the manner described pp. 1 and 2, will most commonly furnish positive information in the most uncertain cases. But even then there will always exist a few instances of epithelial, cartilaginous, or even sarcomatous growths, where the diagnosis is very difficult, if not impossible, and where great caution should be exercised; but these, I feel satisfied, may in the present state of science be considered as of extreme rarity.

I cannot conclude this chapter without remarking, that all those who are not habituated to the use of the microscope, should be very careful in arriving at conclusions by its means. A knowledge of the structure of morbid tissues must be preceded by that of healthy textures, and no instrument requires more time, labour, caution, and dexterity to make it available for useful purposes. Still its employment by the younger members of the profession is daily increasing, and will before long, in their hands, I trust, yield the most advantageous results. How few, comparatively, since the days of Laennec, have made themselves thorough masters of auscultation! Let us hope that the cultivation of histology will prove equally useful, and be more widely extended.

## CHAPTER VII.

## PROGNOSIS OF CANCEROUS AND CANCROID GROWTHS.

UNDER this head I shall make a few remarks, 1st, on the supposed uniform fatality: and, 2nd, on the tendency of these growths to return. The question of cure (more especially by excision) I shall discuss in the next chapter, on Treatment.

I. The necessary fatality of cancer has been so impressed upon the minds of practitioners and anatomists, that it enters with them as a necessary element into their definition of the disease. Thus Müller says, "Those growths may be termed cancerous which destroy the natural structure of all tissues, which are constitutional from their very commencement, or become so in the natural process of development, and which, when once they have infected the constitution, if extirpated, invariably return, and conduct the persons who are affected by them to inevitable destruction."<sup>1</sup> With the greatest deference to this distinguished anatomist, it may be said, that not only are there no grounds for such a positive statement, but that facts prove it to be erroneous. To me it appears equally unpathological to talk of any disease being *invariably* fatal, or *invariably* curable; for the most innocent sometimes kill, and the most malignant sometimes terminate in cure.

I have brought forward facts to show that cancerous growths do not necessarily go on enlarging until they kill, but that sometimes they become abortive. It is exceedingly difficult, however, to prove that cancer has been wholly obliterated from the system; for if, after an operation, the disease does not return, doubts would be held as to whether the part excised had really been cancer. Indeed this is

<sup>1</sup> Müller, Op. Cit., p. 28.

frankly stated by Gluge,<sup>1</sup> who observes, "that the best surgeons have seen so many fatal returns of the disease after extirpation, that they have considered the few successful cases not to be cancer." It must be obvious to any unprejudiced mind, that conclusions of this kind can never lead to an improvement in the medical art. Again, if, after a supposed spontaneous cure, no trace of cancer remain, it may be denied that the cicatrices or concretions discovered are evidences of healing. Hence, then, the importance of the observations which have been detailed, (Obs. XV., XVIII., XIX., XXXI.)—which point out the occasional efforts of nature to a spontaneous cure, and satisfactorily prove, that while cancer has healed in one organ it still lingers in another; in other words, that sufficient anatomical traces of its existence remain for identification.<sup>2</sup>

Dr Walshe<sup>3</sup> observes, "Cancer is not, as a matter of absolute necessity, a fatal disease; but the number of recoveries, happening in either of the ways mentioned, is relatively so small, that, practically speaking, they are almost without numerical value, and may be excluded from consideration." But I can no more agree with this modified statement than with the unqualified one of Müller. The established recoveries may be small in number; but their numerical value is altogether unknown in the present state of science, and will remain so until we possess statistics founded on facts, instead of mere opinions. It is very probable that careful examination will show a very great increase in the number of spontaneous cures. Such is certainly my own opinion. On the other hand, I protest against the idea, that any kind of cure, however seldom it may occur, ought to be excluded from consideration. On the contrary, it is exactly on these cases that our attention ought to be exclusively fixed, in order to discover in what manner, and by what means, nature has effected the cure. It is only in this manner that we can ever hope to found a rational system of therapeutics.

I have already stated reasons for believing that a cancerous growth is for some time purely local. How often does it happen that indolent tumours exist in a breast or elsewhere for years, without making

<sup>1</sup> Gluge, *Op. Cit.*, Lief. 12, p. 5.

<sup>2</sup> For numerous other instances of the fatty, calcareous, and fibrous degeneration of cancer, see Bruch, *Op. Cit.*, p. 550; Bochdalek, *Op. Cit.*, pp. 59, 65; Cruvelhier, *Liv. xxvii. pl. 3*; Walshe, *Op. Cit.*, p. 77.

<sup>3</sup> Walshe, *Op. Cit.*, p. 171.



progress, or causing inconvenience; and that, after a certain time, they suddenly increase, and exhibit great powers of development? A fibrous vascular tumour may have existed, in the filamentous meshes of which a cancerous exudation has been afterwards infiltrated. In this indolent state a tumour may often be discussed by appropriate means, and, if excised, be permanently eradicated. Even when the growth has become undoubtedly cancerous, ablation is stated to have been occasionally followed by the most perfect success. Doubts must always exist regarding such cases so long as no authentic record is preserved of the minute examination of the tumour removed. Every experienced surgeon who adopts a favourable or unfavourable view of this question, can point to crowds of cases in support of his opinion; but when he is asked whether the growth operated upon be truly cancer or not, it will be found that there are no positive grounds on which to form a conclusion. He *considered* it to be cancer, nothing more.

In the present state of our knowledge, then, I believe that there is no possibility of pronouncing accurately whether an operation will be successful or not. It appears to me that all analogy opposes the doctrine of the necessarily fatal nature of cancer, or of any other morbid alteration of the economy. There was a time when phthisis pulmonalis was also thought to be necessarily fatal, and when recoveries from it led practitioners to doubt their diagnosis rather than the truth of a received dogma. Morbid anatomy has exploded that error, as it will doubtless do that regarding cancer.

Although Müller has stated, in his definition of cancer, that, if extirpated, it invariably returns, and leads to inevitable destruction; he also makes the contradictory assertion, that it cannot be doubted that true carcinoma has, in some very rare cases, been cured by extirpation.<sup>1</sup> He gives one case, in which he proved the excised tumour by examination to be a true cancer. One well authenticated case is quite sufficient to prove all that is wanted, as it leads to the inevitable conclusion, that what has happened once may occur again and again. Were it necessary, however, I could fill whole pages with citations from authors, all of whom have given cases of the permanent cure of cancer by excision. But they are all open to the objection, that the tumour removed was not *proved* to be cancer. This does not apply to a case by Sédillot,<sup>2</sup> which, if it

<sup>1</sup> Müller, Op. Cit., p. 84-85.

<sup>2</sup> Sédillot, Op. Cit., Obs. XXX., p. 99. Planche VIII.

ultimately recovered, must be considered one of the most remarkable on record. It occurred in a woman, aged thirty-five, who entered the hospital with a cancer of the knee, which had been previously extirpated *nine times*. It was removed for the *tenth time* on the 15th of July, and again returned on the 1st of September following. The thigh was amputated on the 6th of November, and she was dismissed on the 30th of March in perfect health. On the 1st of August (nine months after the operation), the cicatrix remained sound, and no appearance of return was observable. A careful microscopic examination of the tumour was made by M. Küss, who discovered numerous cancer cells, which he has figured.

II. The second point in the prognosis is, the probability of cancer returning after a temporary cure has been established. There can be no doubt that such growths do exhibit a great tendency to return. This fact, instead of leading us into dangerous generalizations, destructive to our hopes of eradicating it, should induce us, by increased exertions in research, to ascertain whether this return be invariable in all cases, or only occasional; and, if the latter, what circumstances differ in these from such as exist in the former. It is in this point of view that a microscopic examination, by separating with certainty cancroid from cancerous growths, will do so much to improve our prognosis. But no advance can be made in such an inquiry until the nature and structure of the growth excised be ascertained.

It is now well understood, that not only cancerous, but the most innocent growths may return after excision. It is generally supposed, however, that in all such cases the second growth originates in some germ which had been left in the part. Hence, it is of great importance to separate a recurrence in the seat of a former tumour, from that occurring in other places or textures. The former is not necessarily to be dreaded. Numerous instances are on record, of fatty, fibrous, and encysted growths returning again and again, and being finally extirpated with success. I have alluded to a fatty growth, ultimately cured by Sédillot after the third excision (p. 228); the return of a fibrous growth after twenty-nine years is recorded, Obs. XXXVIII.; and of a fibro-nucleated growth after seven years, Obs. XXIV. Epithelial growths also occasionally return, but enchondroma, according to Müller, does not. On all these points, how-

ever, it is absolutely essential to obtain more accurate information before arriving at decided conclusions.

It does not necessarily follow, that because a growth appears in more places than one following an operation, that therefore it is cancerous. Warty and encysted growths may occur in several places on the surface; fibrous tumours may be scattered throughout the body of the uterus, or in other situations; and neuroma occur extensively in various nerves. These cases, however, are rare, and are seldom confounded with the return of cancer in different organs; so that when, after an operation, the disease appears in another part of the body, the prognosis is very unfavourable.

Cancer, after it has existed a certain time, has a great tendency to extend itself to the lymphatic glands in its neighbourhood. It must not be supposed, however, that swellings of such glands following the appearance of a local tumour, is any certain proof, either that the disease is cancer, or that, therefore, it is necessarily fatal. The same effect follows all irritating local disorders, and it is frequently very difficult to determine whether, in cases of undoubted cancer, such secondary swellings originate from simple inflammation, or engorgement, or the formation of cancerous matter. In cancrioid growths the same thing happens, and I have recorded two cases (Obs. LV., LVI.) where the lymphatic glands in the neighbourhood of epithelial ulcers were enlarged. As such swellings of the lymphatic glands indicate a certain continuance of the disease, and a tendency to spread, their occurrence will render the prognosis more unfavourable than when they are not present; but whether they affect the prognosis as much in cancrioid as in cancerous cases, is a question yet to be decided.

## CHAPTER VIII.

## RATIONAL TREATMENT OF CANCEROUS AND CANCROID GROWTHS.

AN empirical practice in cancerous and cancroid growths has notoriously failed, and we must look to a knowledge of their anatomy and pathology for the correct principles of treatment. Not that we are to neglect the knowledge derived from experience; but that this should be directed in such a manner, and so employed, as, if possible, to harmonize with and elucidate scientific facts.

We have seen that a cancerous growth is a vascular structure, which consists of nucleated cells infiltrated among a fibrous stroma, and that its power of growth, extension, and re-development, is dependent on the amount of cells it contains. It follows, that to retard the growth of the cancer cell when once formed, is to retard the advance of cancer itself, and that to render it non-productive is to arrest its progress. If it be true that a cancerous growth may, to a certain extent, be local, it follows that the earlier it is excised the better the chance of eradication. Lastly, if the origin of a cancer depend upon the peculiarities inherent in the exudation poured out, our hopes of prevention, and especially of preventing a return after excision, must depend upon our discovery of what those peculiarities are; upon our power of obviating them, and restoring the healthy condition of the economy. I consider it unnecessary to treat of the palliative modes of treatment, with which every practitioner is acquainted, and which may be found detailed in every work on surgery. I shall, therefore, confine my remarks to the three great points of interest now alluded to; namely, 1st, means of retardation and resolution; 2d, means of extirpation; and 3d, means of prevention.

## I.—MEANS OF RETARDATION AND RESOLUTION.

The growth of all cells in the vegetable, as well as in the animal

world, is more or less dependent upon certain external circumstances which are under the control of man. Thus, their development is favoured by an elevated temperature, a proper supply of moisture, room for expansion, and by certain localities. It is principally by a regulation of the two former, that the horticulturist is enabled to push forward the growth of plants in climates where, otherwise, they could not exist. An attention to locality and the nature of soils, is also a matter of vast importance to the agriculturist. The influence of these agents is no less observable in the animal world. All eggs and young animals require warmth to favour their growth, and maturity is reached earlier in the tropics than in temperate regions. In the same manner, excessive cold, dryness, want of room, and unfavourable position, are circumstances hostile to cell development. But it requires no lengthy argument to prove the great influence of these agents on vital growth. The vegetation and bloom of spring and summer,—the effects of the wet season in warm climates, and the periodical inundations of certain countries,—the heat necessary for animals and vegetables, and indeed all the phenomena of growth, sufficiently attest the effect of temperature, moisture, space, and locality.

When we observe that nutrition throughout the animated world obeys certain laws, we must feel persuaded of the reasonableness of endeavouring to destroy growth, by removing or counteracting the circumstances which favour, and putting in force those which are hostile to, it. Such, indeed, is the truth and uniformity of nature, that nothing which operates can do so contrary to any correct principles she imposes. Hence those means which have been blindly adopted by empirical practitioners, if they fail, do so because they act in opposition, and if they succeed, it is because they are in harmony with her laws. The only methods of treatment which have been proved to possess the slightest effect, may be shown to be those which a knowledge of anatomy and pathology would have dictated. As means of retardation, therefore, the following points deserve consideration; namely, the influence of cold, dryness, pressure and locality.

1. *Cold*.—In a cancerous growth, the tendency of which is to excessive cell formation, we evidently retard its advancement by the application of cold. Were it possible, indeed, to bring down the

temperature of an entire growth below the vegetating point, we must inevitably kill it ; but, supplied as it is with heat through the warm blood from within, this is impracticable. Still, the external application of cold is one of the most powerful means we possess of retarding the progress of a cancerous or any other kind of growth.

2. *Dryness*.—We have previously pointed out that the development of cell growth is dependent on its being continually supplied by a nourishing fluid or blastema. It follows, that if this could be cut off the growth would die. The ligature of an artery leading to the parts might be supposed capable of effecting this ; but the readiness with which the anastomosing vessels would again supply it, renders the plan of little service, except in particular cases. This plan, however, has been tried by surgeons, and not unfrequently with success. Magendie<sup>1</sup> arrested the growth of an encephaloid tumour on one side of the head by tying the carotid artery. Jobert<sup>2</sup> states that he has cured four ulcerated cancers (?) of the lip, and one of the tongue, by including in the ligature of the principal vessels the nervous filaments distributed to the cancer. Dr Hossack has applied a ligature to the carotid artery, in two cases of scirrhus of the parotid gland on the same side. In one case the growth of the tumour was arrested, and the suffering of the patient relieved. In the other case a completed cure was produced. “The tumour was of considerable size, of three or four years’ growth, interfered considerably with the motions of the jaws, and had caused closure of the external meatus ; the patient had been treated with iodine internally and externally, for two months, without the slightest benefit. Disappearance of the tumour followed the ligature of the vessel ; and not only this, but a depression eventually formed in the situation, in form precisely like that of the gland in its natural state, thereby showing its complete removal, together with that of the disease.”<sup>3</sup>

Dryness kept up externally, would have no direct effects in retarding a cancerous growth. But we should learn to avoid all lotions and wet applications, which have never done good, and must, from the well-known power of imbibition possessed by the skin, conduct

<sup>1</sup> Phen. Physiques de la Vie, Tom. I. p. 119.

<sup>2</sup> Brit. and For. Med. Review, Vol. IX. p. 260. 1840.

<sup>3</sup> Quoted by Walshe, from the American edition of his article Cancer, p. 204.

moisture to the part, and thereby favour the development of any cells it may contain.

3. *Pressure*.—That cells should have plenty of room to expand, is one of the circumstances necessary for rapid growth. The more solid a tissue the more slowly it grows; while cells, the natural habitat of which is in a fluid, are remarkable for the quickness with which they reach maturity, and the readiness of their re-development. The truth of this general law is well exemplified in cancer; scirrhus proceeds more slowly than encephaloma, and this last more rapidly after ulceration, when all restraints to its progress are removed. External pressure, therefore, which evidently prevents the expansion of cells, must be a most powerful agent for retarding growth, and, as such, may be expected to be highly beneficial in the treatment of cancer.

Pressure has been long used in surgery with a view of promoting absorption, and with the best results in a variety of cases of local swelling. Its real action in all these cases is, first, by restraining all growth; and, secondly, favouring the disintegration of cells, which necessarily leads to their re-entrance into the blood, and subsequent excretion through the emunctories. It may also operate by compressing the bloodvessels, and diminishing the supply of the fluid, on which the growth is essentially dependent. Thus it unites two modes of influencing cell development.

Pressure applied externally to so-called cancerous tumours has been pretty extensively tried, and been found successful sometimes in retarding, and at others in altogether removing them. Travers has seen cases of this kind, and Recamier gives the following results of the practice tried in 100 cases. He says of these, “sixteen appeared to be incurable, and underwent only a palliative treatment; thirty were completely cured by compression alone, and twenty-one derived considerable benefit from it; fifteen were radically cured by extirpation alone, or chiefly by extirpation and pressure combined, and six by compression and cauterization; in the thirteen remaining cases the disease resisted all the means employed.” Dr A. R. J. Bayle, out of 127 recorded cases, gives 71 cures, 26 improved, and 30 unaffected.<sup>1</sup> Other individual cases have been recorded with similar good results.

The mode of applying pressure was very faulty, until Dr Neil

<sup>1</sup> Walshe, *Op. Cit.*, p. 208.

Arnott invented the apparatus figured and described by Dr Walshe. It consists of a spring, an air cushion supported by a flat resisting frame or shield, a pad, and two belts. It may be used without interfering with the movements of the thorax, and the amount of the pressure can be nicely regulated, and equably applied. It causes great relief from pain, and is useful in ulcerated cases for restraining hemorrhage. Dr Walshe gives a carefully recorded case, where a tumour of the female mamma, having all the external signs of scirrhus, and which it was proposed to remove by the knife, was entirely resolved by means of this instrument.

If pressure alone be capable of producing such good results, its conjunction with one or more of the other circumstances capable of retarding growth may be attended with even greater utility. It appears to me, that the apparatus recently invented by Dr James Arnott<sup>1</sup> of Brighton, by means of which pressure might be combined with external cold and dryness, is directly indicated, and deserves to be tried. Or his apparatus, applied when the patient is at rest, may be alternated with that of Dr Neil Arnott, where exercise is desirable.

4. *Locality*, as well as temperature and moisture, exerts great influence over cell development. Certain plants and animals are peculiar to certain soils and regions; others, while they may inhabit many countries, flourish more luxuriantly in some than in others. We observe the same facts in the diseases to which animals are subject, and particularly in cancer, which exhibits a peculiar predilection for certain organs, and seems even to be more virulent in some than in others. At first sight it may appear difficult to determine how an observation of this truth can assist our means of retardation; but a study of the kind of tissues most favourable for the growth of cancer, may give us some indications of the mode of so regulating nutrition as to modify its progress or prevent its return. To this subject I shall again allude under the head of means of prevention.

## II.—MEANS OF EXTIRPATION.

The means of extirpation consist of—1. The excision of the part.  
2. Chemical agents which destroy texture.

<sup>1</sup> On Indigestion, &c., with an Account of an Improved Mode of Applying Heat or Cold in Irritative and Inflammatory Diseases. 1847.



1. *Excision.*—The principles which should guide the surgeon in excising morbid growths have excited great discussion, and, as occurs in most medical subjects, while experience has been put forth as the sole guide to our knowledge, in reality the wildest hypothesis and conjecture have been the real foundation of the controversy. Of this the whole history of medicine furnishes a proof, and no better example of it can be chosen than the discussion which occurred in the French Academy of Medicine in 1844, where all the celebrated surgeons of Paris stated their opinions on the very subject I am about to treat.

On that occasion M. Cruveilhier read a memoir, in which he maintained that surgeons are continually cutting out fibrous tumours from the female breast which never undergo cancerous transformation, and which therefore might be allowed to remain with perfect safety. So far from fibrous growths ever degenerating into cancer, he considered that they indicate a state of constitution altogether incompatible with malignant action; so that, in being able to detect them in the breast or uterus, he has confidently assured the patients that they would never be subject to cancer. In support of these statements he brought forward cases of tumours in these situations which had existed from ten to thirty years, and cited one exceptional instance, where cancer having attacked a breast already the seat of fibrous tumours, these remained unaffected, while all the rest of the organ was cancerous. He pointed out that cancer always depended upon a constitutional disorder, that local disease was the effect and not the cause, and to remove the first, while the latter was allowed to remain, was an irrational practice.

In these opinions M. Cruveilhier was supported by MM. Velpeau and Jolly. The first maintained that he could diagnose fibrous, or what he called fibrinous, tumours of the mamma, which never degenerated into cancer, although he frequently removed them to tranquillize the patient, or to get rid of a deformity.

On the other hand it was contended by most of the practical surgeons of Paris, including the names of Blandin, Gerdy, Roux, Amussat, Bérard, and Lisfranc, that it was impossible to diagnose fibrous from cancerous tumours of the breast at an early period; that the former were only an incipient stage of the latter, and consequently frequently degenerated; and that the best practical rule to be followed was always to excise them as early as possible. They

maintained that the disease was first local, and that the cachexia was induced by absorption from the morbid growth—was the cause, and not the result. They denied the law of incompatibility, sought to be established by M. Cruveilhier, and denounced his paper as one likely to be followed by the most injurious consequences in practice.

In support of these opinions, numerous cases were cited, having all the symptoms and characters belonging to what M. Cruveilhier called fibrous tumours, which afterwards became cancerous, and destroyed the patient. Some specimens also were brought forward, where tumours, originally fibrous, had apparently undergone the cancerous transformation, even in the uterus. Many surgeons brought forward instances of tumours, to all appearance truly cancerous, which were excised, and where there had been no return for a long series of years.

This celebrated discussion left the practical question in the same state as before; namely, that as a matter of prudence all tumours should be removed from the female breast, whatever be their nature. No one practitioner who took a part in it, appeared to be aware of the real structure of cancerous tumours, or knew that a fibrous as well as a foreign growth was invariably present in them. Indeed, many cited, as the best proof of cancer, the presence of the dense fibrous structure, often grating under the knife, which is exactly that part of the tumour which is least malignant.

A knowledge of the structure and natural progress of cancerous and cancroid growths, must in future exempt surgeons from much of the doubt and difficulty they formerly experienced. At the same time, it cannot be denied that considerable obscurity still hangs over our knowledge of the pathology of cancer, and that there are no means of diagnosing a cancerous from fibrous and other forms of cancroid growth at their commencement. It seems to me certain that a cancerous may supervene upon a cancroid growth, and that both for a time may be local; so that under all circumstances, where the nature of the tumour is doubtful, after means of retardation and resolution have had a fair trial, excision should be at once had recourse to. As there is no possibility at an early period of knowing whether the growth may or may not ultimately become cancerous, prudence demands that, *so soon as it becomes evident that these means have failed to arrest its progress*, an operation should

be had recourse to. If *early* excision were more practised, many of the lamentable cases which occur would never arise.

Many cases are met with in practice, where hard lumps or nodules occur in various parts of the body, which cause little inconvenience for years. These are the cases in which means of retardation and resolution are most likely to be beneficial, especially when conjoined with the means of prevention to be afterwards noticed. The rule for excision must be guided by particular circumstances, such as the inconvenience or anxiety felt by the patient; but, above all, by the period of life. Tumours, which need cause little alarm during youth, become more dangerous as the age advances towards thirty-five, and from that to fifty. Thus, in a young person, longer time may be devoted to the employment of retarding and preventive means, than it would be prudent to do in adult age.

From the conflicting statements of the most experienced surgeons as to the utility of excising *advanced* cancerous tumours, it is impossible to draw any conclusion. Those whose experience is favourable, may have mistaken cancrioid for cancerous tumours; whereas those who are unfavourable, may, from the particular kind of their practice, have operated for the most part in advanced cases. Consulting and skilful operating surgeons of reputation, for instance, are generally applied to as a *dernier resort*, after the fears and timidity of the patient, or the desire of the ordinary medical attendant, have induced them to lose much valuable time in trying various remedies. Be this as it may, it cannot be denied that many of those who are best entitled to give an opinion, are opposed to interfering with the progress of cancer in any way, when the nature of the disease is clearly made manifest to them. This is done on the avowed principle, 1st, that cancer is in its nature incurable; 2d, that it is cruel to inflict on a dying individual a surgical operation destined to be of no use; and 3d, that such operation, if performed, would hasten the fatal termination.

But however justified surgeons may feel themselves, from the result of experience, in arriving at these general conclusions, cases frequently occur which show how dangerous it is in practice to adopt them as principles which are to be invariably carried out. One object of this work is to show that surgeons, up to the present time, have been continually confounding together various kinds

of growths. Yet canceroid growths, such as epithelial and enchondromatous, if allowed to proceed, will ultimately destroy the patient as certainly as cancer; and there can be little doubt that many of these have been allowed to do so under the idea that they were malignant. In this manner many surgeons, by avoiding one error, have fallen into another, and in their laudable desire to prevent unnecessary operations, have refused to interfere in cases in which, had they done so, the patient would very probably have recovered. In short, to carry out their own views, the diagnosis should have been well established, and, before condemning an individual to certain death, it ought to have been rendered manifest that the disease really was what it was supposed to be. That this has not yet been accomplished, the observations detailed in the first part of this treatise must sufficiently demonstrate.

Supposing, then, that the principles now so generally acted on in this country be correct, viz., that cancer once present can never be eradicated by the knife, it must be evident that surgeons are the more bound to use every means in their power to prevent the possibility of mistaking any other growth for it. With this view not only symptoms and signs must be carefully inquired into, but instrumental aid must be employed. No surgeon would perform the operation of lithotomy, merely because of the symptoms it occasioned; he would first insist on introducing a sound and feeling the stone. So no surgeon will, in future, be warranted in refusing to operate for a suspicious growth, unless he can see, by the aid of the microscope, the structure which separates cancerous from canceroid growths, and demonstrate that the conditions he has imposed upon himself are really fulfilled.

But it may be asked, are these principles correct? Is it true that cancer is necessarily incurable, or has this opinion arisen simply from the want of success in treatment? The latter explanation seems to me to be the just one; for that cancer may occasionally be cured, is not only demonstrated by morbid anatomy, but might be proved by a host of cases in which removal of the growth has been followed by no renewal of the disease for many years. So far, therefore, from our being justified in not operating, the question ought to be, not as to whether cancerous should be separated from canceroid growths, and then left to pursue their course, but whether any cases of cancer ought to be exempted from the chance of recovery which an operation holds out.

On this point Lebert seems to have come to a conclusion diametrically opposed to that of most modern surgeons. He says, "when a cancer well localized does not cause much suffering to the patient; when, especially, it is found in an individual who has passed the age of fifty-five years, and in whom it follows a slow progress, it seems prudent *not* to operate. When, on the contrary, the disease marches rapidly and influences injuriously the general health, it will be necessary to operate promptly and largely, and to follow the cancer at each return with the same energy." He gives cases where, by acting in this way, immediate death was avoided, and life prolonged for several years. Thus, believing a true cancer to be altogether incurable, he has recourse to the operation merely as a palliative, and justifies it on the ground of the temporary relief it occasions.

But I believe that excision ought to be had recourse to, both as a curative and as a palliative remedy. Undoubtedly, the earlier it is performed, the more is it likely to be attended with permanently good results. But even in advanced cases it should be tried with hopes of success, and so long as it continues to *return in the same place*, the excision should be repeated. The case of Sédillot, formerly alluded to (p. 234), indicates what excellent results may sometimes attend an energetic practice, based on rational principles; whereas, allowing a man to die on the hypothesis of a disease being necessarily fatal, can never do good, whilst it may often lead to the most lamentable results. When, on the other hand, the disease attacks internal organs, excision as a general rule ought not to be practised, unless strong circumstances, peculiar to the individual case, demand it, or there is a probability of its prolonging life.

The practical rule, then, which pathology and experience unite in causing us to adopt, seems to be this, *that so long as a cancer remains fixed in a part which is capable of being removed, and the strength of the patient is not too much reduced, so long is the surgeon warranted to interfere.* If this applies to cancerous, it does so with tenfold force to canceroid growths, which every thing that we know warrants us in asserting are much less fatal and malignant.

As regards the mode of operating, I must refer to surgical works. It is only important to remark, that in every case the removal of the disease should be complete, and a considerable portion of the surrounding tissue excised with it. A few cancer cells may easily

infiltrate themselves among textures, without being appreciable to naked sight; and, there is every reason to suppose, that a neglect of this rule has led to its return. The same caution as to perfect eradication is also requisite with some cancroid growths, especially the epithelial and fibrous, the occasional return of which is a circumstance that, more than any thing else, has led to their being confounded with cancer. With regard to them, however, the rule is by no means so absolute, and has occasionally been departed from with success, after a careful microscopic examination has determined the nature of the growth. Thus, in epithelial ulcerations of the lip, where, in order to prevent deformity, it is important to preserve as much of the parts as possible, Sédillot has barely removed the indurated structure, and thus preserved a larger amount of soft textures than he would have been warranted in doing had the disease been cancer. Again, Mr Goodsir having shown, by a minute examination, that the ordinary fungus of the testicle was composed essentially of the tubular structure of the organ, Mr Syme confidently recommended an improved operation for its preservation.<sup>1</sup>

These brilliant results are mere indications of what the surgeon might accomplish were his diagnosis rendered exact by means of the microscope, and his mind relieved from its present uncertainty as to the nature of the growth. In like manner, by operating at an early period in all cases of suspected tumour, and keeping careful records, both of the minute structure removed, and of the ultimate results, much advantage would be gained to surgery. Lastly, by boldly excising all cancerous growths within his reach, when, after careful investigation, he has satisfied himself that no internal organ is affected, and repeating the operation so long as the return of it is merely local, I feel persuaded that not only in many cases would life be prolonged and much suffering saved, but that some might be permanently cured.

The other arguments advanced in opposition to the practice of excision, are easily disposed of. No doubt it would be cruel to inflict an operation so long as it is believed to be of no ultimate use, or, still more, to be prejudicial. But when the hope of preserving life is shown by reason and experience not to be a chimera, but a reality, the whole argument falls to the ground. Who, knowing that he had been bitten by a mad dog, would not insist on the parts being

<sup>1</sup> Monthly Journal of Medical Science. January, 1845.

completely excised, rather than run the risk of having hydrophobia; and who, with almost the certainty of death before him, from the presence of a cancerous growth, would hesitate to submit to its extirpation, even for the faintest chance of life? Besides, the pain of operations is now under the control of the medical practitioner, through the discovery of the anæsthetic properties of chloroform by Professor Simpson; and thus the fear, on the part of the surgeon, of inflicting pain for a doubtful end, and the dread of incurring it on the part of the patient, are alike overthrown.

But it has been asserted that an operation often induces the disease to run a more rapid course than if it had not been interfered with surgically. This must be a very difficult proposition to prove; for how is it possible to calculate the length of time an individual would have lived under any circumstances? But, supposing it to be true, are we therefore to abandon all efforts at extirpation, and adopt a general rule which must consign thousands of persons to almost certain death? Rather let us endeavour to ascertain what are the circumstances which attend, and possibly cause a return of the disease. It is acknowledged by every one that *some* cases undoubtedly recover. Why should it happen that one person will be permanently cured, while in another the disease returns? There must be laws which regulate these occurrences, which, however, unknown at present, are certainly not beyond the scope of scientific research. Surely it would be more praiseworthy to make an endeavour to investigate a point of such great importance, than apathetically to imagine, that every thing has been done that man can accomplish, or to take shelter behind so called "rules of surgery," which, at best, are but theories founded upon the weakness and imperfections of art.

Do any rational means, therefore, remain to us whereby it is possible to discover why cancerous growths return more frequently than cancrroid ones, and if so, should they be put in practice? To both these questions I have no hesitation in answering in the affirmative. When a fibrous, fatty, or encysted growth returns after excision, it is universally attributed to the whole of the diseased parts not having been removed. May not many of the cases of cancerous growth which return, be attributed to the same circumstance? May not the success which follows amputation of cancerous testicles depend on the completeness with which, from their position, they may be separated from other textures? Germs, altogether in-

visible to naked sight, may be infiltrated among a tissue, which, instead of being excised, is only divided by the knife. This happened in Obs. XLVI., in which I found the muscles in the neighbourhood of the tumour so loaded with cells, that at the time I prognosed the return of the disease. Surgeons, however, up to the present time, have acted on the principle, that their sense of touch and naked sight, are means sufficient for determining whether the whole of a growth has been removed. That this is a complete fallacy must be acknowledged by every histologist. New researches, therefore, are necessary. Not only should the tumours themselves be carefully investigated after extirpation to ascertain their nature, but the neighbouring tissues should be examined, to determine whether they are entirely free of cancer cells and nuclei. The microscope ought to be a necessary instrument in the operating theatre, and every suspected tissue examined on the spot, before the lips of the wound are closed. It may be stated that this is impracticable; but when it is known that, proper precautions being taken, an expert histologist might make such examination in the short space of thirty seconds, and that several demonstrations could be accomplished in a few minutes, or while ligatures are placed on the vessels, it will I trust be acknowledged, that there is nothing very embarrassing in the proposition. The desire of leaving no means untried, should alone animate the practitioner. No doubt, it is troublesome to be under the necessity of entering into new researches on points which many consider already determined, and concerning which decided opinions have so long been held by numerous practitioners. Such, however, are the sacrifices which the further progress of medical science demands.<sup>1</sup>

I am aware that the propositions now advanced are altogether at variance with the opinions of many eminent men, for whom I entertain the highest respect. But the careful consideration of seven years; the minute investigation into many cases which have been allowed

<sup>1</sup> Dr Walshe has given nineteen propositions connected with the excision of cancer, which, although commencing with the comfortable assurance, that "the removal of a cancerous tumour *may* cure the disease," lay down so many circumstances where the return is "absolutely certain," or "the invariable result," as to present on the whole a very gloomy picture. These propositions appear to me to be founded too little on pathology, and too much on the fallacious statistics of the day.



to kill because they were considered malignant, and which I conscientiously believe might have been saved had other views with respect to them been held; and a regard for the present state of science, have convinced me that the important subject of the treatment of cancer by excision is not yet closed. I believe that new researches founded upon a knowledge of structure, and new observations guided by a clear conception of the importance of diagnosis, will lead to results that must materially modify our prevailing notions with respect to this disease. Without asserting that these researches will be successful, with a full knowledge of the fatal results that will probably, in the majority of cases, attend attacks of cancer, it has been my object to stimulate to future inquiry. Surely the subject is worthy of our labours, and nothing can be hoped from supineness, in a study where the most indomitable energy and perseverance can alone support our endeavours.

2. *Chemical Agents.*—Attempts have been made to destroy cancerous growths by cauteries of various kinds, which act chemically on the part in such a way as to destroy its vitality. Occasional cases have been recorded of the success of this treatment. But it must be very difficult to apply such remedies to the whole of a growth; while the irritation they occasion, by exciting fresh exudation, which the pre-existing germs of cancer may make the means of further extension of the disease, renders the probability of success very doubtful. The same objection does not apply to the treatment of cancroïd growths in this way; for in these cases the object is to remove the bulk of the morbid growth or ulcer, and cause healthy granulations, which, as there is only normal tissue present, though in increased quantity, is in no way interfered with. It is very probable, indeed, that most of the successful cases so treated were cancroïd rather than cancerous growths; but this, from the confusion that has hitherto existed in the diagnosis, it is impossible now to ascertain.

We have seen that certain chemical agents have a marked effect upon the cancer cell. Acetic acid especially, dissolves the cell-wall more or less, and strong potash reduces the whole to a granular mass. The continued application of these agents, therefore, would tend to dissolve the growth, if it could be brought into direct contact with the cells, and need not necessarily excite such irritation as to cause fresh exudation. The only objection is, the utter impossibility of

affecting the whole mass, even in cases of ulceration, and preventing the formation of deep-seated cells, while the superficial ones are destroyed. In certain cancroid growths, especially epithelial ones, the application of acetic acid is an established remedy, and should always be tried whenever it is thought possible to bring the fluid successively in contact with the entire mass of the disease.

### III.—MEANS OF PREVENTION.

Our principal attention, during the whole progress of cancer, and especially after excision, ought to be directed to modify the general health, and combat that peculiar disposition to cancerous exudation, or that something in the blood, which we have seen to be the origin of the disease. It has been endeavoured to accomplish this on empirical grounds, by giving all sorts of alteratives and tonics, such as mercury, iodine, arsenic, gold, copper, chloride of barium, &c. &c. But the universal failure of all such remedies not only exhibits their inutility, but the erroneous notions which led to their employment.

We have previously seen, that our knowledge of the essential cause and origin of cancer is very defective, if indeed it do not amount to nothing. Ignorant of the cause, rational medicine is powerless; but, by observing the circumstances under which the disease occurs, and contrasting it with others that seem altogether opposed to it in nature, we may infer that the laws which regulate and favour the one are at variance with those which govern the other.

I have previously endeavoured to show (p. 205)—that tubercle is essentially different from cancer; has a predilection for different textures; and occurs at a different epoch of life. It is a substance essentially albuminous, exhibits little tendency to organization, and its effects on the constitution are materially modified by the exhibition of animal oils. Cancer, on the other hand, is also albuminous; but we observe that it has a great tendency to rapid organization, and that in proportion as its power of cell growth increases it abounds more and more in fat.

An excessive cell development must materially be modified by diminishing the amount of fatty elements, which originally furnish elementary granules and nuclei; the circumstances which diminish obesity, and a tendency to the formation of fat, would seem *a priori* to be opposed to the cancerous tendency. Fat, however, is essential to a healthy nutrition in the economy, and there will always be a

difficulty in so regulating ingesta, as while, on the one hand, we prevent such an excess of adipose formation as not to favour excessive cell-growth, on the other, we may sufficiently contribute to the healthy nutrition of the tissues. In most cases of cancerous and cancroïd growths, however, it seems to me a prudent step to diminish all those dietetic substances easily converted into fat, including not only oily matters themselves, but starch and sugar.

But there is another source of fat in the economy, originating in the secondary digestion of the tissues, which we may operate upon with greater chance of success. By preventing accumulation from this source, we not only invigorate the system and keep the functions in order, but cut off one of the supplies of that material which keeps up excessive growth. This we can only do by taking care that the excretory organs properly perform their functions, and that the matter excreted bears a full or even increased proportion to the ingesta. By paying attention to the function of the lungs, skin, liver, and kidneys, and by promoting their action, we shall accomplish what is most necessary to obviate a cancerous tendency, and the disposition of the disease to return. It may be stated that this is only saying in other words, attend to the general health. But health is too often judged of by the appetite, amount of ingesta, and robustness of an individual, rather than by a due amount of the excretions, and a spare but active constitution. If a tendency to fat be an antidote to tubercle, as I believe it is, spareness may possibly be considered opposed to cancer. In the one case, we should do all we can to bring the nutrition up to and above the average; in the other, down to and below it.

I am willing to acknowledge that the views now offered are hypothetical, but so is every thing connected with the constitutional treatment of cancer. Much still requires to be done both by the histologist and the animal chemist before the relations of oil, albumen, and mineral matters are so perfectly understood, that we shall be able to explain why these principles are accumulated in particular organs and structures to form diseases, as they evidently are. Why, for instance, in phthisis pulmonalis, when the whole body is emaciated in the extreme, should the liver and kidneys undergo a fatty degeneration? Why, in certain persons apparently in perfect health, should the heart insidiously become so fatty that it suddenly ceases to beat? Why in some persons are these accumulations of fat stored up in cells pro-

duced for the purpose, constituting healthy adipose tissue ; whereas in others the fat enters pre-existing cells, as those in the lungs, liver, and kidney, occasioning fatty degeneration and fatal diseases of those organs? Why should these fatty accumulations occasionally be connected with increase in the fibrous or albuminous element, as in cirrhosis of the liver ; and why, in other constitutions, should the albuminous structure alone be affected, or calculi and other mineral collections be formed? Again, why should ultimate fibres of the same tissue, say muscles, sometimes be converted into fatty granules (Fig. 168), and at other times into albuminous filaments (Fig 99)? These are points which, although at present unknown, will, I trust, ere long be investigated and understood, and then we shall begin to have glimpses of what ought to constitute a sure and certain guide to the constitutional treatment of numerous diseases of nutrition, and, among the rest, of cancer.

In the mean time, I think that one practical rule of great importance may be derived from these speculations ; viz. that in all wasting diseases caused by mal-assimilation of the primary digestion, the animal oils are directly indicated, and that in all diseases accompanying accumulation of fatty matter in the economy they are contra-indicated. In the first class of affections are most scrofulous and tubercular diseases in youth ; in the second, cancerous diseases in adult and advanced life. But there are cases of tubercular disease with tendency to local fatty accumulations, in which oil is injurious ; and there are also cases of cancer, with emaciation from want of assimilation, in which it is beneficial.<sup>1</sup>

<sup>1</sup> While correcting these pages, my attention has been directed to a work on the treatment of tumours, by Mr Macilwain—(*The General Nature and Treatment of Tumours*. London, 1845). He gives cases where, by paying attention to the general health, minutely investigating into all the functions of the economy, and enjoining a rigid hygienic treatment, he has succeeded in arresting their progress, and even causing their absorption. No doubt the majority of tumours he speaks of were canceroid, but that is of little importance to his argument ; which is (following Abernethy), that local diseases are of constitutional origin. Many of the views and modes of practice of Mr Macilwain are founded on a rational basis, and deserve the careful consideration of the profession.

APPENDIX.



## A P P E N D I X.

---

I HAVE now shortly to state what is known of the ultimate results of those operations which have been referred to.

OBSERVATION I.—Having heard that the subject of this case had experienced a return of the disease, and was now in the hospital of the House of Refuge, I visited her, November 17, 1848, with the kind permission of Dr Fairbairn. On examining the breast, it was seen to be the size of a large foetal head, generally hard and indurated to the feel. The cicatrix of the former wound was visible about the middle of its upper third, and to the left was an irregular nodulated protuberance of a bright red colour, which was of soft consistence, had ulcerated in its centre, and was discharging blood and pus; at the inferior part of the tumour was another red spot, the size of half-a-crown, ulcerated in the centre. The glands in the axilla, and under the clavicle, were enlarged, and exceedingly painful to the touch. She is continually suffering great agony; her nights are sleepless, the general strength greatly diminished, and she takes little food.

According to her own statement, the glands in the axilla were affected before the operation in February 1847; and the pain in them has never ceased since, although the wound perfectly healed. In November 1847, a small lump appeared in the inferior part of the mamma, which was soon followed by the formation of others. These, to use her own words, caused the breast to feel “as if it were full of peas and beans.” The nodules gradually coalesced, until the breast assumed its present appearance. She is most anxious to submit to an operation even now, if it were thought advisable.

In the remarks appended to this case, I stated that I had selected it as a standard of comparison, and that another growth removed by Mr Spence (June 10, 1847), exactly resembled it in structure. Now it is singular that the morbid growth in Mr Spence’s case also returned, presenting a hard nodule the size of a small walnut in the substance of the cicatrix. He again excised it, November 17, 1848, and it was found to contain numerous cancer cells, similar to those represented Fig. 3.

OBSERVATION II.—The patient from whom this tumour was taken has had no return of the disease.

OBSERVATION III.—This patient is now in perfect health, and has had no return of the disease.

The size of the tumour was that of a human *head*, not of a human hand, as erroneously printed in the text.

OBSERVATION IV.—The woman, since her dismissal from the Infirmary, has not been heard of.

OBSERVATION V.—On the 8th November 1848, I learned from Mr Fergusson that this patient had never re-applied at King's College Hospital, and that it is supposed in consequence that she continues well.

OBSERVATION VI.—The breast has ulcerated, but there is every reason to suppose that the woman is still living.

OBSERVATION VII.—The growth in this case, as stated p. 14, consisted of a jelly-like or simple blastema, in which fibrous tissue was forming. No distinct cancer cells could any where be seen, and yet, singular to say, the disease returned in two other parts of the body, and occasioned death. The following is the letter I received from Mr Page, announcing this event, together with a portion of one of the tumours:—  
 “CARLISLE, 19th July 1848.—MY DEAR SIR,—The portion of tumour I last sent you was removed from the same patient whose case was described by you in the *Monthly Journal*, Obs. VII. Fig. 19. The woman was discharged in July 1847, and remained quite well for a month, when she first complained of pain in the right sciatic region, which was looked upon as sciatica, and treated accordingly. In January a small tumour was discovered beneath the lower margin of the gluteus maximus, in the median line of the thigh. This tumour gradually increased in size until her death, which took place on the 18th of June, when it had attained the magnitude of a large foetal head, and from its pressure on the sciatic nerve had given rise to extreme suffering. Not long before her death, another and still larger tumour was discovered pretty nearly in the same situation in the opposite thigh, which had given rise to no pain or other inconvenience, and she appeared to be quite unaware of its presence. We could not succeed in getting a post-mortem examination, and the small portion I sent you was obtained quite surreptitiously.

“I have never seen a case where the patient's sufferings were so great and long continued; many pints of Fleming's tincture of aconite were applied to the limb, and her daily dose of laudanum was 1½ ounce. On one occasion I had her kept for eight hours in a state of unconsciousness by means of chloroform, during which time she consumed three ounces; the benefit resulting from repose at this time was most striking.—Yours very truly,  
 W. B. PAGE.”

*Description of the Portion of Tumour received.*—The slice of tumour, received for examination, was about an inch broad, of greyish colour and pulpy gelatinous consistence. It could readily be broken down under the finger, but yielded no milky juice on pressure.

*Microscopic Examination.*—On squeezing a small portion of the growth between glasses, it presented, under the microscope, a structureless blastema consisting of finely molecular matter, in which were imbedded several compound granular masses at different depths, as in Fig. 19. No trace of fibrous tissue, however, or any kind of corpuscles, could be discovered. Ether at once removed the granules, and acetic acid rendered the blastema somewhat more transparent.



*Remarks.*—This case in itself, not to speak of numerous others which have been recorded in Part I., goes far to prove that the return of a morbid growth does not depend altogether upon the extent to which organization of its substance has been carried. In other words, some tumours may occasionally return, consisting of a simple blastema, with the earliest traces of commencing structure; others, when organization has proceeded so far as to constitute a fibro-nucleated texture—a third class, where perfect cells are formed, and a fourth where the whole consists of fibres. It is extremely probable, however, that growths containing cancer cells are most malignant, and most frequently return; but to establish even this point with exactitude, we require a greater number of accurate observations.

The compound granular masses found in the molecular blastema, I believe, to be granules of evolution, and the first commencement of organization. From these, nuclei are formed, which are ultimately converted into fibres or cells. This theory is supported by Figs. 18, 19, and 20, in which it will be observed that aggregations of these fatty granules existed in the softest part of the growth, or the one where least structure was observable; that, as nuclei and fibres appeared, these became less numerous, and wherever firm fibrous tissue existed, they had wholly disappeared. The same process occurs as takes place in the egg. The vitelline molecules and granules unite to form the embryo, and diminish in proportion as it increases.

OBSERVATION VIII.—Dr Duncan learnt from a letter received from Coldstream, where the patient resides, dated November 23, 1848, that she continues well, without any return of the disease.

OBSERVATIONS X. and XI.—Neither of these individuals have had any return of the disease. The latter was discharged cured some days after the date of the last Report.

OBSERVATIONS XXXIV. XXXV. and XXXVI.—In none of these cases has the disease returned, and the patients are known to be in perfect health.

OBSERVATION XXXVIII.—Nothing has been heard of this man since his dismissal from the Infirmary.

OBSERVATIONS XXXIX. and XL.—In neither of these cases has the disease returned.

OBSERVATIONS XLI. and XLII.—Neither of these patients have been heard of since the operation.

OBSERVATION XLIII.—I learn from Dr Davies (November 9, 1848), that “the patient continues in good health, without any return of the malady.”

OBSERVATION XLIV.—This patient has continued in good health up to the present time.

OBSERVATION XLVIII.—Having heard from Mr Syme that the disease returned and proved fatal in this case, I wrote to Dr Lucas of Dalkeith for the facts as they occurred, after her leaving the Infirmary. The following is the letter he kindly sent me in reply:—"DALKEITH, 20th November 1848.—MY DEAR SIR,—The girl continued to enjoy pretty good health after the operation till towards the end of the year, when pain, and afterwards enlargement, began to take place in the seat of the amputation. I saw her first on the 7th of December. The shoulder, which for some time after the operation was flat, and on a level with the ribs of the same side, now projected very considerably, in consequence of a morbid growth about the size of a child's head, occupying the situation of the former wound. It was evidently a tumour of malignant nature, and opiates and other palliatives were alone recommended. Large veins spread in intricate net-works over the whole surface of the tumour, which gradually increased in size. Effusions of serum, tinged with the colouring matter of the blood, began by and by to raise the cuticle in large blisters, which broke, healed, and were replaced by others. No hemorrhage ever occurred. Emaciation went on slowly at first, till hectic fever came on, when it proceeded with great rapidity. Diarrhoea soon succeeded, and death put a period to the poor girl's sufferings about the middle of March last, the tumour being then more than twice the size it was when I saw it first.—I ever am very faithfully yours,  
"JOHN LUCAS."

*Remarks.*—According to Müller, an enchondroma is not liable to return, yet that the tumour in this case was cartilaginous, cannot, on examining Figs. 126, 127, and 128, admit of doubt. Whether, however, the disease that re-appeared was the same as the original one, it is impossible to say, from the parts not having been examined.

OBSERVATION LII.—This patient has continued in good health up to the present time.

OBSERVATION LIII.—I learn from Mr Page (November 6, 1848) that this patient has had no return of the disease, and continues to perform the duties she has been accustomed to for many years—those of a domestic servant.

OBSERVATION LIV.—This patient has not been heard of since the operation, and is therefore supposed to be in good health.

OBSERVATION LV.—I learn concerning this case (November 13, 1848) that the wound has healed, with the exception of a spot the size of a pea. The cicatrix has caused great contraction of the integuments. He has had no bad symptom.

OBSERVATION LVI.—This gentleman has enjoyed the most excellent general health since the operation. The florid granulations noticed in the report, having been touched with sulphate of copper, soon disappeared, and the wound healed. The tongue at present nearly fills the mouth; articulation, though not so perfect as before the disease commenced, is much better than it was immediately prior

to the operation, and is daily improving. The glands low down in the neck are no longer tender, and have diminished in size. The submaxillary glands however increased, and, according to the decided determination of the patient, were excised, November 29, 1848, by Dr Duncan, assisted by Messrs Goodsir and Spence. A curved incision, extending from the ear to near the symphysis of the chin, was made immediately below the jaw, on the right side, and the enlarged glands below carefully dissected out. The operation was performed under the influence of chloroform, and caused the patient no pain. He is doing well (Dec. 5.)

*Description of the Glands removed.*—Three of the glands were kindly given to me for examination by Mr Goodsir. One of them, about an inch and a half long, and half an inch in depth, was healthy in its texture throughout. In another of nearly the same size, there existed at one extremity a yellowish mass the size of a coffee-bean, closely resembling tubercle. On being cut into, it was found to consist of a cheesy substance, friable under pressure, and enclosed in a cyst of white indurated matter, about the one-eighth of an inch in thickness. Another gland, about the size of an almond nut, on being incised, was found to be filled with the same soft, yellowish, cheesy matter. The healthy structure of the gland had entirely disappeared, and it was converted into an encysted structure, with bands crossing from side to side of the external cyst, dividing it into loculi. The wall of the cyst was in some places one-eighth of an inch thick, composed of the same white indurated matter as that noticed in the last gland described, which closely resembled the substance represented Fig. 148 *b*, and yielded no milky juice on pressure.

*Microscopic Examination.*—On placing a little of the yellow cheesy matter, mixed with water, between glasses, it was seen, under a power of 250 linear diameters, to be composed of a multitude of epithelial cells, similar to those figured Figs. 145, 153, 154. Many of them were firmly matted together, and presented a simicircular concave form at their edges, which evidently resulted from the breaking up of the concentric laminae, as represented Fig. 151. They were mingled with numerous molecules and granules, and crystals of cholesterine. On making a thin section of the white indurated substance, which enclosed the cheesy soft substance, it presented the same structure as that shown Fig. 151, but without the muscular fibres. Numerous free nuclei and fusiform cells, as in upper part of Fig. 150, were mingled with the loose epithelium, and concentrically laminated masses.

*Remarks.*—The result of this examination can leave no doubt that the lymphatic glands are subject to the same epithelial form of morbid growth as affects the tongue, face, or other similar structures. I think it due, however, to Mr Paget to state, that he had previously ascertained this fact; at least I understood him to tell me so, in a conversation I had with him on this subject at Bartholomew's Hospital last autumn.

*Fibro-Nucleated Growths.*—I do not know whether the structure I have called fibro-nucleated, is the same that Mr Paget speaks of as being composed almost entirely of corpuscles like nuclei or cyto-blasts (Brit. and For. Med. Review, Vol. XXII. p. 263). I have

never seen a growth to which such a description could apply, inasmuch as, although the nuclei were abundant, fibres undoubtedly made up the principal part of the tissue. Neither are fibro-nucleated growths remarkable for the rapidity of their progress, which is assigned by Mr Paget as one of the characters of those which he has found to be principally made up of nuclei. It is much to be regretted, however, that, in the present state of histology, the publication of any description of a new structure or form of growth should not be accompanied by a figure drawn from nature.

*Professor Sédillot's Case.*—In alluding to M. Sédillot's case, p. 234, in which a cancerous tumour had been excised from the knee *ten times*, and the leg afterwards amputated, I observed, that, if the woman ultimately recovered, it must be considered as one of the most remarkable facts on record. Impressed with the importance of knowing the termination of the case, I wrote to M. Sédillot before drawing up this appendix, and the following is his reply, dated *Strasburg, 24th October 1848*:—

“I hasten, according to the wish expressed in your letter of the 19th current, to inform you that the patient in question died a year after the cure of her amputation, of cancer of the lungs.

“I have been more fortunate with a young girl operated on between two and three years ago, with an enormous cancer of the superior part of the thigh. Three operations had previously been performed on it by Dr Ergott of Belfort. I was obliged to dissect the crural artery and vein, which were surrounded by cancerous matter, and the operation, continued under the influence of sulphuric ether, lasted upwards of an hour. The wound was enormous, and was partly covered by a large cutaneous flap borrowed from the internal crural region. The patient recovered, and is now in perfect health. This curious case is recorded in the *Gazette Médicale de Strasbourg*.”

EDINBURGH, *December 5, 1848.*

THE END.

#### ERRATA.

- Page 6, line 4 from bottom, *for hand, read head.*  
 „ 127, „ 12 „ *for Fig. 125, read Fig. 145.*  
 „ 133, „ 12 „ *for lamina, read laminæ.*  
 „ 149, „ 15 from top, *for plastic, read pavement.*  
 „ 227, last line, *for thus, read then.*





BOUND BY  
JOHN GRAY  
EDINBURGH

